

RETINAL VEIN OCCLUSION GUIDELINES

Studnička Jan^{1,2}, Němčanský Jan^{3,4}, Vysloužilová Daniela⁵, Ernest Jan^{6,7,8}, Veith Miroslav⁹, Němec Pavel^{8,10}

¹Department of Ophthalmology, University Hospital Hradec Králové and Faculty of Medicine in Hradec Králové of Charles University, Czech Republic

²VISUS, spol. s r.o., Czech Republic

³Department of Ophthalmology, University Hospital Ostrava, Czech Republic

⁴Department of Craniofacial Surgery, Faculty of Medicine, University of Ostrava, Czech Republic

⁵Department of Ophthalmology, Faculty of Medicine, Masaryk University, Brno, Czech Republic

⁶Vitreoretinální centrum Neoris, s.r.o., Czech Republic

⁷Axon Clinical, s.r.o., Czech Republic

⁸Department of Ophthalmology, 1st Faculty of Medicine of Charles University and Military University Hospital Praha, Czech Republic

⁹Department of Ophthalmology, 3rd Faculty of Medicine of Charles University and University Hospital Královské Vinohrady, Praha, Czech Republic

¹⁰Lexum a.s., Czech Republic

The authors of the study declare that no conflict of interests exists in the compilation and theme of this professional communication, and that it is not supported by any pharmaceuticals company.

Submitted to the editorial board: June 2, 2024

Accepted for publication: August 2, 2024

Available on-line: October 14, 2024



Primary author

Associate Professor Jan Studnička, MD, PhD

Corresponding author

Jan Němčanský, MD, PhD, MBA

Oční klinika FN Ostrava

17. listopadu 1790

708 52 Ostrava

E-mail: jan.nemcansky@fno.cz

SUMMARY

Retinal vein occlusion and its complications are among the most common causes of severe loss of sight in developed countries. In recent years, developments in imaging methods have been introduced, leading to an improvement in diagnostic possibilities. At the same time new treatment options have become available (new intravitreal drugs and treatment protocols, laser and surgical methods). The presented guidelines summarize the current knowledge about retinal vein occlusion in order to standardize and update procedures for the diagnosis, classification and treatment of the disease.

Key words: retinal vein occlusion, diagnostics, treatment, guidelines

Čes. a slov. Oftal., 80, 2024, No. 6, p. 298–305

1. INTRODUCTION AND EPIDEMIOLOGY

Retinal vein occlusion (RVO) is the second most common cause (after diabetic retinopathy) of deterioration of vision in developed countries in connection with a vascular pathology of the retina. It typically occurs in persons aged over 40 years (more frequently in patients aged over 60 years), with equal incidence in both sexes [1,2].

The prevalence is stated at 5.2 cases of RVO per 1000 persons, of which in 4.42 cases this concerns branch retinal vein occlusion (BRVO) and in 0.8 cases central retinal vein occlusion (CRVO) [3]. In the literature the overall five-year incidence or RVO is stated at 0.8%, the fifteen-year incidence at 1.8%,

and in the case of CRVO 0.2% and 0.5% respectively [4,5]. Prevalence and incidence both increase with age.

RVO is divided according to the location of vascular affliction into CRVO, in which the entire venous retinal system is afflicted and the presumed location of increased resistance to venous flow is located in or beyond the region of the lamina cribrosa. In the case of BRVO some of the branches of the retinal vein are occluded, and the changes are localized in the basin of this branch. BRVO may be limited to a small peripheral arteriovenous nicking, or (if the occlusion is located on the edge of the optic nerve) the pathology may affect the entire quadrant. A variant of CRVO is hemi-occlusion, with closure of both superior or both inferior branches of the retinal vein [6].

2. PATHOPHYSIOLOGY OF RVO

RVO is a multifactorial disease [7,24]. The cause of this nosological unit is thrombosis inside the lumen of the retinal veins, but it is not clear as to whether this concerns a primary matter or a secondary manifestation. There are certain differences in the pathogenesis of occlusion of the branch and main trunk of the retinal vein, as a result of which they are separate clinical units [2,6,8].

2.1. Pathophysiology of central retinal vein occlusion

A number of hypotheses exist with regard to the pathogenesis of CRVO. The occurrence of CRVO is most often explained by means of a compression of the trunk of the central retinal vein (CRV) by the activity of the central retinal artery (CRA), because both vessels are located in a shared fibrous capsule. A role may also be played by a degenerative or inflammatory disease of the wall of the CRV and hemodynamic factors, e.g. hypotension and blood dyscrasia [2,8–10].

The final result of these mechanisms is a stagnation of the flow of the venous blood, with subsequent formation of thrombosis in the CRV. The processes that contribute to the formation of a thrombosis are a reduction of blood flow, an increase of blood viscosity and damage to the endothelial barrier of the retinal vein (**"Virchow's triad"**). A fundamental location for the formation of thrombosis is the lamina cribrosa and the subsequent venous section. It is assumed that in the case of non-ischemic type of CRVO the thrombosis is located beyond the lamina cribrosa, and the increased accessibility of vascular collaterals here leads to less complete occlusion [9]. According to the results of the clinical trial Central Retinal Vein Occlusion Study, within the course of three years 34% of eyes convert non-ischemic CRVO into ischemic form, in which 15% of eyes do so within the first four months. This process is irreversible [11]. Malfunction of venous drainage leads to an increase of pressure in the venous channel, with subsequent reduction of blood flow, thereby leading to retinal ischemia. Hypoxia is subsequently a trigger for increased release of vascular endothelial growth factors (VEGF) and cytokines. This concerns interleukin (IL) 6, IL 8, interferon-inducible protein-10 (IP-10), monocyte chemotactic protein-1 (MCP-1), and platelet-derived growth factor (PDGF), which influence vascular permeability and angiogenesis in CRVO and BRVO [12–14]. The concentration of these inflammatory factors and cytokines in the vitreous and the anterior chamber is higher in the case of CRVO than in BRVO, and in proliferative diabetic retinopathy their concentration is lower still [15–18].

2.2. Pathophysiology of branch retinal vein occlusion

The cause of the condition is compression of the vein by the artery in places of arteriovenous nicking on the retina (both vessels have a shared adventitia), which generates a certain degree of stagnation and turbulence of blood flow, which may lead to damage to the vascular endothelium and subsequently to the formation of thrombosis. The vein lumen may be compressed by up to 33% of its diameter in the place

of crossing. In the case of preexisting atherosclerotic changes of the vascular wall, this process is exacerbated. Obstruction in the venous system leads to elevation of venous pressure and to subsequent overburdening of the drainage capacity of the venous channel. The result is edema, hemorrhage and ischemia of the corresponding retinal areas [2,6,8,19,20].

3. RISK FACTORS OF RVO

The most significant risk factor is age of over 70 years, with attendant sclerotic changes in blood vessels [21]. The main risk factors are arterial hypertension, hypercholesterolemia and diabetes mellitus. Further risk factors are hyperhomocysteinemia, higher body mass index (BMI), smoking and previous heart attack or stroke. Mutation of factor V Leiden increases the risk of RVO by approximately 50–60%. Risk factors are also other hypercoagulable states (antiphospholipid syndrome, protein C and S deficiency and antithrombin deficiency). Risk factors under discussion are hormonal substitution therapy containing estrogen, oral contraceptives and diuretics. More serious risk factors include hyperviscosity syndrome (multiple myeloma, polycythemia vera, lymphoma and leukemia) and inflammatory diseases associated with retinal vasculitis (sarcoidosis, toxoplasmosis, tuberculosis, Behçet's disease, systemic lupus erythematosus, polyarteritis nodosa, Wegener's granulomatosis and Goodpasture syndrome). Ocular risk factors include glaucoma [2,6].

4. SUBJECTIVE SYMPTOMS OF RVO

Patients may initially be asymptomatic, later they experience a deterioration of visual acuity (VA), and in later complications eye pain may also occur [22]. In the case of BRVO the degree of deterioration of vision and the extent of the blind spot in the visual field are dependent upon the location of vascular occlusion and on the presence and extent of macular edema. Prognostically unfavorable BRVO has initial visual acuity (VA) of 6/24 and worse [21,23]. In the case of CRVO various degrees of loss of sight and central scotoma occur. Initial VA is worse in the case of ischemic CRVO. The prognosis of CRVO is far worse in comparison with BRVO. Ischemic CRVO is almost always linked with poor initial VA, and its correction is highly improbable. The worse the initial VA in the case of non-ischemic occlusion, the worse the prognosis for the acuity of resulting vision. In the case of prethrombosis there may not be any subjective symptoms, or only transitory episodes of deterioration of vision may occur.

5. OBJECTIVE FINDING IN RVO

The clinical picture of CRVO incorporates edema of the papilla of the optic nerve (ON) and edema of the retina, dilation and tortuosity of all retinal veins, as well as deep and superficial hemorrhages of the retina in all quadrants. In the case of ischemic occlusion, cotton wool spots also appear as an expression of retinal ischemia.

The finding in BRVO manifests similar characteristics as in CRVO, which are however limited only to the region of the

retina located beyond the place of occlusion of the afflicted vein. In the case of simultaneous affliction of the superior or inferior half of the retina this is referred to as hemi-occlusion of the central retinal vein. A symptom of longer duration of the disease in BRVO is the presence of collateral circulation around the afflicted area, and in CRVO also vascular collaterals on the optic nerve papilla and the formation of capillary aneurysms, resulting in exudation [1]. Optociliary shunts also form on the ON papilla as a sign of newly formed collateral channels with choroidal circulation.

Macular edema (ME) often persists even after absorption of hemorrhages, and a secondary epiretinal membrane may form.

The clinical picture of prethrombosis (incipient RVO) is characterized by the presence of dilated retinal veins and a small number of scattered hemorrhages, but without ME.

6. COMPLICATIONS OF RVO

6.1. Complications of CRVO

In the case of non-ischemic CRVO, the main sight-threatening complication is ME and the risk of conversion to ischemic form.

In the **ischemic form of CRVO**, retinal hypoxia stimulates the expression of pro-angiogenic growth factors, leading to the development of neovascularization (NV) – the main complication of ischemic CRVO. NVs occur especially in the anterior segment of the eye – beginning on the iris by the edge of the pupil, and subsequently progressing to the iridocorneal angle (although in 10% of patients NVs appear first of all in the iridocorneal angle). They thereby impede the outflow of intraocular fluid through the trabecular meshwork, with a subsequent elevation of intraocular pressure and the onset of neovascular glaucoma (NVG).

The strongest predictors of the occurrence of NV in the anterior segment of the eye are VA and the scope of the non-perfusion area determined by fluorescein angiography (FAG) [11]. Ischemic CRVO is the second most common cause of NVG. In approximately 60% of patients with ischemic CRVO, NVs of the anterior segment appear within the range of a few weeks to two years. NVG develops in 40–45% of patients with CRVO, in 80% of these patients this occurs within 6–8 months of the onset of CRVO [24]. NVG is frequently accompanied by intravitreal hemorrhage or hemorrhage into the anterior chamber, and is a very adverse prognostic factor [2,7,24].

The development of retinal NV may lead to the onset of fibrovascular traction, tractional retinal detachment and hemorrhage into the vitreous [25,26].

6.2. Complications of BRVO

Complications of BRVO are above all the development of ME and macular ischemia. Chronic ME is linked with a poor prognosis for the development of VA. The longer the period of duration of edema, the greater the probability of structural damage to the fovea [25]. The incidence of NV is relatively low in the case of BRVO, with the exception of cases with extensive ischemia.

7. DIAGNOSIS OF RVO

With regard to the general risk factors, monitoring of blood pressure values (Holter blood pressure monitoring) is recommended for patients with RVO, as well as measurement of the levels of blood sugar and lipids in blood. The basic laboratory tests also include evaluation of the differential blood count, speed of sedimentation of erythrocytes, value of C-reactive protein and homocysteine. A comprehensive assessment by an internal medicine specialist or general practitioner is appropriate in order to exclude the risk of other systemic thrombosis. Patients without risk factors and younger patients with RVO should have their blood coagulation parameters examined in order to exclude thrombophilic states including antiphospholipid syndrome.

As part of the basic eye examination, it is necessary to perform intraocular tonometry and examination of the anterior segment, including gonioscopy in order to exclude the presence of NVs. Timely identification of NVs is of fundamental importance in order to reduce the risk of onset of complications [22,27]. It is essential to perform careful biomicroscopy of the fundus in artificial mydriasis, also with examination of the retinal periphery.

For monitoring of the dynamic of the disease it is an advantage to perform digital photography of the ocular fundus. For documentation of the maximum of changes and the state of the retinal periphery we currently use wide-angle imaging systems, which display up to 82% of the surface of the retina and enable a view up to 270 degrees [28].

FAG is decisive for determining the scope of retinal ischemia and for demonstrating the incidence of NV. The non-ischemic and ischemic forms of RVO can be differentiated only on the basis of an angiographic finding. According to FAG, ischemic CRVO is defined by the presence of zones of capillary non-perfusion within a scope of 10 or more surfaces of the optic nerve papilla in the region of the posterior pole of the eye [11]. According to FAG, ischemic BRVO is defined by the scope of capillary non-perfusion greater than 5 surfaces of the optic nerve papilla [29].

Optical coherence tomography (OCT) is used in the diagnosis and monitoring of the development of ME and affiliated disorders of the vitreoretinal interface. A sign of acute ME is the presence of subretinal and intraretinal fluid. Detailed parameters of the OCT finding, above all Disorganization of Retinal Inner Layers (DRIL), changes of integrity of the line of the inner and outer segments of the photoreceptors and external limiting membrane point to a potential irreversible loss of cells and an attendant irreversible deterioration of vision. In different stages of RVO it is possible to observe hyperreflective intraretinal foci and vitreomacular abnormalities (e.g. traction, epiretinal membrane) on OCT.

OCT angiography (OCTA) enables detection of changes in the superficial and deep plexus of the retinal vessels and displays NV of the retina and ON papilla [1].

In the case of non-transparent optic media, it is necessary to perform ultrasound examination in order to exclude intravitreal hemorrhage and retinal detachment.

It is of crucial importance to determine the exact type of

vascular occlusion, because in the case of the ischemic type it is necessary from the outset to conduct frequent monitoring every month until stabilization of the finding.

8. TREATMENT OF RVO

8.1. Treatment of risk factors

The treatment of cardiovascular diseases, which are the main risk factor in RVO, is necessary not only in order to prevent the onset and development of manifestations of retinal vein occlusion, but also as prevention of the occurrence of other vascular events (e.g. heart attack and stroke) and to reduce the risk of vein occlusion in the other eye. In women who have suffered RVO, termination of hormone replacement therapy containing estrogen should be considered [1].

Treatment of affiliated pathologies and evaluation of systemic risks should be conducted by a doctor with the relevant specialization (internal medicine specialist, general practitioner, hematologist, neurologist).

The prognosis for patients with non-ischemic CRVO and VA of 6/9 or better is favorable, and it is therefore possible to conduct only careful monitoring. However, due to the existing risk of development of ischemic form, following an agreement with the relevant specialist (internal medicine specialist or hematologist) transitional general anticoagulation treatment may be administered which will avert this risk with 96% probability [30]. The primary objective is to determine the risk factors and identify the risk of occurrence of ME or conversion to ischemic form of CRVO. In the case of BRVO without ME, with a peripheral perfusion and VA of ZO 6/12 or better, the prognosis is favorable, and it is also possible only to monitor the patient. Within the first three months it is recommended to monitor patients once per month, and subsequently once every two months during the first year [6].

8.2. Antithrombotic treatment, fibrinolysis

At present this form of treatment is not unequivocally supported by randomized clinical trials, and for this reason there is no unequivocal expert consensus regarding the administration of this treatment by an ophthalmologist [7,31–33].

8.3. Laser treatment

Laser treatment of CRVO is necessary for patients with extensive retinal non-perfusion, presence of NVs of the retina or anterior segment. The onset and amount of NVs are directly proportional to the extent of ischemia. In these cases, panretinal photocoagulation (PRP) is performed, which must be commenced as early as possible. The objective of treatment is to increase the vascular supply in the undamaged parts of the retina, and to reduce the production of VEGF [34,35]. However, sometimes it is necessary to wait until the resorption of hemorrhages before commencing PRP, in which case it is appropriate to consider another therapeutic modality. PRP is of fundamental importance in NVG – separately or in combination with anti-VEGF preparations [24].

In the case of non-ischemic CRVO it is sometimes possible to utilize laser induced chorioretinal anastomosis (L-CRA), in which we use the laser to create an anastomosis

(bypass) between the location of occlusion of the CRV and the choroid. This technique leads to an improvement of VA and to a reduction of the risk of occurrence of ischemic CRVO with further complications [36–38]. As regards the effectiveness of current pharmacotherapy and the potential complications of L-CRA, it appears to be most advantageous to use this technique in combination with intraocularly administered anti-VEGF preparations. In such a case it is possible to expect an improvement of VA, anatomical ratios and simultaneously a pronounced reduction of the overall number of administered injections [39–41].

Laser treatment of ME (grid laser of the macula) in CRVO does not bring about an improvement of VA, and as a result is not recommended in this indication [42].

In the case of macular edema, laser photocoagulation is usable only in the case of BRVO [43] – grid laser of the macular or focal laser. It is not indicated in the case of diffuse ME or for hemodynamically severe, hemorrhagic occlusion. Its effectiveness is significantly lower in comparison with treatment using anti-VEGF preparations [44,45].

It is appropriate to perform sector laser photocoagulation on patients with BRVO in the case of appearance of ischemic zones, retinal NV or NV of the optic nerve papilla. PRP of a hemorrhagic retina is generally considered a contraindication due to the risk of incidence of hypercoagulation lesions with induction of the onset of epiretinal membrane and tractional changes of the macula [5].

8.4. Intravitreal application of anti-VEGF preparations

In the case of RVO, retinal ischemia leads to an elevated release of VEGF into the vitreous. Destabilization of VEGF levels increases the permeability of vessels, with subsequent infiltration of fluid and the onset of macular edema [46–48]. Anti-VEGF preparations prevent the effect of vascular endothelial growth factor on their receptors on the retinal endothelial cells.

At present the anti-VEGF preparations approved within the framework of treating ME are ranibizumab and aflibercept. Both block VEGF, and aflibercept also blocks placental growth factor. The binding affinity of aflibercept to VEGF-A is greater than the binding affinity of ranibizumab [49,50]. Both pharmaceuticals achieve comparable results in the sense of improvement of VA and reduction of central retinal thickness, but aflibercept attains the therapeutic target with a lesser number of generally administered injections [51,52]. Faricimab has demonstrated a comparable efficacy and safety as aflibercept in registration clinical trials, and also a reduced number of doses in comparison with ranibizumab. On the basis of these results, approval proceedings are currently under way for the use of faricimab in the treatment of ME upon a background of RVO [53,54].

Anti-VEGF preparations are the drug of first choice for most patients with ME upon a background of RVO. Treatment should be commenced as early as possible, since the attained results are worse following a delay in the commencement of treatment. After treatment is commenced, it is recommended to continue with monthly applications until stability of

VA has been attained, or until the disappearance of signs of activity of the disease. It is subsequently possible to extend the intervals between applications, ideally in a treat and extend (T&E) regimen. Above all in ischemic forms of RVO it is necessary to conduct long-term monitoring due to the potential recurrence of ME or the onset of NV. The beneficial effect of anti-VEGF therapy is manifested in a regression of ME and a regression of neovascularization, but it does not eliminate the subsequent production of VEGF [1,24].

Anti-VEGF preparations have a significant potential effect both separately and in combination with laser treatment, above all in the case of advanced ischemic forms of RVO and complications (e.g. NVG) [24].

8.5 Intravitreal application of corticosteroids

The reasons for the use of intravitreal corticosteroids in the treatment of ME upon a background of RVO are linked with their capacity to reduce capillary permeability thanks to the strengthening of the connections of the endothelial cells of the capillaries and inhibition of the expression of VEGF. At the same time, they also have an anti-inflammatory effect thanks to the blockade of inflammatory mediators, inhibition of leukostasis and the limiting of the fibrin accumulation and the migration of phagocytes. In addition, corticosteroids prevent the release of prostaglandins, some of which are proven mediators of the onset of cystoid ME.

Intravitreal dexamethasone has already been in use for a longer time as a strong corticosteroid which reduces the level of inflammatory mediators. It is highly soluble, and following

intravitreal application has a short half-life. In the treatment of ME upon a background of RVO a biodegradable implant with slow release of dexamethasone (Ozurdex) is used, which gradually releases the pharmaceutical to the posterior pole of the eye for up to six months from intravitreal implantation.

Treatment of ME upon a background of RVO using corticosteroids is effective, and with regard to the results of clinical trials it is suitable primarily as the drug of first choice in the case that no effect of treatment is demonstrated after 3–6 injections of an anti-VEGF preparation [55,56]. In the case of patients with a medical history of a recent severe cardiovascular event and patients who are unable to attend monthly applications within the first 6 months of treatment, it is possible to use Ozurdex as the preparation of first choice. In the case of these patients, it is necessary to monitor intraocular pressure every 2 to 8 weeks after injection.

Repeated treatment with the pharmaceutical preparation Ozurdex is usually performed after 4 months, with 2–3 injections on average administered per year. With regard to the relatively high risk of incidence of cataract, patients with pseudophakia are more suitable for this treatment; patients with their own lens should be informed of this matter [1].

The schemas of the decision-making procedure for treatment of CRVO and BRVO are presented in Figure 1 and Figure 2.

8.6 Surgical options for treatment of complications of retinal vein occlusion

In the era of anti-VEGF therapy and depot corticosteroids

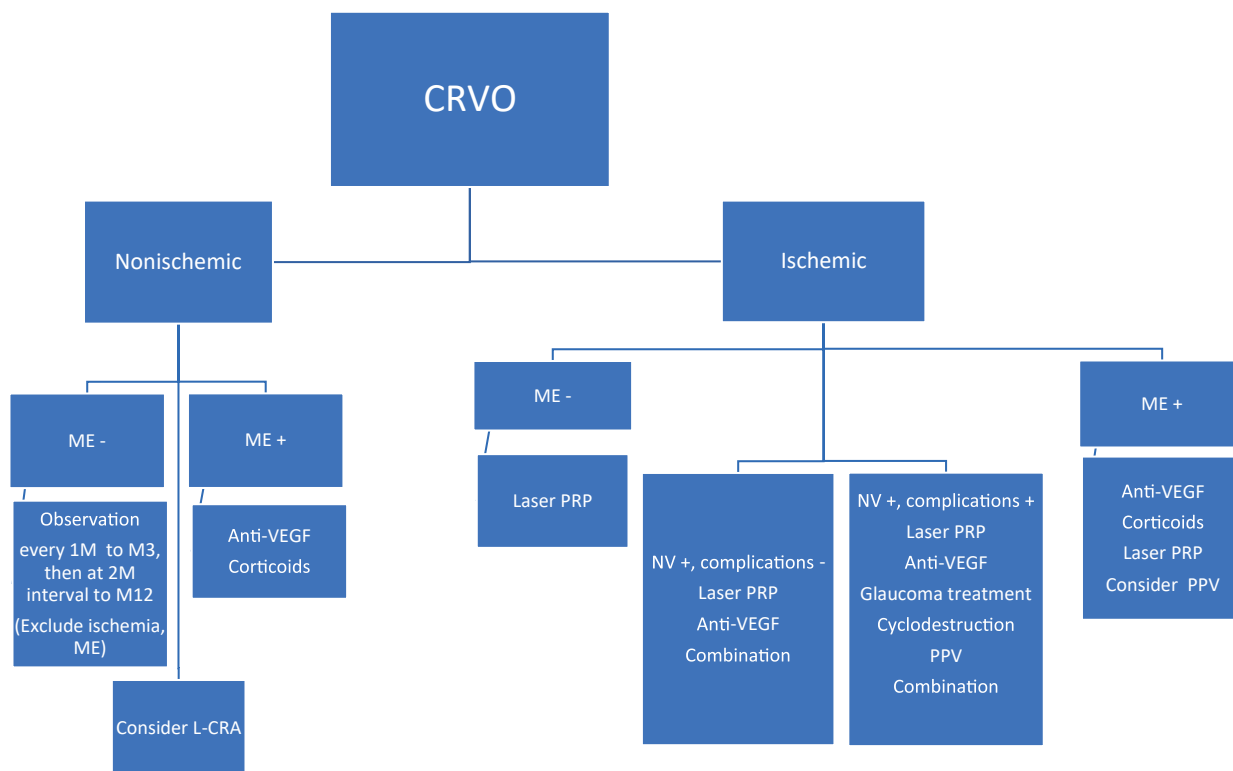


Figure 1. Management of CRVO treatment

CRVO – central retinal vein occlusion, ME – macular edema, M – month, L-CRA – laser induced chorioretinal anastomosis, anti-VEGF – inhibitors of vascular endothelial growth factor, NV – neovascularization, PRP – panretinal photocoagulation, PPV – pars plana vitrectomy

there was a significant reduction of the number of patients with RVO indicated for surgical treatment. Despite this, in the case of severe complications or insufficient effectiveness of conservative procedures, pars plana vitrectomy (PPV) remains justified in these cases. The objective of surgical treatment is similar as in the case of conservative therapeutic procedures: to reduce hypoxia, reduce the production of VEGF and other inflammatory mediators, to prevent the occurrence of or treat secondary complications (hemophthalmos, NV, gliovascular proliferation) and to create the conditions for a better effect of conservative therapy (corticosteroids, anti-VEGF, laser photocoagulation).

This especially concerns the following findings:

- A. Hemophthalmos – non-resorbing intravitreal hemorrhage which deteriorates VA or prevents monitoring and further intravitreal treatment with anti-VEGF or corticosteroids. After removal of the turbid vitreous, patients experience an immediate effect depending on the extent of previous damage and the degree of hypoxia [57]. Within the framework of PPV, it generally proves effective at the same time to eliminate any pathology of the vitreoretinal interface and perform targeted perioperative laser photocoagulation [58]. Concurrent intravitreal application of depot corticosteroids at the conclusion of the operation has been demonstrated to be effective in reducing ME [59–62]. It has been confirmed in trials that while the clearance of anti-VEGF from the vitreous in the eye after PPV is quicker, the effect of depot corticosteroids remains analogous as in an eye without PPV [59–63]. The timing of the operation should be indicated depending on the

time of onset of the complications of RVO and prior treatment, at present we often proceed to PPV after only 4 weeks unless hemophthalmos shows any tendency towards resorption.

- B. Macular edema with concurrently present pathology of the vitreoretinal interface responds less well to conservative therapy, and its results are therefore often limited. Surgical treatment consists in PPV with peeling of the epiretinal membranes and peeling of the membrana limitans interna. The timing of the operation depends on the effect of prior conservative therapy and the dynamics of the finding. The effect of PPV with peeling of the epiretinal pathology and its contribution to anatomical and functional improvement has been demonstrated by a series of authors [64–69]. In order to achieve the maximum therapeutic effect, it is suitable to combine a surgical procedure with conservative therapy perioperatively or subsequently following the performance of PPV [59–62].
- C. Neovascular glaucoma in connection with intraocular hemorrhage

The objective of PPV is to restore the transparency of optic media and to perform perioperative panretinal laser photocoagulation of the retina to the maximal periphery, if applicable in combination with external transscleral cryoretinopexy. Combination of PPV with the application of a glaucoma drainage implant is also possible. In some cases, it is essential to combine PPV also with lens surgery if the opacities of the lens prevent detailed visualization of the posterior segment and treatment of the retinal periphery by endolaser. The surgical procedure may bring stabilization of intraocular pressure and visual functions, though in the majority of

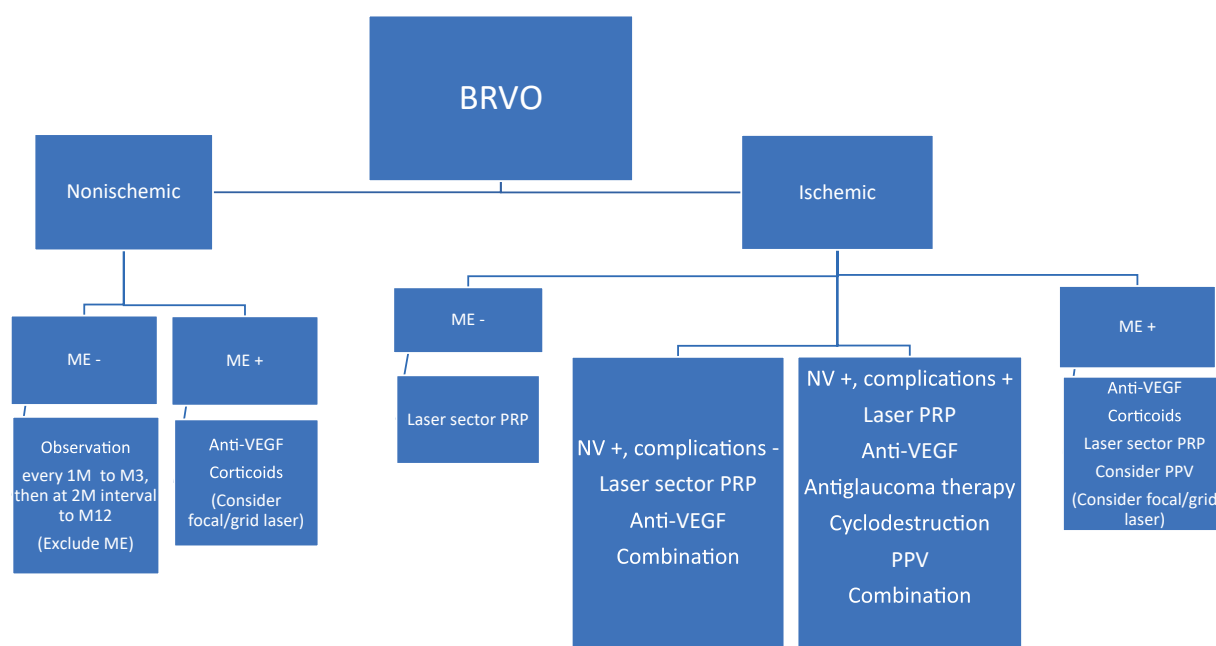


Figure 2. Management of BRVO treatment

BRVO – branch retinal vein occlusion, ME – macular edema, M – month, anti-VEGF – inhibitors of vascular endothelial growth factor, NV – neovascularization, PRP – panretinal photocoagulation, PPV – pars plana vitrectomy

cases of these severe conditions it is not possible to expect a more significant improvement of vision, and the objective of PPV is rather to prevent further complications and progression of the disease [57].

8.7 Treatment of neovascular glaucoma

Panretinal photocoagulation (PRP) is of fundamental importance in the treatment of NVG, leading to a reduction of ischemia and regression of NV.

Intravitreal treatment using anti-VEGF preparations may be applied in the presence of NV of the iris and NVG in monotherapy, and especially in combination with PRP (see above) [24]. If the chamber angle is definitively closed by synechiae, anti-VEGF treatment can reduce the extent of NV, but has no influence on the values of intraocular pressure.

To reduce intraocular pressure, we use topical application of beta blockers, carbonic anhydrase inhibitors, alpha-agonists and prostaglandin analogues. For suppression of in-

flammatory changes and alleviation of pain it is possible to use topical application of atropine or corticosteroids. In the case of extensive synechiae of the chamber angle, pharmacological treatment may be insufficient and we must proceed to surgical treatment. Trabeculectomy is less successful in NVG and is burdened by a higher risk of perioperative and postoperative complications than in primary glaucoma, and as a result it is more appropriate to use drainage implants [70].

In the case of NVG accompanied by complications (intraocular hemorrhage, opacity of optic media) we perform PPV (see 8.6).

In the terminal stages of NVG with little potential for improvement of VA or eye pain, it is possible also to use the cyclodestructive methods of cyclophotocoagulation or cyclocryocoagulation (in combination with PRP or transscleral cryoretinopexy, or separately) [24,71]. In the case of a blind and painful eyeball retrobulbar application of alcohol is possible, or we may perform enucleation [27].

REFERENCES

- Schmidt-Erfurth U, Garcia-Arumi J, Gerendas BS, et al. Guidelines for the Management of Retinal Vein Occlusion by the European Society of Retina Specialists (EURETINA). *Ophthalmologica*. 2019;242(3):123-162.
- Řehák J, Řehák M. Venózní okluze sítnice. 1 ed. Praha: Grada; 2011. 138 p.
- Rogers S, McIntosh RL, Cheung N, et al. The prevalence of retinal vein occlusion: pooled data from population studies from the United States, Europe, Asia, and Australia. *Ophthalmology*. 2010;117(2):313-319.e311.
- Klein R, Klein BE, Moss SE, Meuer SM. The epidemiology of retinal vein occlusion: the Beaver Dam Eye Study. *Trans Am Ophthalmol Soc*. 2000;98:133-141; discussion 141-133.
- Klein R, Moss SE, Meuer SM, Klein BE. The 15-year cumulative incidence of retinal vein occlusion: the Beaver Dam Eye Study. *Arch Ophthalmol*. 2008;126(4):513-518.
- Řehák J, Studnička J, Rozsival P, et al. Doporučené postupy pro diagnostiku a léčbu pacientů s venózní okluzí sítnice [Recommendations for diagnosis and therapy of patients with retinal vein occlusion]. *Cesk Slov Oftalmol*. 2012;68(6):244-256. Czech.
- Rehak J, Rehak M. Branch retinal vein occlusion: pathogenesis, visual prognosis, and treatment modalities. *Curr Eye Res*. 2008;33(2):111-131.
- Haymore JG, Mejico LJ. Retinal vascular occlusion syndromes. *Int Ophthalmol Clin*. 2009;49(3):63-79.
- Hayreh SS, Zimmerman MB, Podhajsky P. Incidence of various types of retinal vein occlusion and their recurrence and demographic characteristics. *Am J Ophthalmol*. 1994;117(4):429-441.
- Janssen MC, den Heijer M, Cruysberg JR, Wollersheim H, Bredie SJ. Retinal vein occlusion: a form of venous thrombosis or a complication of atherosclerosis? A meta-analysis of thrombophilic factors. *Thromb Haemost*. 2005;93(6):1021-1026.
- The Central Vein Occlusion Study Group. Natural history and clinical management of central retinal vein occlusion. *Arch Ophthalmol*. 1997;115(4):486-491.
- Funk M, Kriechbaum K, Prager F, et al. Intraocular concentrations of growth factors and cytokines in retinal vein occlusion and the effect of therapy with bevacizumab. *Invest Ophthalmol Vis Sci*. 2009;50(3):1025-1032.
- Noma H, Funatsu I, Mimura T, Harino S, Hori S. Vitreous levels of interleukin-6 and vascular endothelial growth factor in macular edema with central retinal vein occlusion. *Ophthalmology*. 2009;116(1):87-93.
- Boyd SR, Zachary I, Chakravarthy U, et al. Correlation of increased vascular endothelial growth factor with neovascularization and permeability in ischemic central vein occlusion. *Arch Ophthalmol*. 2002;120(12):1644-1650.
- Suzuki Y, Nakazawa M, Suzuki K, Yamazaki H, Miyagawa Y. Expression profiles of cytokines and chemokines in vitreous fluid in diabetic retinopathy and central retinal vein occlusion. *Jpn J Ophthalmol*. 2011;55(3):256-263.
- Lee WJ, Kang MH, Seong M, Cho HY. Comparison of aqueous concentrations of angiogenic and inflammatory cytokines in diabetic macular oedema and macular oedema due to branch retinal vein occlusion. *Br J Ophthalmol*. 2012;96(11):1426-1430.
- Ehlken C, Rennel ES, Michels D, et al. Levels of VEGF but not VEGF(165b) are increased in the vitreous of patients with retinal vein occlusion. *Am J Ophthalmol*. 2011;152(2):298-303.e291.
- Aiello LP, Avery RL, Arrigg PG, et al. Vascular endothelial growth factor in ocular fluid of patients with diabetic retinopathy and other retinal disorders. *N Engl J Med*. 1994;331(22):1480-1487.
- Frangieh GT, Green WR, Barraquer-Somers E, Finkelstein D. Histopathologic study of nine branch retinal vein occlusions. *Arch Ophthalmol*. 1982;100(7):1132-1140.
- Christoffersen NL, Larsen M. Pathophysiology and hemodynamics of branch retinal vein occlusion. *Ophthalmology*. 1999;106(11):2054-2062.
- Rehak J, Dusek L, Chrapek O, Fric E, Rehak M. Initial visual acuity is an important prognostic factor in patients with branch retinal vein occlusion. *Ophthalmic Res*. 2011;45(4):204-209.
- Rodrigues GB, Abe RY, Zangalli C, et al. Neovascular glaucoma: a review. *Int J Retina Vitreous*. 2016;2:26.
- Jaissle GB, Szurman P, Feltgen N, et al. Predictive factors for functional improvement after intravitreal bevacizumab therapy for macular edema due to branch retinal vein occlusion. *Graefes Arch Clin Exp Ophthalmol*. 2011;249(2):183-192.
- Dumbrăveanu L, Cușnir V, Bobescu D. A review of neovascular glaucoma. Etiopathogenesis and treatment. *Rom J Ophthalmol*. 2021;65(4):315-329.
- McIntosh RL, Rogers SL, Lim L, et al. Natural history of central retinal vein occlusion: an evidence-based systematic review. *Ophthalmology*. 2010;117(6):1113-1123.e1115.
- Chan CK, Ip MS, Vanveldhuisen PC, et al. SCORE Study report #11: incidences of neovascular events in eyes with retinal vein occlusion. *Ophthalmology*. 2011;118(7):1364-1372.
- Havens SJ, Gulati V. Neovascular Glaucoma. *Dev Ophthalmol*. 2016;55:196-204.
- Silva PS, Cavallerano JD, Sun JK, Soliman AZ, Aiello LM, Aiello LP. Peripheral lesions identified by mydriatic ultrawide field imaging: distribution and potential impact on diabetic retinopathy severity. *Ophthalmology*. 2013;120(12):2587-2595.
- Branch Vein Occlusion Study Group. Argon laser scatter photocoagulation for prevention of neovascularization and vitreous hemorrhage in branch vein occlusion. A randomized clinical trial. *Arch Ophthalmol*. 1986;104(1):34-41.
- Řehák J, Chrapek O. Venózní okluze sítnice. In: Rozsival P, editor. *Trendy soudobé oftalmologie*. 2: Grada; 2005. p. 73-95.

31. Paciullo F, Valeriani E, Porfidia A, et al. Antithrombotic treatment of retinal vein occlusion: a position statement from the Italian Society on Thrombosis and Haemostasis (SISST). *Blood Transfus.* 2022;20(4):341-347.
32. Lazo-Langner A, Hawel J, Ageno W, Kovacs MJ. Low molecular weight heparin for the treatment of retinal vein occlusion: a systematic review and meta-analysis of randomized trials. *Haematologica.* 2010;95(9):1587-1593.
33. Valeriani E, Paciullo F, Porfidia A, et al. Antithrombotic treatment for retinal vein occlusion: a systematic review and meta-analysis. *J Thromb Haemost.* 2023;21(2):284-293.
34. Central Vein Occlusion Study Group. Central vein occlusion study of photocoagulation therapy. Baseline findings. *Online J Curr Clin Trials.* 1993;Doc No 95:[6021 words; 6081 paragraphs].
35. Li C, Wang R, Liu G, et al. Efficacy of panretinal laser in ischemic central retinal vein occlusion: A systematic review. *Exp Ther Med.* 2019;17(1):901-910.
36. McAllister IL, Gillies ME, Smithies LA, et al. The Central Retinal Vein Bypass Study: a trial of laser-induced chorioretinal venous anastomosis for central retinal vein occlusion. *Ophthalmology.* 2010;117(5):954-965.
37. Lu N, Wang NL, Li ZH, Wang GL, Zhang F, Peng XY. Laser-induced chorioretinal venous anastomosis using combined lasers with different wavelengths. *Eye.* 2007;21(7):962-967.
38. Fekrat S, Goldberg MF, Finkelstein D. Laser-Induced Chorioretinal Venous Anastomosis for Nonischemic Central or Branch Retinal Vein Occlusion. *Arch Ophthalmol.* 1998;116(1):43-52.
39. McAllister IL, Smithies LA, Chen FK, Mackey DA, Sanfilippo PG. Benefits of a Laser Chorioretinal Anastomosis Plus Ranibizumab vs Ranibizumab Alone for Central Retinal Vein Occlusion: 4-Year Results. *Am J Ophthalmol.* 2023;252:101-110.
40. McAllister IL. Chorioretinal Anastomosis for Central Retinal Vein Occlusion: A Review of Its Development, Technique, Complications, and Role in Management. *Asia Pac J Ophthalmol (Phila).* 2020;9(3):239-249.
41. McAllister IL, Smithies LA, Chen FK, Mackey DA, Sanfilippo PG. Functional benefits of a chorioretinal anastomosis at 2 years in eyes with a central retinal vein occlusion treated with ranibizumab compared with ranibizumab monotherapy. *BMJ Open Ophthalmol.* 2021;6(1):e000728.
42. The Central Vein Occlusion Study Group. Evaluation of grid pattern photocoagulation for macular edema in central vein occlusion. The Central Vein Occlusion Study Group M report. *Ophthalmology.* 1995;102(10):1425-1433.
43. The Branch Vein Occlusion Study Group. Argon laser photocoagulation for macular edema in branch vein occlusion. *Am J Ophthalmol.* 1984;98(3):271-282.
44. Clark WL, Boyer DS, Heier JS, et al. Intravitreal Aflibercept for Macular Edema Following Branch Retinal Vein Occlusion: 52-Week Results of the VIBRANT Study. *Ophthalmology.* 2016;123(2):330-336.
45. Campochiaro PA, Hafiz G, Mir TA, et al. Scatter Photocoagulation Does Not Reduce Macular Edema or Treatment Burden in Patients with Retinal Vein Occlusion: The RELATE Trial. *Ophthalmology.* 2015;122(7):1426-1437.
46. Campochiaro PA, Hafiz G, Shah SM, et al. Ranibizumab for macular edema due to retinal vein occlusions: implication of VEGF as a critical stimulator. *Mol Ther.* 2008;16(4):791-799.
47. Noma H, Funatsu H, Yamasaki M, et al. Pathogenesis of macular edema with branch retinal vein occlusion and intraocular levels of vascular endothelial growth factor and interleukin-6. *Am J Ophthalmol.* 2005;140(2):256-261.
48. Pe'er J, Folberg R, Itin A, Gnessin H, Hemo I, Keshet E. Vascular endothelial growth factor upregulation in human central retinal vein occlusion. *Ophthalmology.* 1998;105(3):412-416.
49. Pielon A, Clark WL, Boyer DS, et al. Integrated results from the COPERNICUS and GALILEO studies. *Clin Ophthalmol.* 2017;11:1533-1540.
50. Papadopoulos N, Martin J, Ruan Q, et al. Binding and neutralization of vascular endothelial growth factor (VEGF) and related ligands by VEGF Trap, ranibizumab and bevacizumab. *Angiogenesis.* 2012;15(2):171-185.
51. Casselholm de Salles M, Amrén U, Kvanta A, Epstein DL. Injection frequency of aflibercept versus ranibizumab in a treat-and-extend regimen for central retinal vein occlusion: A Randomized Clinical Trial. *Retina.* 2019;39(7):1370-1376.
52. Hykin P, Prevost AT, Vasconcelos JC, et al. Clinical Effectiveness of Intravitreal Therapy With Ranibizumab vs Aflibercept vs Bevacizumab for Macular Edema Secondary to Central Retinal Vein Occlusion: A Randomized Clinical Trial. *JAMA Ophthalmol.* 2019;137(11):1256-1264.
53. Hattenbach LO, Abreu F, Arrisi P, et al. BALATON and COMINO: Phase III Randomized Clinical Trials of Faricimab for Retinal Vein Occlusion: Study Design and Rationale. *Ophthalmology Science.* 2023;3(3):100302.
54. Tadayoni R, Paris LP, Danzig CJ, et al. Efficacy and Safety of Faricimab for Macular Edema due to Retinal Vein Occlusion: 24-Week Results from the BALATON and COMINO Trials. *Ophthalmology.* 2024.
55. Hattenbach LO, Feltgen N, Bertelmann T, et al. Head-to-head comparison of ranibizumab PRN versus single-dose dexamethasone for branch retinal vein occlusion (COMRADE-B). *Acta Ophthalmol.* 2018;96(1):e10-e18.
56. Hoerauf H, Feltgen N, Weiss C, et al. Clinical Efficacy and Safety of Ranibizumab Versus Dexamethasone for Central Retinal Vein Occlusion (COMRADE C): A European Label Study. *Am J Ophthalmol.* 2016;169:258-267.
57. Yeshaya A, Treister G. Pars plana vitrectomy for vitreous hemorrhage and retinal vein occlusion. *Ann Ophthalmol.* 1983;15(7):615-617.
58. Lam HD, Lahey JM, Kearney JJ, Ng RR, Lehmer JM, Tanaka SC. Young patients with branch retinal vein occlusion: a review of 60 cases. *Retina.* 2010;30(9):1520-1523.
59. Boyer DS, Faber D, Gupta S, et al. Dexamethasone intravitreal implant for treatment of diabetic macular edema in vitrectomized patients. *Retina.* 2011;31(5):915-923.
60. Iglicki M, Busch C, Lanzetta P, et al. Vitrectomized vs non-vitrectomized eyes in DEX implant treatment for DMO-Is there any difference? the VITDEX study. *Eye (Lond).* 2023;37(2):280-284.
61. Rezakallah A, Malclès A, Dot C, et al. Evaluation of Efficacy and Safety of Dexamethasone Intravitreal Implants of Vitrectomized and Nonvitrectomized Eyes in a Real-World Study. *J Ocul Pharmacol Ther.* 2018;34(8):596-602.
62. Wang JK, Huang TL, Chang PY, et al. Comparison of Intravitreal Dexamethasone Implant and Ranibizumab in Vitrectomized Eyes with Diabetic Macular Edema. *J Ophthalmol.* 2021;2021:8882539.
63. Hahn P. Successful treatment of neovascular age-related macular degeneration following single bevacizumab failure using aflibercept in a vitrectomized eye. *Clin Ophthalmol.* 2014;8:2129-2131.
64. Liang XL, Chen HY, Huang YS, et al. Pars plana vitrectomy and internal limiting membrane peeling for macular oedema secondary to retinal vein occlusion: a pilot study. *Ann Acad Med Singap.* 2007;36(4):293-297.
65. Raszevska-Steglinska M, Gozdek P, Cisiecki S, Michalewska Z, Michalewski J, Nawrocki J. Pars plana vitrectomy with ILM peeling for macular edema secondary to retinal vein occlusion. *Eur J Ophthalmol.* 2009;19(6):1055-1062.
66. Park DH, Kim IT. Long-term effects of vitrectomy and internal limiting membrane peeling for macular edema secondary to central retinal vein occlusion and hemiretinal vein occlusion. *Retina.* 2010;30(1):117-124.
67. Kumagai K, Ogino N, Fukami M, Furukawa M. Vitrectomy for macular edema due to retinal vein occlusion. *Clin Ophthalmol.* 2019;13:969-984.
68. Adelman RA, Parnes AJ, Bopp S, Saad Othman I, Ducournau D. Strategy for the management of macular edema in retinal vein occlusion: the European VitreoRetinal Society macular edema study. *Biomed Res Int.* 2015;2015:870987.
69. Nishida A, Kojima H, Kameda T, Mandai M, Kurimoto Y. Five-year outcomes of pars plana vitrectomy for macular edema associated with branch retinal vein occlusion. *Clin Ophthalmol.* 2017;11:369-375.
70. Vinod K, Gedde SJ, Feuer WJ, et al. Practice Preferences for Glaucoma Surgery: A Survey of the American Glaucoma Society. *J Glaucoma.* 2017;26(8):687-693.
71. Rehak J, Vymazal M. Kryotherapie zur Behandlung der neovaskulären Glaukome mit verschlossenem Kammerwinkel. [Cryotherapy in treatment of neovascular glaucoma with closed chamber angle]. *Klin Monbl Augenheilkd.* 1994;204(1):20-23. German.