

EFFECT OF INTRAVITREAL AFLIBERCEPT ON CORNEAL ENDOTHELIAL CELLS

Šulavíková Zuzana¹, Šustýkevičová Zuzana¹, Káčerik Marek¹, Krásnik Vladimír²

¹Department of Ophthalmology, University Hospital Trenčín, Slovakia

²Department of Ophthalmology, Faculty of Medicine, Comenius University and University Hospital, Bratislava, Slovakia

The authors of the study declare that no conflict of interests exists in the compilation, theme and subsequent publication of this professional communication, and that it is not supported by any pharmaceuticals company. The study has not been submitted to any other journal.

Submitted to the editorial board: December 22, 2023

Accepted for publication: February 5, 2024

Available on-line: March 15, 2024



MUDr. Zuzana Šulavíková, FEBO
Očná klinika, Fakultná nemocnica
Trenčín
Legionárska 28
911 71 Trenčín
E-mail: zuzana.sulavik@gmail.com

SUMMARY

Aim: To determine the effect of repeated intravitreal injections of aflibercept on the corneal endothelium in patients with diabetic macular edema (DME) and macular edema due to retinal vein occlusion (RVO).

Methods: In a prospective study conducted between January 2021 and November 2023, a total of 87 treatment-naïve eyes with DME and RVO were evaluated. The exclusion criteria were surgery or laser intervention during the follow-up period, contact lens wear, cataract surgery in the last 6 months, dystrophy, or other corneal condition that may cause endothelial damage. In addition to routine examinations on the day of application, we also measured the corneal endothelium using specular microscopy on the 1st, 4th and 8th day of injection. We evaluated 4 parameters: endothelial cell density (CD), hexagonality (HEX), coefficient of variability (CV) and central corneal thickness (CCT). First of all, we evaluated the entire cohort of eyes, and then divided it according to 2 criteria; the diagnosis into DME/RVO and according to the lens status into phakic/pseudophakic eyes.

Results: A total of 87 eyes of 68 patients were evaluated. The average age of the patients at the time of diagnosis was 66.8 ± 9.3 years. Within the cohort 51 (59%) eyes were phakic and 36 (41%) pseudophakic. A total of 61 (70%) eyes with a diagnosis of DME were treated, and 26 (30%) with RVO. During the follow-up, there were no significant changes in the average values of CD, HEX, CV, CCT due to aflibercept treatment, either in the whole group or in subgroups according to diagnosis or lens condition.

Conclusions: The results of this study suggest that intravitreal administration of aflibercept in patients with DME and RVO did not have an impact on corneal endothelial parameters, including CCT, HEX, CD and CV. These parameters were measured using endothelial microscopy during an 8-injection observation period.

Key words: aflibercept, corneal endothelium, endothelial cells, antiVEGF, specular microscope

Čes. a slov. Oftal., 80, 2024, No. 4, p. 202–207

INTRODUCTION

The endothelium is one of 6 layers of the cornea, and is formed by one layer of hexagonal shape cells [1,2]. It ensures the active transport of water out of the cornea, and is thereby responsible for the transparency, constant hydration and stable optical power of the cornea [3]. The density of the endothelial cells decreases with age by approximately 0.6% per year, from a number of 3400 cells/mm² at the age of 15 years to approx. 2300 cells/mm² at the age of 85. The physiological density of endothelial cells is stated as the number of 2000–3000 cells/mm² [4]. The principle of non-contact specular microscopy is to display the corneal endothelium with the use of a mirror reflec-

tion on the interface between the endothelium and the anterior chamber fluid. This is achieved by white light and a microscope with powerful enlargement. The specular microscope measures corneal thickness, and automatically segments and counts the endothelial cells. The instrument generates various indexes, which assist in the diagnosis and treatment of the cornea, for example cell density (CD), coefficient of variability (CV), hexagonality (HEX) and central corneal thickness (CCT) [5]. Studies have confirmed the presence of vascular endothelial growth factors (VEGF) and its receptors on the epithelium, stroma and corneal endothelium [6–10].

Intravitreally applied pharmaceuticals are eliminated from the eye by two paths: posteriorly via the blo-

od-retinal barrier, and anteriorly by means of drainage of the chamber fluid. However, several experimental studies have demonstrated that antiVEGF molecules are practically completely eliminated by the anterior pathway [11–13]. Aflibercept (Eylea®, Bayer) is a fusion protein which contains fragments of domains of human VEGF receptors 1 and 2, binding to the Fc fragment of human IgG1. It functions as a soluble substitute receptor, which binds VEGF-A and placental growth factor (PIGF), and thereby inhibits their binding to the receptor [14]. The pharmacokinetic profile of intravitreal application of 2.0 mg/0.05 ml aflibercept in humans has not yet been definitively clarified, but Do et al. have confirmed that the half-life of aflibercept in the chamber fluid following a single intravitreal application was 11 days in patients with age-related macular degeneration (AMD) [15]. Bevacizumab was detected in the anterior chamber even as long as one month after intravitreal application [12]. Our objective was to examine whether repeated intravitreal applications of aflibercept may adversely affect the endothelium and corneal thickness in patients with diabetic macular edema (DME) and macular edema upon a background of retinal vein occlusion (RVO).

MATERIAL AND METHOD

The prospective study conducted between January 2021 and November 2023 included a total of 87 eyes (68 patients) with a diagnosis of DME and RVO. All the patients were treatment-naïve, and had been indicated for intravitreal treatment with aflibercept. The exclusion criteria were other ocular surgical or

laser procedure during the follow-up period, contact lens wear, dystrophy or other corneal condition that may cause changes to the endothelium. The included pseudophakic eyes were more than 6 months after cataract surgery. On the day of application, we measured as standard best corrected distance visual acuity (BCVA) with the ETDRS optotype, intraocular pressure using a non-contact tonometer, anterior and posterior segment in mydriasis and central retinal thickness (CRT) on the optical coherence tomography (OCT). In addition to these routine examinations, on the day of the 1st, 4th and 8th injection we also examined the corneal endothelium (Fig. 1, 2). We performed endothelial microscopy with Nidek CEM-530 (Tokyo, Japan). We scanned the central cornea a size of 0.55 x 0.25 mm with the instrument configured in an automatic mode with auto-tracking. We conducted 5 measurements and evaluated the best quality scan. We evaluated 4 parameters: CD, HEX, CV and CCT. We then injected 0.05 ml of aflibercept intravitreally into the patient under sterile aseptic conditions under topical anesthesia. The results were statistically analysed with the use of descriptive statistics, a Chi-squared test and a t-test, the level of significance was set at $p = 0.05$.

RESULTS

Table 1 presents the basic demographic data. A total of 87 treatment-naïve eyes of 68 patients were included in the evaluation. The average age of the patients at the time of diagnosis was 66.8 ± 9.3 (33–87) years. The ratio of men to women was 52 (60%): 35 (40%). Of the total number of 87 eyes, 51 (59%)

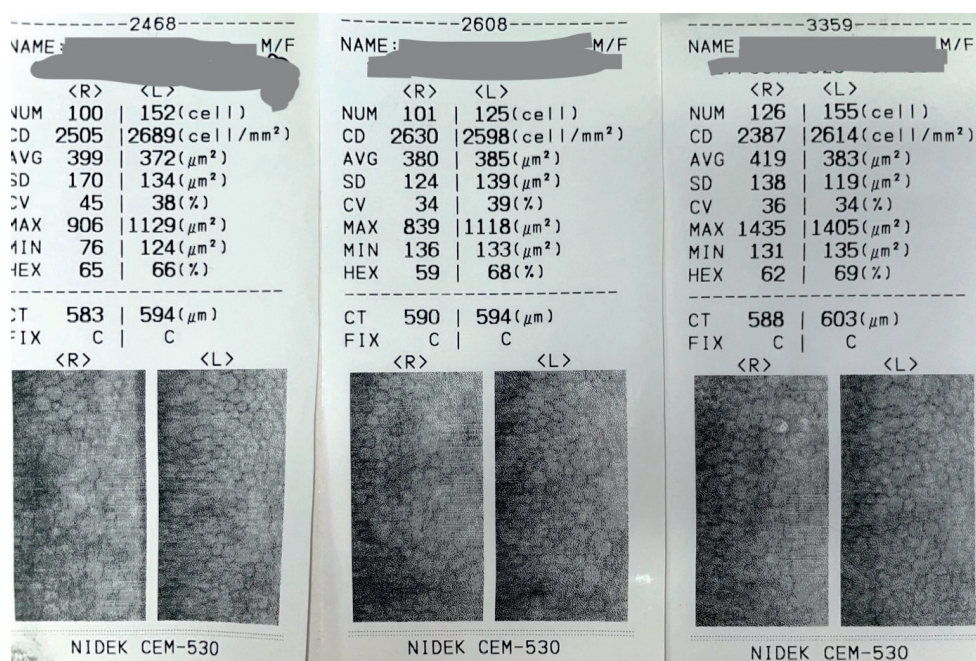


Figure 1. Corneal specular microscopy of 68-year-old pseudophakic patient with macular edema due to retinal vein occlusion on left eye on day of 1st, 4th and 8th application

were phakic and 36 (41%) pseudophakic. A total of 61 (70%) were treated with a diagnosis of DME, and 26 (30%) with a diagnosis of RVO; of the latter group 15 (17%) patients had branch RVO and 11 (13%) central RVO. The mean value of glycated hemoglobin in patients with diabetes mellitus (DM) was $7.6 \pm 0.7\%$ (5.9–9.9) DCCT, and 54 eyes (89%) had DME upon a background of type 2 DM.

Mean BCVA of all the patients on the day of the 1st injection was 53 ± 12 letters of ETDRS. A significant improvement to 60 ± 12 took place on the day of the 4th application, and again on the day of the 8th application to 62 ± 12 letters of ETDRS, ($p < 0.001$ for both in comparison with the 1st injection). Identically significant improvements also took place upon the division of the eyes according to diagnosis, in the group with DME (55 ± 11 ; 60 ± 11 ; 62 ± 13) and RVO (49 ± 13 ; 58 ± 13 ; 61 ± 12) letters of ETDRS.

Mean CRT measured on spectral OCT on the day of

the 1st injection of aflibercept was $565 \pm 151 \mu\text{m}$. On the day of the 4th application there was a significant reduction to $347 \pm 92 \mu\text{m}$ and on the day of the 8th application to $322 \pm 95 \mu\text{m}$, ($p < 0.001$ for both in comparison with the 1st injection). Significantly significant improvements were achieved also upon the division of the eyes according to diagnosis, in the group with DME (538 ± 127 ; 367 ± 83 ; 324 ± 90) and RVO (629 ± 185 ; 300 ± 95 ; 319 ± 107) μm .

We evaluated 4 parameters of the corneal endothelium measured with the aid of endothelial microscopy: CD, CV, CCT and HEX. First of all we evaluated the entire cohort of eyes and subsequently divided it according to 2 criteria; according to diagnosis into DME/RVO and according to the condition of the lens into phakic/pseudophakic eyes (Table 2).

Mean CD in all eyes on the day of the 1st application was $2669 \pm 346 \text{ bb/mm}^2$. On the day of the 4th (2642 ± 369

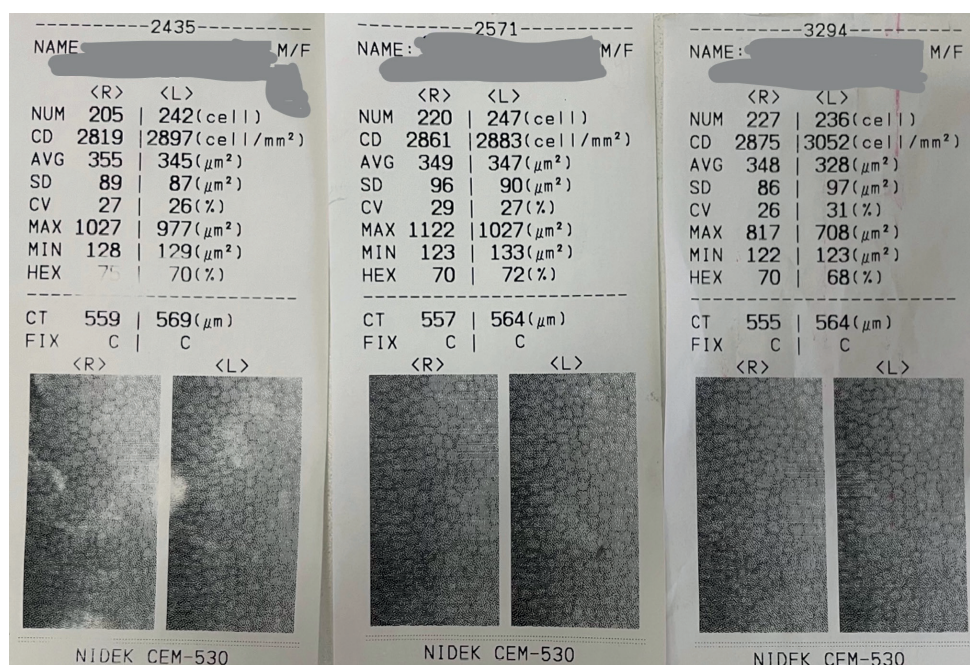


Figure 2. Corneal specular microscopy of 68-year-old phakic patient with diabetic macular edema due on right eye on day of 1st, 4th and 8th application

Table 1. Demographic and clinical characteristics of study eyes

| | |
|-----------------------|---------------------|
| All eyes | n = 87 |
| with DME | n = 61 (70%) |
| With RVO | n = 26 (30%) |
| Age in years | 66.8 ± 9.3 (33–87) |
| Male / female | 52 (60%) / 35 (40%) |
| Phakic / Pseudophakic | 51 (59%) / 36 (41%) |
| Right / left | 40 (46%) / 47 (54%) |

DME – diabetic macular edema, RVO – retinal vein occlusion

bb/mm²) and 8th application (2671 ±364 bb/mm²) we did not record a statistically significant difference in comparison with the values of the 1st injection. However, we recorded a difference ($p = 0.009$) in the mean value of CD

on the 1st and 8th day of application between the groups with RVO (2541 ±257; 2541 ±238) and DME (2724 ±365; 2732 ±399) bb/mm². An expected significant difference was confirmed also in mean CD between the group of

Table 2. Morphometric analysis of parameters measured by specular endothelial microscopy on day of 1st, 4th and 8th aflibercept application

| | 1 st | 4 th | 8 th application |
|---------------------------------------|-----------------|---------------------------|-----------------------------|
| All eyes | | | |
| Cell density (cells/mm ²) | 2669 ±346 | 2642 ±369 ($p = 0.279$) | 2671 ±364 ($p = 0.159$) |
| Coefficient of variability (%) | 30 ±5 | 31 ±4 ($p = 0.444$) | 31 ±4 ($p = 0.876$) |
| Hexagonality (%) | 68 ±4 | 68 ±4 ($p = 0.672$) | 66 ±7 ($p = 0.058$) |
| Central corneal density (μm) | 564 ±32 | 564 ±33 ($p = 0.155$) | 562 ±28 ($p = 0.329$) |
| Eyes | n = 87 | n = 84 | n = 59 |
| Phakic eyes | | | |
| Cell density (cells/mm ²) | 2731 ±334 | 2730 ±343 ($p = 0.368$) | 2696 ±363 ($p = 0.820$) |
| Coefficient of variability (%) | 30 ±5 | 30 ±4 ($p = 0.658$) | 30 ±5 ($p = 0.595$) |
| Hexagonality (%) | 68 ±4 | 68 ±4 ($p = 0.120$) | 66 ±6 ($p = 0.063$) |
| Central corneal thickness (μm) | 567 ±33 | 567 ±32 ($p = 0.630$) | 565 ±27 ($p = 0.652$) |
| Eyes | n = 51 | n = 49 | n = 35 |
| Pseudophakic eyes | | | |
| Cell density (cells/mm ²) | 2583 ±348 | 2520 ±372 ($p = 0.071$) | 2634 ±371 ($p = 0.089$) |
| Coefficient of variability (%) | 31 ±4 | 31 ±4 ($p = 0.490$) | 31 ±4 ($p = 0.772$) |
| Hexagonality (%) | 67 ±5 | 68 ±4 ($p = 0.326$) | 65 ±7 ($p = 0.395$) |
| Central corneal thickness (μm) | 559 ±31 | 560 ±34 ($p = 0.085$) | 558 ±29 ($p = 0.186$) |
| Eyes | n = 36 | n = 35 | n = 24 |
| DME eyes | | | |
| Cell density (cells/mm ²) | 2724 ±365 | 2684 ±391 ($p = 0.174$) | 2732 ±399 ($p = 0.068$) |
| Coefficient of variability (%) | 30 ±5 | 30 ±4 ($p = 0.522$) | 30 ±4 ($p = 0.821$) |
| Hexagonality (%) | 68 ±5 | 68 ±4 ($p = 0.731$) | 65 ±8 ($p = 0.091$) |
| Central corneal thickness (μm) | 564 ±29 | 565 ±31 ($p = 0.104$) | 561 ±27 ($p = 0.042$) |
| Eyes | n = 61 | n = 58 | n = 40 |
| RVO eyes | | | |
| Cell density (cells/mm ²) | 2541 ±257 | 2549 ±297 ($p = 0.704$) | 2541 ±238 ($p = 0.767$) |
| Coefficient of variability (%) | 31 ±4 | 31 ±4 ($p = 0.669$) | 32 ±5 ($p = 0.343$) |
| Hexagonality (%) | 68 ±4 | 68 ±4 ($p = 0.784$) | 67 ±3 ($p = 0.222$) |
| Central corneal thickness (μm) | 562 ±39 | 562 ±37 ($p = 0.977$) | 564 ±30 ($p = 0.671$) |
| Eyes | n = 26 | n = 26 | n = 19 |

p-value indicated the statistical significance of the difference between the 1st application values, DME – diabetic macular edema, RVO – retinal vein occlusion

phakic (2731 ± 334 ; 2730 ± 343 ; 2696 ± 363) and pseudophakic eyes (2583 ± 348 ; 2520 ± 372 ; 2634 ± 371) bb/mm², but no changes of endothelial cell density took place at the time due to the influence of the injections in the subgroups.

During the course of the follow-up period we did not record any significant change of the mean value of CV in all eyes (30 ± 5 ; 31 ± 4 ; 31 ± 4)%, or a change of HEX of the endothelial cells (68 ± 4 ; 68 ± 4 ; 66 ± 7)% or a change of mean CCT (564 ± 32 ; 564 ± 33 ; 562 ± 28) μ m. We also did not confirm any mutual differences in HEX and CV between the subgroups according to diagnosis or state of the lens. The only significant change in CCT was recorded in the group with DME, in terms of comparison of CCT on the day of the 8th application in comparison with the 1st application (from 564 to 561 μ m, $p = 0.042$).

Complete follow-up to 8th injection finish 59 (68%) of the original 87 eyes; of which 19 (73%) RVO and 40 (66%) DME eyes. Termination or suspension of treatment before the 8th injection took place due to improvement of the finding (3), exit (1), high level of glycated hemoglobin (10), non-responder with need to switch (9), necessity of pars plana vitrectomy due to epiretinal membrane (2), and for unknown reasons (3).

DISCUSSION

AntiVEGF treatment usually requires repeated intravitreal applications. Studies have demonstrated that VEGF and its receptors are exprimated on the corneal endothelium [6–10]. Experimental animal models have confirmed a certain concentration of antiVEGF molecules in the anterior chamber following their intravitreal application [16], and have also detected a reduction of CD following intracameral application of ranibizumab in rabbits [17]. Based on these facts also, the potential cytotoxic effect of antiVEGF molecules on the corneal epithelium is under investigation.

Papadakou observed the influence of DM alone on the parameters of the corneal endothelium, coming to the conclusion that CD was lower in patients with DM in comparison with a healthy control group [18]. In our cohort we did not record a decrease of CD in patients with DME (2724 ± 365 ; 2684 ± 391 ; 2732 ± 399) in comparison with RVO (2541 ± 257 ; 2499 ± 297 ; 2541 ± 238) bb/mm².

Urban observed the effect of antiVEGF molecules (ranibizumab and aflibercept) on the corneal epithelium in 110 eyes of patients with ARMD. At the end of the six-month observation period, a statistically significant reduction of CD was demonstrated in the group treated with aflibercept. The percentage of hexagonal cells was lower in both groups, and this study also demonstrated a slight increase of polymegathism [19]. It was also demonstrated that ranibizumab causes a minor and insignificant increase of CCT, whereas CCT remained unchanged in the group treated with aflibercept [19]. This is in contradiction with a publication by Chatzi-ralli, who also observed the influence of ranibizumab and aflibercept on the corneal endothelium in 36 patients with DME and determined that these molecules had no influence on the cornea, and after a 12-month follow-up period did not record any changes in CD, HEX, CV and CCT [20]. Joshi et al. did not record any changes on the endothelium in a cohort of 102 eyes during the first month after intravitreal application of ranibizumab, and there was no difference between phakic and pseudophakic eyes [21]. Doguizi also did not demonstrate cytotoxic effects on the endothelium after 4 applications of aflibercept in a cohort of 34 eyes with ARMD [22].

Our results are in accordance with publications that have not confirmed a significant effect on the parameters of the cornea measured on endothelial microscopy in patients with DME and RVO treated with aflibercept after the 8th application. The only significant change in CCT was recorded in the group with DME, specifically upon a of CCT on the day of the 8th application in comparison with the 1st application (from 564 to 561 μ m, $p = 0.042$). With reference to the absence of other changes of the endothelium, we consider this change non-pathological, random and clinically insignificant.

CONCLUSION

Our observations confirm that intravitreal injections of 2.0 mg/0.05 ml of aflibercept in patients with DME and RVO do not affect corneal epithelial parameters, including CCT, HEX, CD and CV. These parameters were evaluated using specular microscopy during an 8-injection observation period.

REFERENCES

1. Sridhar MS. Anatomy of cornea and ocular surface. *Indian J Ophthalmol.* 2018;66:190-194.
2. Dua HS, Faraj LA, Said DG, Gray T, Lowe J. Human corneal anatomy redened: a novel pre-Descemet's layer (Dua's layer). *Ophthalmology.* 2013;120(9):1778-1785.
3. Salmon JF. *Kanski's Clinical Ophthalmology*, 9th edition. Londýn: Elsevier 2020;204-516. ISBN: 978-0-7020-7711-1.
4. Van den Bogerd B, Zakaria N, Adam B, et al. Corneal Endothelial Cells Over the Past Decade: Are We Missing the Mark(er)? *Transl Vis Sci Technol.* 2019;13:1-9.
5. Chaurasia S, Vanathi M. Specular microscopy in clinical practice. *Indian J Ophthalmol.* 2021;66:517-524.
6. Gan L, Fagerholm P, Palmblad J. Vascular endothelial growth factor (VEGF) and its receptor VEGFR-2 in the regulation of corneal neovascularization and wound healing. *Acta Ophthalmol Scand.* 2004;82:557-563.
7. Philipp W, Speicher L, Humpel C. Expression of vascular endothelial growth factor and its receptors in inflamed and vascularized human corneas. *Invest Ophthalmol Vis Sci.* 2000;41:2514-2522.

8. Ambati BK, Nozaki M, Singh N, et al. Corneal avascularity is due to soluble VEGF receptor-1. *Nature*. 2006;443:993-997.
9. Chalam KV, Agarwal S, Brar VS, Murthy RK, Sharma RK. Evaluation of cytotoxic effects of bevacizumab on human corneal cells. *Cornea*. 2009;28:328-333.
10. Liarakos VS, Papaconstantinou D, Vergados I, Douvali M, Theodossiadis PG. The effect of subconjunctival ranibizumab on corneal and anterior segment neovascularization: study on an animal model. *Eur J Ophthalmol*. 2014;24:299-308.
11. Rimpelä AK, Kiiski I, Deng F, Kidron H, Urtti A. Pharmacokinetic simulations of intravitreal biologicals: aspects of drug delivery to the posterior and anterior segments. *Pharmaceutics*. 2018; 11:9-10.
12. Bakri SJ, Snyder MR, Reid JM, Pulido JS, Ezzat MK, Singh RJ. Pharmacokinetics of intravitreal ranibizumab (Lucentis). *Ophthalmology*. 2007;114:2179-2182.
13. Park SJ, Choi Y, Na YM et al. Intraocular pharmacokinetics of intravitreal aflibercept (Eylea) in a rabbit model. *Invest Ophthalmol & Vis Sci*. 2016;57:2612-2617.
14. Summary of Product Characteristics of Eylea® [Internet]. Date of revision: 13.7.2017. [cited 2023 Dec 17]. Available from: https://www.ema.europa.eu/en/documents/product-information/eylea-epar-product-information_en.pdf
15. Do DV, Rhoades W, Nguyen QD. Pharmacokinetic study of intravitreal aflibercept in humans with neovascular age-related macular degeneration. *Retina*. 2020;40:643-647.
16. Niwa Y, Kakinoki M, Sawada T, Wang X, Ohji M. Ranibizumab and aflibercept: intraocular pharmacokinetics and their effects on aqueous VEGF level in vitrectomized and nonvitrectomized macaque eyes. *Invest Ophthalmol Vis Sci*. 2015;56:6501-6505.
17. Ari S, Nergiz Y, Aksit I, Sahin A, Cingu K, Caca I. Evaluation of intracameral injection of ranibizumab and bevacizumab on the corneal endothelium by scanning electron microscopy. *J Ocul Pharmacol Ther*. 2015;31:100-105.
18. Papadakou P, Chatziralli I, Papathanassiou M, et al. The effect of diabetes mellitus on corneal endothelial cells and central corneal thickness: a case-control study. *Ophthalmic Res*. 2020;63:550-554.
19. Urban B, Szwabowicz M, Bakunowicz-Lazarczyk A. Effect of Repeated Intravitreal Ranibizumab and Aflibercept Injections on the Cornea in Patients with Age-Related Macular Degeneration. *J Ophthalmol*. 2020;49:28905.
20. Chatziralli I, Papadakou P, Dimitriou E, et al. The effect of intravitreal anti-vascular endothelial growth factor injections on corneal endothelium in patients with diabetic macular oedema. *Cutan Ocul Toxicol*. 2021;40:66-69.
21. Joshi M, Naik MP, Sarkar L. Effect of intravitreal anti-vascular endothelial growth factor on corneal endothelial cell count and central corneal thickness in Indian population. *J Family Med Prim Care*. 2019;8:2429-2432.
22. Doguizi S, Sekeroglu MA, Inanc M, Yilmazbas P. Effect of Aflibercept on Human Corneal Endothelial Cells in Neovascular Age-Related Macular Degeneration: A Pilot Study. *Ret vit*. 2019;28:13-18.