

INTRAVENOUS THROMBOLYTIC THERAPY FOR ACUTE NONARTERITIC CENTRAL RETINAL ARTERY OCCLUSION. A REVIEW

Janská K.¹, Bodnár R.¹, Janský P.², Vosko M.³

¹Department of Ophthalmology, Regional Hospital, Příbram, Czech Republic

²Department of Neurology, Charles University and Motol University Hospital, Prague, Czech Republic


³Department of Neurology 2, Kepler Universitätsklinikum, Med Campus III, Linz, Austria

The authors of the study declare that no conflict of interests exists in the compilation, theme and subsequent publication of this professional communication, and that it is not supported by any pharmaceutical company. The study has not been submitted to any other journal, nor has it been printed elsewhere, with the exception of congress abstracts and recommended procedures.

Received: 15. 5. 2021

Accepted: 31. 8. 2021

Available on-line: 20 December 2021



MUDr. Kamila Janská
Oční oddělení ON Příbram
Generála R. Tesaříka 80
261 01 Příbram
E-mail: kamila.janska@post.cz

SUMMARY

Central retinal artery occlusion (CRAO) is a form of acute ischemic stroke. It is a critical condition that often leads to severe visual loss or blindness and can be a harbinger of further cerebrovascular events. Due to the lack of scientific data, there are no effective evidence-based forms of therapy for this condition. None of the conservative therapies have proven effective. The results of some previously published studies suggest a benefit of intravenous thrombolytic therapy in the same regimen as in the treatment of ischemic stroke.

This work aims to present an overview of published clinical studies focused on the use of intravenous thrombolysis for CRAO, evaluate its efficacy and safety, and propose an optimal diagnostic and therapeutic algorithm for acute management of CRAO.

Summary statistics of patient data from relevant studies indicate that a significant visual acuity improvement was achieved by a total of 45 % of patients receiving alteplase within 4.5 hours of symptoms onset. The occurrence of adverse events in this time window was not significant. Intravenous thrombolytic therapy in CRAO thus appears to be effective and safe. However, we still lack data from adequate prospective randomized controlled trials to confirm this conclusion. To date, two randomized trials are being conducted. The intravenous thrombolysis administration, patient monitoring, etiologic workup, and setting of effective secondary prevention should be ensured at the centre of highly specialized cerebrovascular care. Urgent transport of the CRAO patient to the nearest centre is essential.

Key words: central retinal artery occlusion, thrombolysis, alteplase, visual acuity

INTRODUCTION

Central retinal artery occlusion (CRAO) is an acute condition that often leads to severe visual impairment or blindness. Most cases (95 %) are thromboembolic in origin, and they are termed a nonarteritic form of CRAO [1]. Data describing the incidence of CRAO are highly variable. The reported annual incidence varies from 1-15 cases per 100 000 population [2]. The incidence of acute CRAO (symptoms for less than 48 hours) is significantly lower, reaching a value of 0.85 per 100 000 population [3]. The incidence increases with age, with the patient's average age between 65 and 70 years [4,5]. Bilateral incidence appears in 1–2 % of patients [6]. Although most patients

experience spontaneous improvement of central visual acuity after occlusion, only 17 % report improved vision to a functional level [7].

According to the current definition of the American Heart Association and the American Stroke Association, occlusion of the central retinal artery (together with occlusion of the ophthalmic artery) is classified as an ischemic stroke [8]. The recommended management of acute CRAO has not yet been defined by Czech and European professional neurological and ophthalmological societies, due to a lack of relevant data. Various procedures in treating CRAO have been evaluated in clinical trials (e.g. anterior chamber paracentesis, ocular massage, hyperbaric oxygen, intravenous acetazolamide or ma-

nnitol therapy, sublingual nitrate therapy, haemodilution). None have proven to have a higher efficacy than a placebo and thus are not recommended in professional guidelines [2,7,9,10]. In terms of intra-arterial thrombolysis administered locally into the ophthalmic artery – the only randomised trial conducted in 2010, the EAGLE trial, was terminated due to ineffectiveness and significantly higher complication rates in the intervention group [11]. The current 2019 American Academy of Ophthalmology guideline for managing acute CRAO recommends immediately transferring the patient to the nearest Primary Stroke Centre or Comprehensive Stroke Centre for observation during hospitalisation, due to the increased risk of ischaemic stroke, investigation of the aetiology, and deployment of effective secondary prevention. The administration of intravenous thrombolysis (IVT) is considered as a controversial therapeutic approach, with a quality of evidence rating of IIA [10].

IVT is an established treatment for acute ischaemic stroke, also used in practice to treat acute CRAO [12]. Today, the only approved thrombolytics for treating acute ischaemic stroke are alteplase (tissue plasminogen activator, t-PA, company name of Actilyse®) and tenecteplase (genetically modified t-PA, allows bolus administration, company name of Metalyse®). Other fibrinolytic agents are discouraged, due to lower efficacy and a higher risk of complications [13]. Although current guideline recommendations do not yet support the use of IVT in the treatment of CRAO, studies have suggested that IVT may be beneficial in patients with CRAO under certain circumstances [7,14–20].

ARTERIAL SUPPLY TO THE RETINA AND THE PATHOGENESIS OF CRAO

The eyeball is nourished (as is the entire orbit and some other nasal, facial and meningeal structures) by the ophthalmic artery (OA). In more than 90% of the population, this artery is the first intradural branch of the internal carotid artery, from which it most often branches off just after the cavernous sinus passage. In its course, it has numerous anastomoses between the intracranial and extracranial vascular systems. Rarely, the OA may be a branch of the external carotid artery, another segment of the internal carotid artery, or even another intracranial artery [21].

The central retinal artery (CRA) is the first branch of the OA and supplies the inner layers of the retina. The choroid plexus nourishes the outer retina and choroid (supply area of the posterior ciliary artery, a branch of the OA). The CRA has three sections: (1) the intraorbital segment (extending from the origin to the point where it pierces the dural sheath of the optic nerve); (2) the intravaginal segment (the course of the artery between the optic nerve and its sheath); and (3) the intraneural segment (the section of artery lying within the optic nerve itself). It then emerges in the optic nerve head, where it branches. The artery's diameter at the optic nerve head is approximately 160 µm [22]. The CRA is constricted at two

points in its course: as it passes through the dural sac and the lamina cribrosa [23]. These two narrowings represent the most likely sites at which an embolus will lodge in CRAO [24]. The CRA is an end artery and has no significant anastomoses [21]. In 10–30% of the population, there is a variant supply to the macular region via the cilioretinal artery. This artery is a branch of the short posterior ciliary artery and is thus not dependent on the patency of the CRA. Its presence may protect the central visual field in CRAO [25,26].

CRA occlusion causes the interruption of the blood supply and immediate impairment of retinal function. The occluded artery may spontaneously recanalise, and the blood supply may be restored. However, irreversible tissue damage will follow if the occlusion lasts too long and visual function remains permanently impaired [1]. Studies in animal models (rhesus macaque monkeys) have shown that retinal cells tolerate absolute ischaemia for 120–240 minutes [27]. In practice, however, during CRAO, the supply is often not entirely interrupted, and retinal cell survival may be prolonged. Several studies have shown that recanalisation up to 270 minutes (4.5 hours) after the onset of symptoms could save at least some of the retinal cells [28–33]. This time period also corresponds to the time window for the administration of thrombolysis in acute ischaemic stroke [6,7,24].

AETIOLOGY AND RISK FACTORS OF CRAO

Vascular risk factors have been described in 78% of patients with CRAO and are identical to those in patients with ischaemic stroke. Arterial hypertension was noted in 73% of patients, critical stenosis of the internal carotid artery in 22%, atrial fibrillation in 20%, and valvular heart disease in 17% of patients with CRA closure [34]. There is an increased risk of ischaemic stroke, especially in the first 4 weeks after CRAO, reaching 3–6% [34,35]. Concurrent ischaemic stroke occurred in 20–24% of patients with CRAO, but these were mainly small asymptomatic lesions detectable only by MRI [36].

As with ischaemic stroke, many diseases and pathologies leading to or contributing to CRAO have been described. We do not possess sufficient systematic data to define the exact representation of various causes. Some are mentioned in case studies only, and in addition, the causes can coexist [37–40]. Organisation into aetiological groups represents a certain simplification. In practice, the TOAST classification for ischaemic stroke is the most widely used system. It divides the aetiological situations into 5 groups (large vessel disease, cardioembolism, small vessel disease, other specified cause, and undetermined cause) [41]. Large vessel disease (macroangiopathy) is the essential aetiological group responsible for CRAO, and the embolisation from atherosclerotic plaques of the ipsilateral internal carotid artery is the most frequent finding. Embolisation from the aortic arch occurs less frequently. Cardioembolism is the second leading aetiological group, mainly atrial fibrillation, when embolisation derives from a thrombus

formed in the left atrium [37,42]. In addition to blood stasis caused by the limitation of myocardial contractility in arrhythmias, endothelial damage and hypercoagulability in the left atrium can also contribute to thrombus formation [43]. Small vessel disease (microangiopathy) is another aetiological group. Small vessels are affected by degenerative processes in arterial hypertension or diabetes mellitus. The group of other causes includes vasculitides, non-inflammatory vasculopathies, genetic microangiopathies, and hypercoagulable states [37,41,42]. CRAO associated with vasculitis, most commonly temporal arteritis, is called arteritic, and accounts for approximately 5% of all cases of CRAO [1]. It usually occurs in patients over 50 years of age. The clinical features distinguishing it from the nonarteritic form are headache, general fatigue, polymyalgia, weight loss of unclear aetiology, or claudication from chewing. In laboratory results, an elevated erythrocyte sedimentation rate is always present. No embolus is visible upon fundus examination [6,20]. It can also be distinguished from nonarteritic CRAO by the absence of a "spot sign" on ultrasound examination [44]. Arteritic CRAO requires different management with the therapeutic use of corticosteroids. We do not address this further in our study. In a significant number of patients with CRAO (as with ischaemic stroke), the aetiology remains undetermined. It can be caused by inadequate investigation, the coexistence of multiple identified causes, or true cryptogenic aetiology. However, accurate determination of the aetiology is crucial for the subsequent setting of optimal secondary prevention (antiplatelet or anticoagulation therapy) [6,10].

CLINICAL PRESENTATION OF CRAO

Patients with CRAO typically present with a painless sudden monocular decrease or loss of visual function. The severity of the decrease in visual acuity (VA) depends on the degree of CRA obstruction and the variable presence of the cilioretinal artery. Thus, VA may vary from fully preserved visual acuity to no light perception. Episodes of amaurosis fugax may precede the occlusion itself [10].

CRAO is accompanied by characteristic fundus findings and changes of the retinal appearance. In the early phase after occlusion, changes are usually very discrete or completely absent. The typically described whitish appearance of the retina with a cherry spot in the macula usually develops after several hours of occlusion (Figure 1). The pale appearance of the retina is due to opacification of the retinal nerve fibre layer in ischaemic oedema [10,24]. Oedema increases with time from the onset of ischaemia, and we can quantify its size by measuring the retinal thickness on OCT [45]. The image of a cherry spot is formed by the contrast of the perfused choroid (whose vascular supply is not disturbed in CRAO) visible through the centre of the macula against the surrounding pale, oedematous retina. Other typical fundus findings in CRAO include segmentation of the blood column in the vessels, alteration of the arteriovenous ratio, and arterial attenuation. We observe a relative afferent pupillary defect, the

degree of which correlates with the severity of ischaemia [10,46].

Embolic obstruction of the CRA is most commonly found in the retrobulbar space, but fragments of these emboli can be detected on the eye fundus in 40% of patients with CRAO [46,47]. Their appearance may point to a possible aetiology of CRAO [48]. The most commonly encountered bright yellow and shiny mixed emboli (Hollenhorst plaques) are composed of cholesterol, fibrin, and platelets. These emboli are usually located at the branch points of the retinal arteries and most often originate from atheromatous plaques of the internal carotid artery, heart valves, or aortic arch. Another common type is elongated whitish embolus, purely thrombotic, aetiologically related to atrial fibrillation [37]. The third most common type of embolus is composed of calcium and fibrin, is whitish, and usually originates from calcified heart valves. All these types of emboli are subject to fibrinolysis [24].

Optic nerve atrophy and the presence of cilioretinal collaterals can be noted several weeks after occlusion. Within five months after occlusion, 18% of patients develop neovascularisation of the iris, accompanied by elevation of intraocular pressure [49]. Neovascularisation of the optic disc is another potential complication of CRAO, and its prevalence varies from 2.5 to 31.6% [50].

STUDIES EVALUATING INTRAVENOUS THROMBOLYSIS IN CRAO

Although the first trials of IVT in the treatment of CRAO date back to 1966, this therapy has still not yet achieved widespread use. To date, there is a lack of large-scale pro-

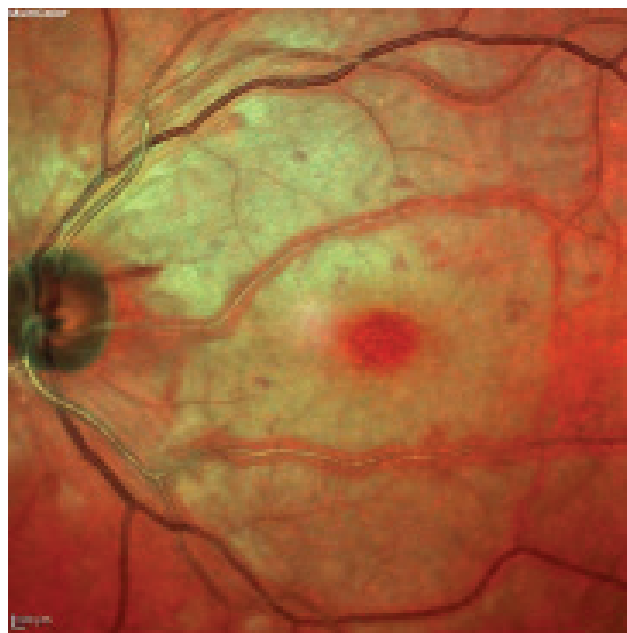

Figure 1. Fundus photography of the left eye: patient 6.5 hours after the onset of CRAO symptoms, retinal whitening and a cherry-red spot in macula.

CRAO – central retinal artery occlusion

spective randomised trials to evaluate its efficacy [51]. Two meta-analyses summarise the results of the studies conducted to date. Shrag et al. conducted a meta-analysis in 2015. He categorised patients with CRAO into three groups (396 patients without treatment, 419 patients treated with conservative therapy, 147 patients treated with IVT receiving different fibrinolytics) [7]. Of the 34 patients who received thrombolysis within 4.5 hours from the onset of symptoms, 17 patients (50%) had recovery of visual functions. No effect of IVT was observed in patients treated after 4.5 hours from the onset of symptoms. A recent meta-analysis by Wang et al. in 2020 included 121 patients with CRAO treated with alteplase, resulting in a significant improvement in VA in 62 patients (52%) [52]. Unfortunately, the authors of this work did not evaluate the time from the onset of the symptoms to IVT administration. The predictive value of the meta-analyses performed is limited, as they include studies of heterogeneous patient composition (after branch retinal artery occlusion or combined arteriovenous central retinal occlusion), the use of different obsolete fibrinolytic agents (streptokinase, urokinase), additional therapeutic modalities (e.g. Wang et al. included data from a Chinese study, where they administered the anticholinergic agent anisodine along with IVT [53]), as well as different time windows for

administering IVT. Moreover, the definition of significant improvement in VA is not uniform between studies.

To date, there are results from only six studies (Table 1) evaluating IVT with the use of alteplase in patients with CRAO (no trials with tenecteplase have been conducted so far) – four prospective interventional studies, one retrospective analysis, and one randomised, double-blind trial that was terminated prematurely in phase II [15-20]. A total of 109 patients were enrolled in these studies, of whom 58 (53%) received IVT within 4.5 hours from the onset of symptoms. In five trials, they administered thrombolysis in the regimen that is standard in the treatment of acute ischaemic stroke, i.e. intravenously administered t-PA at a dose of 0.9 mg/kg (not to exceed 90 mg total dose), 10% of the total dose as an initial IV bolus over 1 minute and the remainder infused over 60 minutes [15,17-20].

In a pilot prospective study by Kattah et al. from 2002, 12 patients with CRAO received thrombolysis, 6 of them within 4.5 hours from the onset of symptoms [15]. Four of the 6 patients (66%), who were treated early, experienced an improvement in VA, but the significance of the improvement was unreported. In the subsequent 3-month follow-up, the long-term effect of therapy was confirmed. Information on patients who received IVT 4.5-6 hours after the onset of symptoms is not available.

Table 1. Characteristics of studies evaluating the use of IVT in patients with CRAO

Author, Year, Country	Study Type	No.	Mean age (range) years	Definition of the significant VA	No. Subjects receiving t-PA ≤ 4.5 H after symptoms' onset	No. Subjects with significant VA	No. Subjects receiving t-PA 4.5–6 H after symptoms' onset	No. Subjects with significant VA
Kattah et al., 2002, USA	Pilot prospective study	12	71.4 (53–89)	Parameters of significant VA improvement undefined	6	4 (67 %)	N/A	N/A
Hattenbach et al., 2008, Germany	Prospective interventional case series	28	63.3 (30–85)	Increase of ≥ 3 Snellen lines	7	3 (43 %)	10	4 (40 %)
Chen et al., 2011, Australia	Randomized controlled trial	8	73	Increase of ≥ 3 Snellen lines	1	1 (100 %)	1	1 (100 %)
Nedelmann et al., 2015, Germany	Prospective interventional case series	11	69.8 (45–88)	BCVA ≥ 0.6 in decimal VA	7	2 (28 %)	1	1 (100 %)
Preterre et al., 2017, France	Retrospective analysis	30	62.5	Decrease of ≥ 0.3 logMAR	17	10 (59 %)	13	7 (54 %)
Schultheiss et al., 2018, Germany	Prospective interventional case series	20	72.8 (47–92)	BCVA ≤ 0.5 logMAR	20	6 (30 %)	0	0
Total number of patients		109			58	26 (45 %)	25	13 (52 %)

CRAO – central retinal artery occlusion, BCVA – best corrected visual acuity, H – hours, t-PA – alteplase, VA – visual acuity

Significant complications of IVT administration, including bleeding, were not observed.

A prospective study published by Hattenbach et al. in 2008 included 28 patients with CRAO treated with IVT [16]. Seven patients received thrombolysis within 4.5 hours from the onset of symptoms, three of whom (43 %) achieved significant VA improvement (improvement of 3 Snellen lines or more). Of the 10 patients who received IVT 4.5 to 6 hours from the onset of symptoms, 4 (40 %) showed VA improvement. In the remaining patients treated more than 6 hours from the onset of symptoms, the effect of IVT was not observed. In this study, patients did not receive t-PA as per the current cerebral ischaemia protocol. Patients received a fixed dose of 50 mg t-PA. IV heparin was started at 1 200 units daily for the next 5 days, while monitoring activated partial thromboplastin (aPTT; target range 60–80 seconds). No bleeding complications were observed in this study.

The only randomised, double-blind trial to date was published by Chen et al. in 2011 [17]. It included 16 patients with symptoms lasting from 4 to 24 hours. Eight patients received IVT, but only one patient received thrombolysis within 4.5 hours and one within six hours from the onset of symptoms. These patients showed a significant improvement in VA of more than three Snellen lines at the 1-week follow-up. The improvement in VA was not permanent, and at the 6-month follow-up, a decrease in visual acuity was again present. One patient suffered from haemophthalmos with retinal neovascularisation. In the other patient, the cause was not specified. The remaining six patients had no improvement in VA. The explanation could be the late administration of thrombolysis (mean time of t-PA administration from the onset of the symptoms was $14.4 \text{ h} \pm 6.5$). There was one serious adverse event in the study. Symptomatic intracranial haemorrhage was described in one patient with cerebral amyloid angiopathy, after which the study was prematurely terminated.

The results of a study published by Nedelmann et al. in 2015 are interesting [18]. They divided a cohort of 11 patients treated with IVT for CRAO into two groups, based on the presence of a so-called retrobulbar spot sign (hyperechogenic structure at the CRA site) on B-mode ultrasound. In the 7 patients with this hyperechogenic structure, there was no improvement in VA. By contrast, of the 4 patients with negative retrobulbar spot sign, all achieved VA improvement. Two received IVT within 4.5 hours and the other two after 5.5 and 9 hours, respectively, from the onset of symptoms. This surprisingly absolute correlation was explained by the fact that a positive sonographic finding may indicate the presence of a calcium-based embolus, which is less suitable for thrombolysis, compared with a fibrin-based clot. The administration of IVT was without bleeding complications in this study.

In a 2017 retrospective study, Préterre et al. evaluated the efficacy of IVT in treating 30 patients with CRAO, 17 of whom received thrombolysis within 4.5 hours and the rest within 6 hours from the onset of symptoms [19]. Over-

rall, 55 % of patients achieved a significant improvement in VA. In this study, symptomatic intracranial bleeding was noted in one patient who received intravenous heparin concomitantly with thrombolysis, which constitutes a protocol violation as per the current protocol for alteplase administration. Asymptomatic intracranial haemorrhage was described in two other patients and haematuria in one patient. It is not clear from the published data whether the standard IVT procedure was followed in these cases.

Schultheiss et al. included 20 patients with CRAO with symptom duration of up to 4.5 hours in their 2018 study [20]. Six patients (30 %) experienced significant improvement in VA after IVT. Complications of IVT occurred in two patients (orolingual angioedema, bleeding from an abdominal aortic aneurysm), from which both patients recovered without any sequelae.

Summarising the results of the six studies described above, in a total sample of 58 patients with t-PA administration within 4.5 hours from the onset of symptoms, VA improved in 26 (45 %), of whom 22 patients met the conditions (defined for the study) for significant improvement in VA, and in 4 patients, the significance of improvement was unreported. Of the 25 patients treated 4.5–6 hours from the onset of symptoms, the effect of IVT was observed in 13 (52 %). At IVT administration time beyond 6 hours from the onset of symptoms, the effect of IVT was confirmed in only one patient. When IVT was administered within 6 hours from the onset of symptoms, the calculated 30 % absolute risk reduction corresponds to an excellent number needed to treat (NNT) of 3.3. In comparison, for ischaemic stroke, the NNT (favourable outcome defined by a value of 0–2 on the modified Rankin Scale) when IVT is administered within 4.5 hours from the onset of symptoms is 14, and when administered within 1.5 hours from the onset of symptoms, the NNT is 2 [53]. According to data from these studies, complications of standard IVT administered in patients after CRAO within 4.5 hours from the onset of symptoms are insignificant. The incidence and severity of intracranial haemorrhages increase with the length of delay in IVT administration. The cause may be the haemorrhagic transformation of concomitant asymptomatic ischaemic strokes induced by IVT administration after a safe time window [36].

In order to test the efficacy and safety of IVT in the treatment of acute CRAO, two randomised, double-blind, placebo-controlled, multicentre trials, enrolling patients with CRAO symptoms lasting less than 4.5 hours from the onset of symptoms are currently underway: the French THEIA trial (NCT03197194, recruiting until September 2022) and the Norwegian TENCRAOS trial (NCT04526951, recruiting until January 2024). Exclusion criteria are clinical or laboratory evidence of temporal arteritis, combined arteriovenous occlusion, severe retinopathy (e.g. diabetic proliferative retinopathy), presence of cilioretinal artery, intraocular pressure above 30 mmHg and VA better than 0.05 (THEIA study) or 0.1 (TENCRAOS study). In both studies, 70–80 patients are expected to be enro-

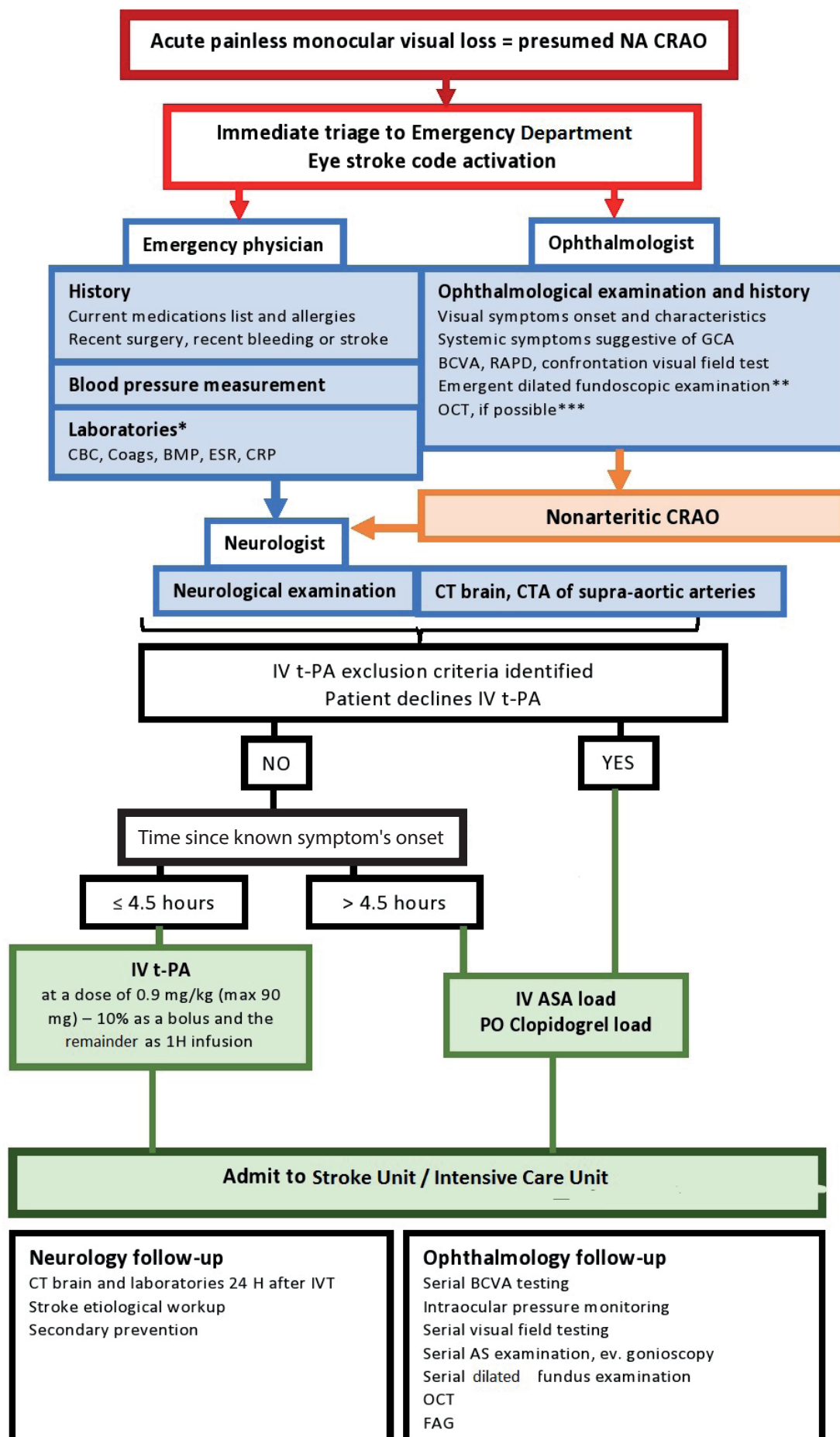


Figure 2. Proposed diagnostic and therapeutic algorithm for management of patients with acute nonarteritic CRAO

CRAO – central retinal artery occlusion, AS – anterior segment, ASA – acetylsalicylic acid, BMP – basic metabolic profile, BCVA – best corrected visual acuity, CBC – cell blood count, Coags – coagulation parameters, CRP – C-reactive protein, CTA – CT angiography, ESR – erythrocyte sedimentation rate, FAG – fluorescein angiography, GCA – giant cell arteritis, H – hour, IV – intravenous, NA – nonarteritic, OCT – optical coherence tomography, PO – oral, RAPD – relative afferent pupillary defect, t-PA – alteplase

* We wait only for the laboratory results of glycaemia before IVT administration; if necessary, for CRP in a finding suspicious of GCA. We wait for the results of coagulation parameters if the patient is taking anticoagulants, or if thrombocytopenia or bleeding disorder is suspected.

** The ophthalmological evaluation should be limited to what is necessary to confirm the diagnosis and to rule out ocular contraindications for thrombolytic treatment. Fundoscopic imaging with a nonmydriatic fundus camera should be obtained whenever possible.

*** Retinal thickness measured on OCT may be used to quantify retinal oedema (which correlates with the time elapsed since the retinal ischaemia onset).

lled, with half treated with alteplase (THEIA) or tenecteplase (TENCRAOS). The control group in both studies will receive 300 mg of acetylsalicylic acid. There is also ongoing recruitment (until the end of 2021) in the international Austrian Registry of Thrombolysis for Recovery of Vision in Acute Central Retinal Artery Occlusion (AR-VISION), which, in addition to evaluating the effect of IVT and risk factor analysis, also compares the effect of IVT and conservative management of CRAO on the number of ischaemic lesions on brain MRI.

DIAGNOSTIC AND THERAPEUTIC ALGORITHM

The care of patients with CRAO is at the interface of Neurology and Ophthalmology, and awareness of the optimal management of this condition is often insufficient among physicians in either specialisation. According to a US survey, only 18% of vitreoretinal specialists and 75% of neurologists would refer a patient with acute CRAO to a Stroke Centre [55]. In the absence of recommendations from professional societies, we propose a diagnostic and therapeutic algorithm for managing acute CRAO, based on the established procedure for IVT in the treatment of

ischaemic stroke in the Czech Republic (Figure 2). When CRAO is suspected, it is necessary to arrange the immediate transfer of the patient to the nearest Primary Stroke Centre (33 in the Czech Republic) or Comprehensive Stroke Centre (13 in the Czech Republic) (Figure 3). If the patient is referred from an Eye Clinic, it is advantageous to examine the VA and to administer mydriatic agents prior to transfer. The receiving centre will be informed by the ambulance crew (CRAO alert) of the expected time of arrival, to ensure the availability of the neurologist and ophthalmologist in the Emergency Department. On arrival at the hospital facility, the aim is to minimise the delay of IVT administration (door-to-needle time) by performing the necessary diagnostic procedures as quickly as possible. The emergency physician (or neurologist) takes a medical history, arranges for blood draws, and examines the patient to rule out contraindications for IVT (intracranial or other significant acute or recent bleeding, uncontrolled blood pressure, haemorrhagic diathesis, effective anticoagulation therapy, known significant aneurysm or dissection, known infective endocarditis, peripartum period, and other relative contraindications).

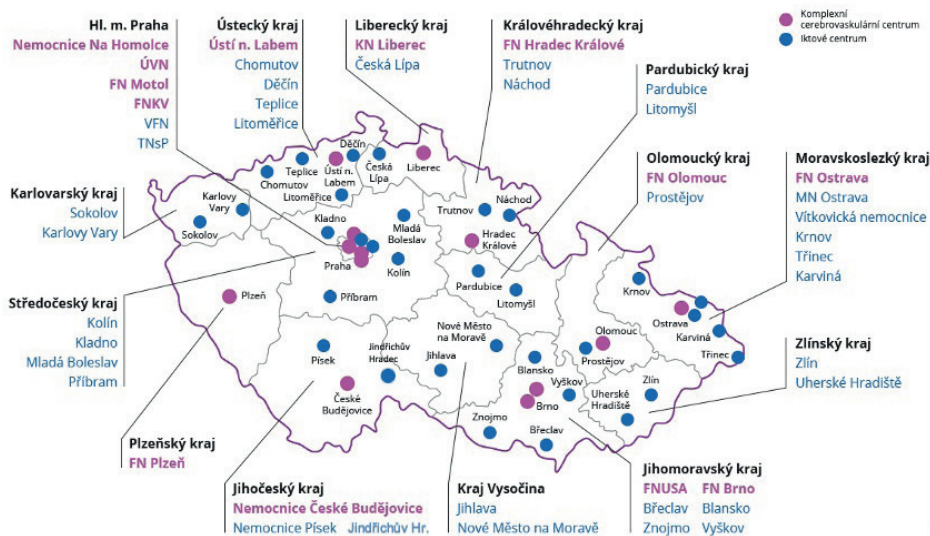


Figure 3. Specialised Stroke Centres in the Czech Republic

The ophthalmologist will confirm the diagnosis of non-arteritic CRAO and rule out ocular contraindications for IVT administration. Ocular contraindications (according to the criteria of the ongoing THEIA and TENCRAOS studies) include elevation of intraocular pressure above 30 mmHg, VA better than 0.1, clinical or laboratory evidence of temporal arteritis, combined arteriovenous occlusion, branch occlusion of the CRA, CRAO without foveal ischaemia, haemophthalmos, active choroidal neovascularisation, proliferative diabetic retinopathy, or other severe retinopathy. After ruling out haemorrhage on the brain CT, the neurologist will indicate thrombolysis, and the patient is admitted to the Neurological Intensive Care Unit for monitoring, aetiology investigation, and setting up appropriate secondary prevention.

CONCLUSIONS

Although IVT is a standard treatment for ischaemic stroke, its use in CRAO is not so common. However, according to the results of the performed studies, it seems that the IVT efficacy and safety can be confirmed in this indication, given the described significant improvement of VA in 45% of patients when t-PA is administered within 4.5 hours from the onset of symptoms. The width of the therapeutic window of 4.5 hours from the onset of symptoms seems rational, given the entry criteria of the two ongoing randomised trials (THEIA and TENCRAOS). It

is also based on the experimental model of the viability of ischaemia-affected retina and recommended practices for treating ischaemic stroke. However, analysis of the results of the described studies suggests that extending the interval for IVT administration to 6 hours from the onset of symptoms may produce the same effect. However, the number of patients treated 4.5-6 hours from the onset of symptoms is insufficient in the evaluated studies. The results of the ongoing studies are awaited with great anticipation and should be reflected in future recommendations.

Goals for further research should be guided by efforts to expand and individualise the therapeutic time window for IVT administration, e.g. by assessing the retinal ischaemic penumbra on OCT (analogous to the use of CT or MRI perfusion imaging, which allowed IVT administration in selected patients up to 9 hours from the onset of symptoms). It may also be interesting to test the value of sonographic markers (e.g. retrobulbar spot sign) in predicting the success of IVT.

In addition to research activity, sufficient attention should be given among physicians and the public to raise awareness of the need for urgent management of acute CRAO. The goal is to minimise the time loss from the onset of symptoms to IVT administration. It requires the immediate transfer of the patient to the nearest Stroke Centre, where a cooperating ophthalmologist and neurologist will follow an optimally set and trained algorithm.

LITERATURE

- Hayreh SS, Zimmerman MB. Central retinal artery occlusion: Visual outcome. *Am J Ophthalmol*. 2005;140:376-391.
- Feltgen N, Neubauer A, Jurklies B, et al. EAGLE-Study Group. Multicenter study of the European Assessment Group for Lysis in the Eye (EAGLE) for the treatment of central retinal artery occlusion: design issues and implications. *EAGLE Study report no. 1: EAGLE Study report no. 1*. *Graefes Arch Clin Exp Ophthalmol*. 2006 Aug;244(8):950-956.
- Rumelt S, Dorenboim Y, Rehany U. Aggressive systematic treatment for central retinal artery occlusion. *Am J Ophthalmol* 2000 Dec;130:908.
- Park SJ, Choi NK, Seo KH, Park KH, Woo SJ. Nationwide incidence of clinically diagnosed central retinal artery occlusion in Korea, 2008 to 2011. *Ophthalmology*. 2014;121:1933-1938.
- Leavitt JA, Larson TA, Hodge DO, Gullerud RE. The incidence of central retinal artery occlusion in Olmsted county, Minnesota. *Am J Ophthalmol*. 2011;152:820-823.
- Dumitrascu OM, Newman NJ, Biousse V. Thrombolysis for Central Retinal Artery Occlusion in 2020: Time Is Vision! *J Neuroophthalmol*. 2020 Sep;40(3):333-345.
- Schrag M, Youn T, Schindler J, Kirshner H, Greer D. Intravenous fibrinolytic therapy in central retinal artery occlusion: a patient-level meta-analysis. *JAMA Neurol*. 2015;72:1148-1154.
- Sacco RL, Kasner SE, Broderick JP, et al. An updated definition of stroke for the 21st century: a statement for healthcare professionals from the American Heart Association/American Stroke Association. *Stroke*. 2013 Jul;44(7):2064-2089.
- Fraser SG, Adams W. Interventions for acute non-arteritic central retinal artery occlusion. *Cochrane Database Syst Rev*. 2009.
- Flaxel CJ, Adelman RA, Bailey ST, Hyman L, Flaxel CJ, Adelman RA. Retinal and ophthalmic artery occlusions preferred practice pattern(R). *Ophthalmol*. 2020;127:259-287.
- Schumacher M, Schmidt D, Jurklies B, et al. EAGLE-Study Group. Central retinal artery occlusion: local intra-arterial fibrinolysis versus conservative treatment, a multicenter randomized trial. *Ophthalmology*. 2010 Jul;117(7):1367-1375.
- Youn TS, Lavin P, Patrylo M, et al. Current treatment of central retinal artery occlusion: a national survey. *J Neurol*. 2018;265:330-335.
- Powers WJ, Rabinstein AA, Ackerson T, et al. Guidelines for the early management of patients with acute ischemic stroke: 2019 update to the 2018 guidelines for the early management of acute ischemic stroke: a guideline for healthcare professionals from the American Heart Association/American Stroke Association. *Stroke*. 2019;50:344-418.
- Biousse V, Calvetti O, Bruce BB, Newman NJ. Thrombolysis for central retinal artery occlusion. *J Neuroophthalmol*. 2007;27:215-230.
- Kattah JC, Wang DZ, Reddy C. Intravenous recombinant tissue-type plasminogen activator thrombolysis in treatment of central retinal artery occlusion. *Arch Ophthalmol*. 2002;120:1234-1236.
- Hattenbach LO, Kuhl-Hattenbach C, Scharrer I, Baatz H. Intravenous thrombolysis with low-dose recombinant tissue plasminogen activator in central retinal artery occlusion. *Am J Ophthalmol*. 2008;146:700-706.
- Chen CS, Lee AW, Campbell B, et al. Efficacy of intravenous tissue-type plasminogen activator in central retinal artery occlusion: report from a randomized, controlled trial. *Stroke*. 2011;42:2229-2234.
- Nedelmann M, Graef M, Weinand F, et al. Retrobulbar spot sign predicts thrombolytic treatment effects and etiology in central retinal artery occlusion. *Stroke*. 2015;46:2322-2324.
- Préterre C, Godeneche G, Vandamme X, et al. Management of acute central retinal artery occlusion: intravenous thrombolysis is feasible and safe. *Int J Stroke*. 2017;12:720-723.
- Schultheiss M, Hartig F, Spitzer MS, et al. Intravenous thrombolysis in acute central retinal artery occlusion - a prospective interventional case series. *PLoS One*. 2018;13.
- Hou K, Wu W, Liu Y, Qu L, Xu B, Yu J. Role of the ophthalmic artery in the endovascular treatment for intracranial vascular diseases. *Acta Neurol Belg*. 2021 Jan 5.
- Donner GT, Polska E, Garhöfer G, Zawinka C, Frank B, Schmetterer L. Calculation of the diameter of the central retinal artery

- ry from noninvasive measurements in humans. *Curr Eye Res.* 2002;25:341-345.
23. Singh S, Dass R. The central artery of the retina. I. origin and course. *Br J Ophthalmol.* 1960;44:193-212.
24. Mac Grory B, Lavin P, Kirshner H, Schrag M. Thrombolytic therapy for acute central retinal artery occlusion. *Stroke.* 2020;51:687-695.
25. Brown GC, Shields JA. Cilioretinal arteries and retinal arterial occlusion. *Arch Ophthalmol.* 1979;97:84-92.
26. Hayreh SS. The cilio-retinal arteries. *Br J Ophthalmol.* 1963;47:71-89.
27. Hayreh SS, Jonas JB. Optic disk and retinal nerve fiber layer damage after transient central retinal artery occlusion: an experimental study in rhesus monkeys. *Am J Ophthalmol.* 2000;129:786-795.
28. Ma H, Campbell BCV, Parsons MW, et al. Thrombolysis guided by perfusion imaging up to 9 hours after onset of stroke. *N Engl J Med.* 2019;380:1795-1803.
29. Campbell BCV, Ma H, Ringleb PA, et al. EXTEND, ECASS-4, and EPITHET Investigators. Extending thrombolysis to 4.5-9 h and wake-up stroke using perfusion imaging: a systematic review and meta-analysis of individual patient data. *Lancet.* 2019;394:139-147.
30. Nogueira RG, Jadhav AP, Haussen DC, et al. Thrombectomy 6 to 24 hours after stroke with a mismatch between deficit and infarct. *N Engl J Med.* 2018;378:11-21.
31. Albers GW, Marks MP, Kemp S, et al. Thrombectomy for stroke at 6 to 16 hours with selection by perfusion imaging. *N Engl J Med.* 2018;378:708-718.
32. Thomalla G, Simonsen CZ, Boutitie F, et al. MRI-guided thrombolysis for stroke with unknown time of onset. *N Engl J Med.* 2018;379:611-622.
33. Zhao J, Zhao H, Li R, et al. Outcome of multimodal MRI-guided intravenous thrombolysis in patients with stroke with unknown time of onset. *Stroke Vasc Neurol.* 2019;4:3-7.
34. Callizo J, Feltgen N, Pantenburg S, et al. European Assessment Group for Lysis in the Eye. Cardiovascular risk factors in central retinal artery occlusion: results of a prospective and standardized medical examination. *Ophthalmol.* 2015;122:1881-1888.
35. Park SJ, Choi NK, Yang BR, et al. Risk and risk periods for stroke and acute myocardial infarction in patients with central retinal artery occlusion. *Ophthalmology.* 2015;122(11):2336-2343.
36. Lee J, Kim SW, Lee SC, Kwon OW, Kim YD, Byeon SH. Co-occurrence of acute retinal artery occlusion and acute ischemic stroke: diffusion-weighted magnetic resonance imaging study. *Am J Ophthalmol.* 2014;157(6):1231-1238.
37. Hayreh SS, Podhajsky PA, Zimmerman MB. Retinal artery occlusion: associated systemic and ophthalmic abnormalities. *Ophthalmology.* 2009 Oct;116(10):1928-1936.
38. Appen RE, Wray SH, Cogan DG. Central retinal artery occlusion. *Am J Ophthalmol.* 1975 Mar;79(3):374-381.
39. Greven CM, Slusher MM, Weaver RG. Retinal arterial occlusions in young adults. *Am J Ophthalmol.* 1995 Dec;120(6):776-783.
40. Brown GC, Magargal LE, Shields JA, Goldberg RE, Walsh PN. Retinal arterial obstruction in children and young adults. *Ophthalmology.* 1981 Jan;88(1):18-25.
41. Adams HP, Bendixen BH, Kappelle LJ et al. Classification of subtype of acute ischemic stroke. Definitions for use in a multicenter clinical trial. TOAST. Trial of Org 10172 in acute stroke treatment. *Stroke* 1993;24(1): 35-41.
42. Dattilo M, Newman NJ, Biousse V. Acute retinal arterial ischemia. *Ann Eye Sci.* 2018;3:28.
43. Watson T, Shantsila E, Lip GY. Mechanisms of thrombogenesis in atrial fibrillation: Virchow's triad revisited. *Lancet.* 2009 Jan 10;373(9658):155-166.
44. Ertl M, Altmann M, Torka E, et al. The retrobulbar "spot sign" as a discriminator between vasculitic and thrombo-embolic affections of the retinal blood supply. *Ultraschall Med.* 2012 Dec;33(7):263-267.
45. Ochakovski GA, Wenzel DA, Spitzer MS, et al. Retinal oedema in central retinal artery occlusion develops as a function of time. *Acta Ophthalmol.* 2020.
46. Arruga J, Sanders MD. Ophthalmologic findings in 70 patients with evidence of retinal embolism. *Ophthalmology.* 1982;89:1336-1347.
47. Bruno A, Russell PW, Jones WL, Austin JK, Weinstein ES, Steel SR. Concomitants of asymptomatic retinal cholesterol emboli. *Stroke.* 1992;23:900-902.
48. Sharma S, Brown GC, Pater JL, Cruess AF. Does a visible retinal embolus increase the likelihood of hemodynamically significant carotid artery stenosis in patients with acute retinal arterial occlusion? *Arch Ophthalmol.* 1998 Dec;116(12):1602-6.
49. Hayreh SS. Neovascular glaucoma. *Prog Retin Eye Res.* 2007 Sep;26(5):470-485.
50. Rudkin AK, Lee AW, Chen CS. Ocular neovascularization following central retinal artery occlusion: prevalence and timing of onset. *Eu J Ophthalmol.* 2010;20:1042-1046.
51. Rossmann H. The thrombolytic therapy of vascular occlusions of the retina [in German]. *Klin Monbl Augenheilkd.* 1966;149(6):874-880.
52. Wang X, Liu Y, Suo Y, et al. Intravenous Recombinant Tissue-Type Plasminogen Activator Thrombolysis for Acute Central Retinal Artery Occlusion. *J Craniofac Surg.* 2021 Jan-Feb 01;32(1):313-316.
53. Wu XJ, Gao F, Liu X, Zhao Q. Observation on therapeutic efficacy of rt-PA intravenous thrombolysis combined with compound anisodine injection on central retinal artery occlusion. *Exp Ther Med.* 2016;12(4):2617-2621.
54. Hacke W, Kaste M, Bluhmki E, et al. ECASS Investigators. Thrombolysis with alteplase 3 to 4.5 hours after acute ischemic stroke. *N Engl J Med.* 2008 Sep 25;359(13):1317-1329.
55. Abel AS, Suresh S, Hussein HM, Carpenter AF, Montezuma SR, Lee MS. Practice patterns after acute embolic retinal artery occlusion. *Asia Pac J Ophthalmol (Phila).* 2017;6:37-39.