

CLINICAL RESULTS OF IMPLANTATION OF TWO TYPES OF MULTIFOCAL ROTATIONALLY – ASYMMETRIC INTRAOCULAR LENSES

SUMMARY

CLINICAL RESULTS OF THE IMPLANTATION OF TWO TYPES OF MULTIFOCAL ROTATIONAL ASYMMETRIC INTRAOCULAR LENSES

Purpose: The aim of the study was evaluation and comparison of clinical results of two types of rotationally asymmetric multifocal intraocular lens (LENTIS Mplus and LENTIS MplusX).

Material and methods: The study included 247 eyes of 124 patients aged 25 - 76 years (mean, 58 years). After phacoemulsification multifocal intraocular lens LENTIS Mplus (group A, n = 141) or LENTIS MplusX (group B, n = 106) was implanted. Patients were divided into two groups according to the type of intraocular lens. Patients were evaluated at 1 month, 3 months and 6 months after surgery. We assessed the uncorrected visual acuity, best corrected visual acuity, subjective refraction, contrast sensitivity and subjective satisfaction.

Results: Mean preoperative monocular uncorrected distance visual acuity (UCDVA) in the group A was $0,40 \pm 0,27$; in the group B $0,34 \pm 0,25$. Postoperatively UCDVA was statistically significant improved in both groups (group A: $1,01 \pm 0,20$; group B: $0,90 \pm 0,15$). Mean preoperative monocular uncorrected near visual acuity (UCNVA) was Jaeger (J) $12,82 \pm 4,16$ (group A), resp. J $12,73 \pm 3,99$ (group B). Postoperatively UCNVA was statistically significant improved in both groups (group A: J $1,81 \pm 1,42$; group B: J $1,54 \pm 1,72$). There was not found statistically significant difference between both groups in these parameters. Contrast sensitivity was evaluated in patients who have undergone clear lens extraction in both eyes. There was not found the statistically significant reduction of contrast sensitivity in both groups. Subjective satisfaction was assessed in the range of marks 1-5. The average mark of the subjective satisfaction ratings in the group A was 1,37; in the group B 1,25.

Conclusion: Our study found the multifocal intraocular lens LENTIS Mplus and LENTIS MplusX give high-quality distance and near vision and provide high degree of spectacle independence. There was not found statistically significant difference in all parameters between the Group A (implantation Mplus LENTIS) and the Group B (implantation LENTIS MplusX) in our study. However, in our study we have observed higher subjective satisfaction and lower incidence of optical phenomena in the Group of patients with the implantation of intraocular lens LENTIS MplusX.

Key words: LENTIS Mplus, LENTIS MplusX, visual acuity, contrast sensitivity, optical phenomena

Čes. a slov. Oftal., 73, 2017, No. 1, p. 3-12

INTRODUCTION

The dramatic progress in refractive surgery over the last twenty years has enabled us to achieve ever greater successes in meeting the main target of this field, which is complete postoperative independence of correction by eyeglasses. At present, phacoemulsification and implantation of a multifocal intraocular lens is the most frequent method of solution. The main attention is concentrated on the development of such a design of a multifocal intraocular lens, which after implantation will provide a full scope of visual acuity without reducing contrast sensitivity and adverse secondary optical phenomena with a minimal risk of all complications during surgery and also in the long-term perspective after surgery. At present, the

fulfilment of these conditions still remains a challenge for the field of the technology of developing multifocal lenses. A significant advance in this field was achieved with the arrival of a new technology with a rotationally asymmetric surface of the optical part of the intraocular lens. This shape of the optical part was developed with the aim of inhibiting the occurrence of secondary optical phenomena, which we are familiar with in connection with the implantation of other types of multifocal intraocular lenses, whilst at the same time preserving the depth of visual acuity. The multifocal intraocular lens LENTIS Mplus (Oculentis GmbH and Topcon Europe BV) is currently available in a wide range of various types, with various additions for near vision. The design of this multifocal lens is also undergoing continuous development.

¹Velická V., ²Hejsek L., ³Raiskup F.

¹Department of Ophthalmology, Faculty of Medicine, Charles University and University Hospital Hradec Králové
Head: prof. MUDr. Naďa Jirásková, Ph.D., FEBO

²Department of Ophthalmology, Faculty of Medicine, Charles University and University Hospital Hradec Králové,
Head: prof. MUDr. Pavel Rozsival, CSc., FEBO

³Klinik für Augenheilkunde, Universitätsklinikum C. G. Carus, Dresden

The authors of the study declare that no conflict of interest exists in the compilation, theme and subsequent publication of this professional communication, and that it is not supported by any pharmaceuticals company.



MUDr. Věra Velická
Oční klinika LFUK a FN
Sokolská 581
500 05 Hradec Králové
e-mail: vera.velicka@fnhk.cz

The shape of the multifocal intraocular lens LENTIS Mplus is based on patented asymmetric aspherical refractive technology, with a smooth transition between the zone for distance and near vision. The functional structure of this intraocular lens combines two spherical surfaces with various radii on the anterior part of the optics – the main surface and the inserted surface. The centres of both spherical surfaces and both focal points of the lens lie on a common axis. The posterior part of the optics has a biconvex aspherical surface. In its result, this technology reduces the source of light dispersion and the incidence of aberrations, and minimises the decrease in contrast sensitivity. In the case of the need to address corneal astigmatism, we have a toric variant of this intraocular lens available, with precision of calculation to 0.01 dioptres. The posterior part of the optics and haptics has a square edge within a scope of 360°, which provides a barrier effect for diffusing the opacities of the posterior capsule. The four point “plate haptics” ensures excellent rotational stability of the intraocular lens within the lens sac. HydroSmart® material is a hydrophilic acrylate with a hydrophobic surface, with absorption of ultraviolet light.

Since January 2014 a new generation of LENTIS Mplus intraocular lenses has been available, under the brand name of LENTIS MplusX. With the introduction of this new range of intraocular lenses, the manufacturer, by changing the shape of the optical part, is attempting to attain better depth of visual acuity, with balanced vision at all distances (“APA” - Additive paraxial asphericity technology), and greater independence of the quality and quantity of vision from the width of the pupil thanks to reduction of the central diameter (“SDO” - Surface design optimisation technology). The improvement in the shape of this intraocular lens should therefore bring a further significant reduction of secondary optical phenomena by means of the homogeneous peripheral transition zone, with an expansion of the segment for near vision and also an attendant increase in quality of vision precisely at this distance. The first clinical results were published in 2014 by the team of authors Berrow et al. (1).

Our aim was to evaluate and compare the clinical results of implantation of two types of this multifocal rotationally asymmetric intraocular lens with the same value of addition for near vision (+3 dioptres), namely LENTIS Mplus and the innovative LENTIS MplusX.

COHORT AND METHODOLOGY

The study included patients who had undergone phacoemulsification with implantation of an intraocular lens of the type LENTIS Mplus (LS-313 MF30), LENTIS Mplus toric (LU-313 MF30T), LENTIS MplusX (LS-313 MF30) or LENTIS MplusX toric (LU-313 MF30T) at the Department of Ophthalmology of the University Hospital in Hradec Králové in the period from July 2012 to April 2015. The cohort included 247 eyes of 124 patients (69 women and 55 men). The average age of the patients was 58 years (25 – 76 years). This cohort was divided into two groups. Group A included patients with implantation of an intraocular lens LENTIS Mplus, or LENTIS Mplus toric (period of implantation from July 2012 to December 2013).

Group B included patients with implantation of an intraocular lens LENTIS MplusX, or LENTIS MplusX toric (all the patients who underwent implantation from January 2014 to April 2015). The patients were examined 1 month, 3 months and 6 months after surgery. We always implanted the same type of intraocular lens bilaterally. The preoperative data is presented in table 1.

We implanted the toric variant of the intraocular lens in patients with regular corneal astigmatism in a value of 0.75D and more (astigmatism slanted and against the rule), and 1D and more (astigmatism with the rule). Before surgery each patient conducted an interview with a doctor, who determined the patient's main motivation for the operation, as well as his/her expectations. Each patient was familiarised with the advantages (independence of correction by eyeglasses) and disadvantages (reduction of contrast sensitivity under impaired lighting conditions, incidence of secondary optical phenomena) of the implantation of multifocal intraocular lenses. Each patient was familiarised with the fact that even after surgery, the necessity for additional correction by eyeglasses may ensue.

The exclusion criteria for the implantation of a multifocal intraocular lens covered the following: retinal pathology (disease of the macula, diabetic retinopathy, condition following retinal detachment), pathology of the optic nerve and cornea (irregular astigmatism, endothelial dystrophy), dry eye syndrome, loose suspensory apparatus of the lens, uveitis, glaucoma and post-traumatic condition of the eye. Our cohort did not include any patient following a prior laser corneal refractive procedure. Pupil width was not considered an exclusion criterion. Patients with highly unrealistic expectations and patients who did not accept the possibility of occurrence of secondary optical phenomena following implantation of a multifocal intraocular lens were excluded from indication. Informed consent was obtained from each patient.

All the patients underwent a preoperative examination, which included the following: taking of anamnesis, examination of uncorrected and best corrected visual acuity in distance and near vision, determination of dominant eye, measurement of intraocular pressure (non-contact tonometer NIDEK NT-530), examination of refraction (auto refractometer NIDEK AR 310A), performance of biometry (IOLMaster, Carl Zeiss Meditec AG), corneal topography (Pentacam, Oculus, Inc.) and contrast sensitivity (CSV-1000, Vectorvision). The examination concluded with an examination of the ocular fundus, and in the case of absence of foveolar reflection also an OCT examination of the macula (CIRRUS HD-OCT, Zeiss). If implantation of a toric variant of the multifocal intraocular lens was planned, we performed digital photography of the anterior segment of the eye on a slit lamp, with application of a program for localisation of the limbal blood vessels.

We performed calculations of the toric intraocular lens according to a calculator available on the internet (<http://www.lentistoric.com>). For calculation of the dioptric strength of the implanted intraocular lens we used the formula Haigis or Hoffer Q. All eyes were planned for emmetropia. All the operations were performed by 1 surgeon (P.R.), using the same surgical technique of phacoemulsification. The intraocular

Table 1 Preoperative data

PARAMETER	Group A (n = 71)	Group B (n = 53)
Average age Mean \pm SD Range	57 \pm 8 (35 - 74 years)	59 \pm 9 (25 - 76 years)
Male/Female (n)	34/37	21/32
Number of eyes	141	106
Refractive lensectomy implantation (number of eyes)	104	68
Cataract surgery (number of eyes)	37	38
Toric intraocular lens implantation (number of eyes)	53	38
Axial length (mm) Mean \pm SD Range	23,07 \pm 0,89 21,2 to 26,57	22,87 \pm 1,16 20,02 to 25,9
Keratometry (diopter) Mean \pm SD Range	43,48 \pm 1,34 39,69 to 47,57	43,39 \pm 1,39 40,64 to 46,5
Corneal astigmatism (diopter) Mean \pm SD Range	-0,85 \pm 0,54 0,00 to -3,40	-1,05 \pm 0,74 0,00 to -3,21
Spherical IOL power (diopter) Mean \pm SD Range	21,96 \pm 2,82 11,20 to 30,0	22,68 \pm 3,4 14,5 to 32,57

Explanatory notes: n - number of patients, mm - millimeter, SD - standard deviation

lens was implanted by means of a corneal incision with a size of 2.4 mm. The operation on the second eye was performed always on the following day. Postoperatively we observed uncorrected visual acuity (UCVA) for distance and near vision, best corrected visual acuity (BCVA) for distance and near vision, subjective refraction and contrast sensitivity. Subjective satisfaction was evaluated on a scale of 1 (maximum satisfaction) to 5 (total dissatisfaction).

All the measured values were statistically processed. In the parameters of UCVA for distance and near vision, as well as for contrast sensitivity, the values of the differences in the individual times of measurement were compared between the lenses LENTIS Mplus and Lentis MplusX. The parameters do not have a normal division, because non-parametric methods were used for testing. For the testing of more than 2 repeated measurements, a Friedman test for 4 dependent selections was used, with a Dunn's test for multiple testing between couples of selections, for testing between two dependent selections a Wilcoxon test and for testing between two independent selections a Mann-Whitney test was used. The results were evaluated on a level of significance of 0.05.

RESULTS

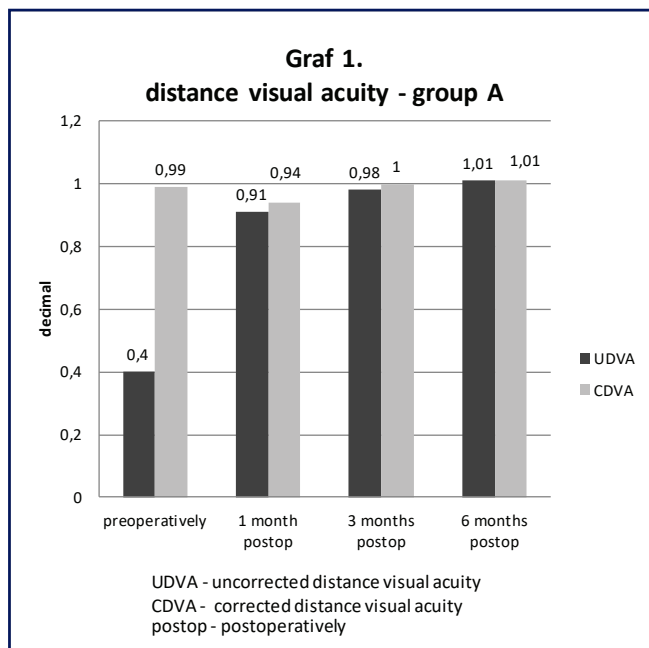
We evaluated monocular uncorrected and best corrected visual acuity for distance and near vision. In all the parameters, in a comparison of the values before surgery and at the end of the observation period, a statistically significant improvement was achieved. The average value of preoperative monocular UCVA (decimal values) for distance vision in group A was 0.40 ± 0.27 (range from 0.02 to 1.2), and in group B

0.34 ± 0.25 (range from 0.02 to 1.0). At the end of the observation period, i.e. 6 months after surgery, we recorded a statistically significant improvement of monocular UCVA in both groups for distance vision (group A: 1.01 ± 0.20 ; range from 0.4 to 1.5; group B: 0.90 ± 0.15 ; range from 0.4 to 1.2). In a comparison of the differences in monocular UCVA for distance vision between group A and group B at the individual times of measurement (preoperatively – 1 month after surgery, preoperatively – 3 months after surgery, preoperatively – 6 months after surgery, 1 month after surgery – 3 months after surgery, 1 month after surgery – 6 months after surgery, 3 months after surgery – 6 months after surgery), no statistically significant difference was determined on the selected level of significance of 0.05.

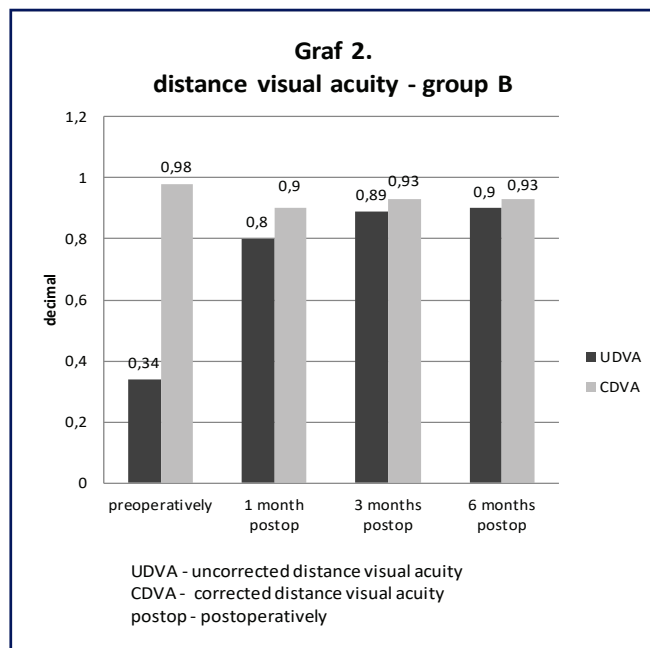
A comparison of monocular uncorrected and best corrected visual acuity for distance vision before and after surgery is presented in graphs 1 and 2.

The average value of preoperative monocular UCVA for near vision in group A was Jaeger (J.) no. 12.82 ± 4.16 ; in group B J. no. 12.73 ± 3.99 . At the end of the observation period we observed a statistically significant improvement in monocular UCVA for near vision in both groups (group A: J. no. 1.81 ± 1.42 ; group B: J. no. 1.54 ± 1.72). In a comparison of the values of the differences in monocular UCVA for near vision between groups A and B at the individual times of measurement, no statistically significant difference was determined on the selected level of significance of 0.05. A comparison of monocular uncorrected and best correction visual acuity for near vision before and after surgery is presented in graphs 3 and 4.

The average preoperative value of subjective refraction for



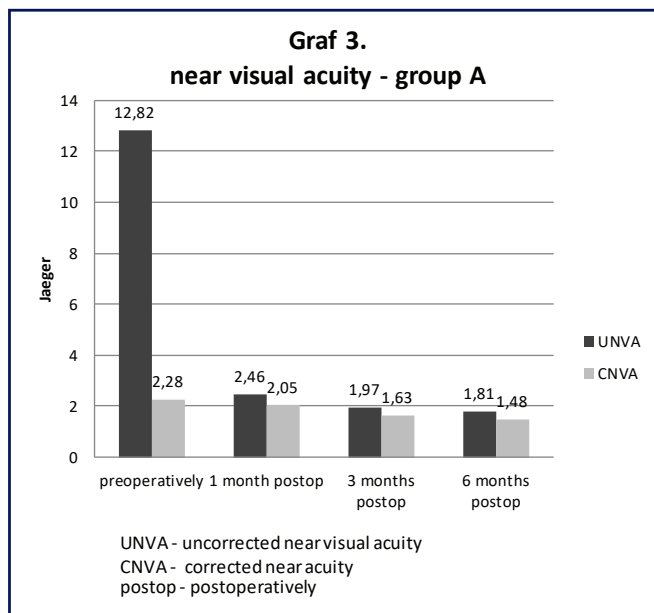
Graph 1 Mean values of uncorrected and corrected distance visual acuity in the group A (LENTIS Mplus) preoperatively, 1 month, 3 months and 6 months postoperatively



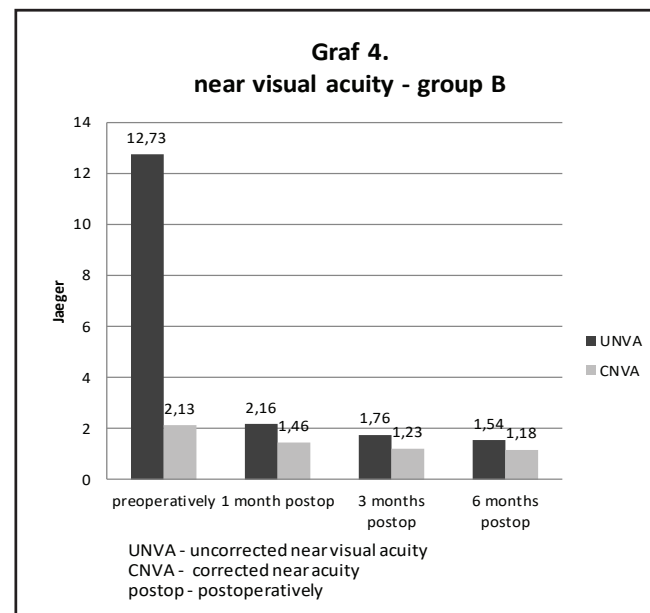
Graph 2 Mean values of uncorrected and corrected distance visual acuity in the group B (LENTIS MplusX) preoperatively, 1 month, 3 months and 6 months postoperatively

distance vision in group A was $+1.46 \pm 1.87$ Dsf (range from -5.75 to +6.0) and -0.48 ± 0.59 Dcyl (range from -4.0 to 0.0), in group B $+2.13 \pm 2.13$ Dsf (range from -3.5 to +8.0) and -0.71 ± 0.88 Dcyl (range from -4.5 to 0.0). At the end of the observa-

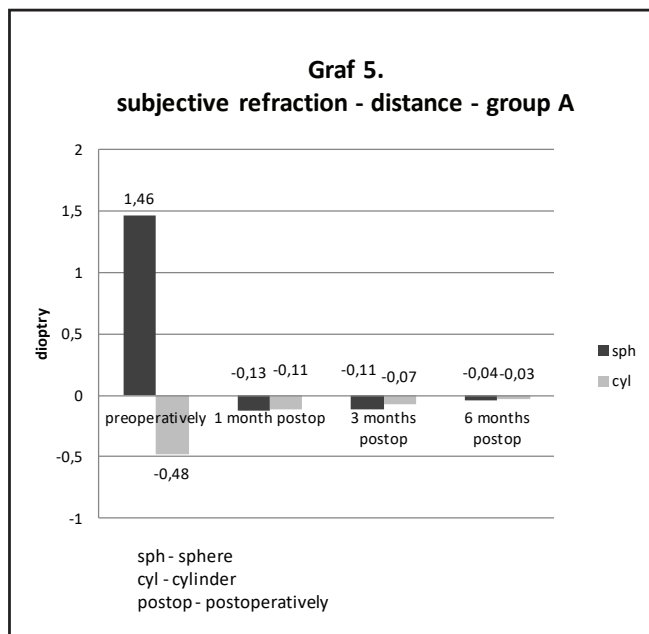
tion period we determined a statistically significant reduction in the values in both groups. A comparison of preoperative subjective refraction for distance vision in both groups is presented in graphs 5 and 6.



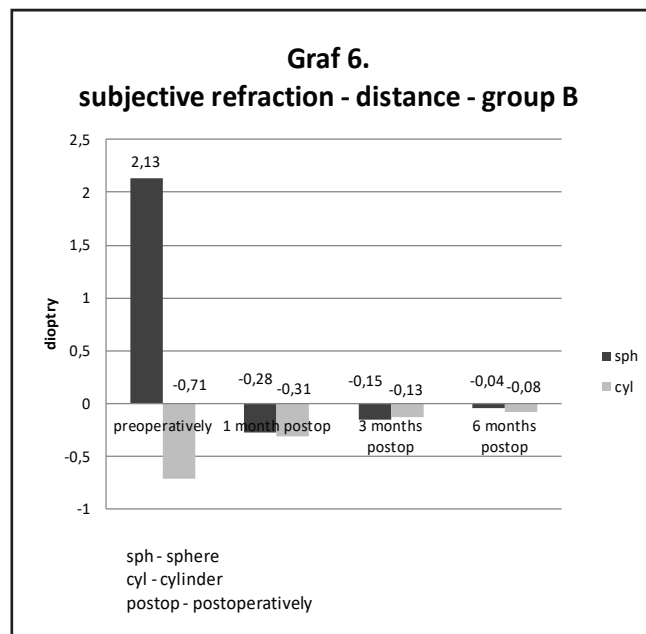
Graph 3 Mean values of uncorrected and corrected near visual acuity in the group A (LENTIS Mplus) preoperatively, 1 month, 3 months and 6 months postoperatively



Graph 4 Mean values of uncorrected and corrected near visual acuity in the group B (LENTIS MplusX) preoperatively, 1 month, 3 months and 6 months postoperatively



Graph 5 Mean values of subjective refraction (distance) in the group A (LENTIS Mplus) preoperatively, 1 month, 3 months and 6 months postoperatively

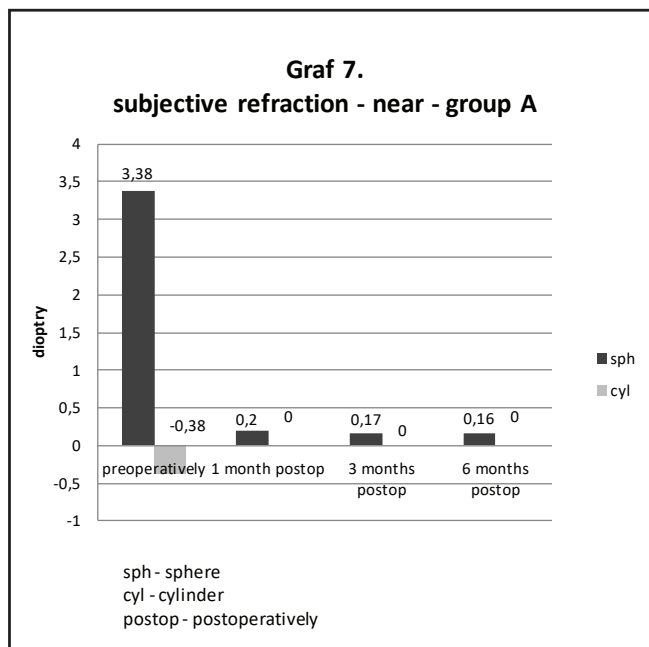


Graph 6 Mean values of subjective refraction (distance) in the group B (LENTIS MplusX) preoperatively, 1 month, 3 months and 6 months postoperatively

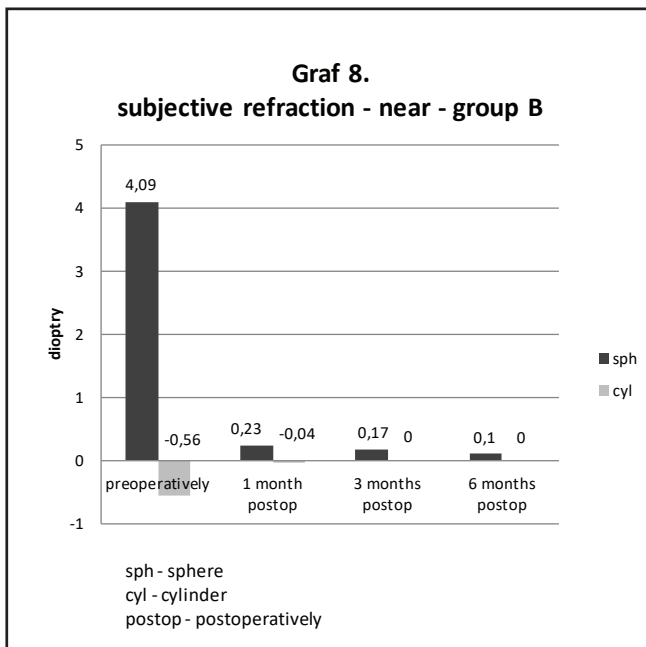
The average preoperative value of subjective refraction for near vision in group A was $+3.38 \pm 1.77$ Dsf (range from -2.00 to + 7.75) and -0.38 ± 0.59 Dcyl (range from -4.0 to 0,0), in group B $+4.09 \pm 2.05$ Dsf (range from + 9.00 to 0) and -0.56 ± 0.84 Dcyl (range from -4.5 to 0,0). At the end of the observa-

tion period we determined a statistically significant reduction in the values of subjective refraction for near vision in both groups. A comparison of preoperative subjective refraction for near vision in both groups is presented in graphs 7 and 8.

We evaluated contrast sensitivity only in patients who had



Graph 7 Mean values of subjective refraction (near) in the group A (LENTIS Mplus) preoperatively, 1 month, 3 months and 6 months postoperatively



Graph 8 Mean values of subjective refraction (near) in the group B (LENTIS MplusX) preoperatively, 1 month, 3 months and 6 months postoperatively

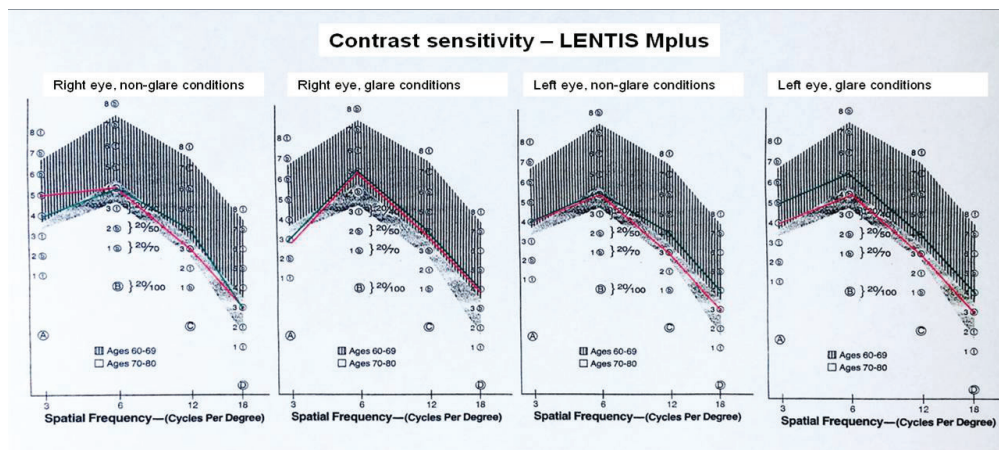


Fig. 1 Contrast sensitivity values in group A (implantation LENTIS Mplus)

explanations: green: the mean preoperative values, red: average values 6 months after surgery, hatched: the normal range for age 60-69 years, dotted: the normal range for age 70-80 years, Cycles per degree = number of cycles per degree

undergone bilateral replacement of the lens within the framework of refractive lensectomy. Contrast sensitivity was examined monocularly, with and without dazzling, preoperatively and 6 months after surgery, separately for each right and left eye. In our study we reached an important finding – the processing of the results did not demonstrate a statistically significant reduction of contrast sensitivity in either of the groups. Due to the lack of any change in contrast sensitivity before and after surgery on the right and left eye, it was not possible to demonstrate a statistically significant difference on the selected level of significance of 0.05 between groups A and B (Mann-Whitney test). The development of contrast sensitivity in both groups is illustrated by fig. 1 and 2. The graphically expressed values are rounded up to whole numbers.

The evaluation of subjective satisfaction was based on an

evaluation conducted at our centre (2), with the aim of developing this evaluation on a rating scale of 1-5 with precise determination of spontaneous subjective complaints causing any worse evaluations. After surgery the doctor always asked whether the patient was satisfied and had no complaints. In the case of a positive answer we did not actively attempt to determine the presence of any adverse effects. In the case of presence of complaints, we recorded the spontaneously stated complaints. We chose the aforementioned procedure for all our patients following implantation of multifocal intraocular lenses for the purpose of maximum suppression of attention to secondary optical phenomena with the aim of ensuring the fastest possible neuroadaptation. The average score in the evaluation of subjective satisfaction in group A was 1.37; in group B 1.25. In group A (implantation of LENTIS Mplus),

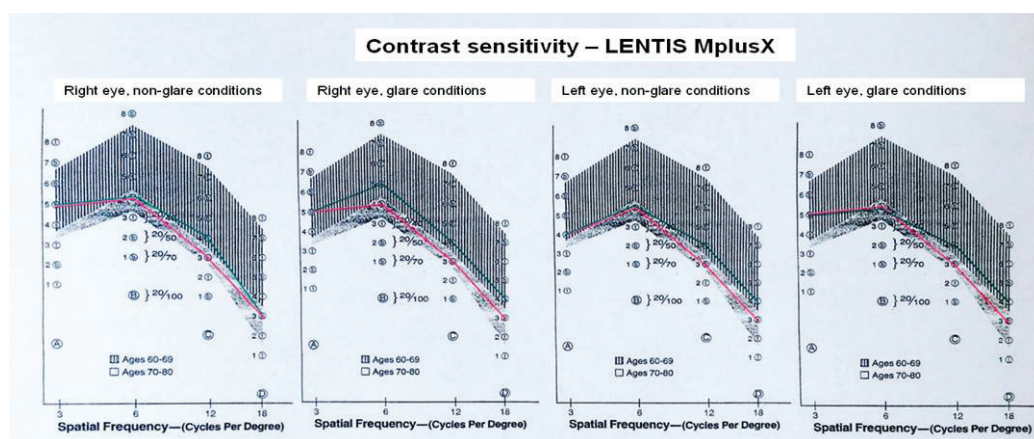


Fig. 2 Contrast sensitivity values in group A (implantation LENTIS MplusX)

explanations: green: the mean preoperative values, red: average values 6 months after surgery, hatched: the normal range for age 60-69 years, dotted: the normal range for age 70-80 years, Cycles per degree = number of cycles per degree

Table 2 Satisfaction ratings - 6 months after surgery

Grade	Group A (n=71)	Group B (n=53)
1 = satisfied without complaints	50 (70,4%)	41 (77,4%)
2 = satisfied with minor complaints that doesn't cause any inconvenience	16 (22,6%)	11 (20,8%)
3 = dissatisfied due to bothering symptoms	5 (7,0%)	1 (1,8%)
4 = dissatisfied, unacceptable problems or inconvenience	0	0
5 = dissatisfaction resulting in IOL explantation	0	0

Notes: n = number of patients

Table 3 Type and frequency of spontaneous subjective complaints

The type of spontaneous subjective complaints	Group A (n = 71)	Group B (n = 53)
	number of patients	
Decrease in distance vision	3	5
Decrease in near vision	4	0
Disturbing optical phenomenon, glare or glare while driving at night	6	3
"Ghosts" around letters	4	1
Deterioration of vision at dusk	1	0
Color shift towards purple hue	1	0
Dry eye after the surgery, discomfort mimicking a chronic inflammation	2	2
Total	21	12

Notes: n = number of patients

Table 4 Rate of types of spontaneous subjective complaints in classification

The type of spontaneous subjective complaints	Group A (n = 71)		Group B (n = 53)	
	Mark 2	Mark 3	Mark 2	Mark 3
	number of patients			
Decrease in distance vision	3	0	4	1
Decrease in near vision	2	2	0	0
Disturbing optical phenomenon, glare or glare while driving at night	4	2	3	0
"Ghosts" around letters	2	2	1	0
Deterioration of vision at dusk	1	0	0	0
Color shift towards purple hue	1	0	0	0
Dry eye after the surgery, discomfort mimicking a chronic inflammation	2	0	2	0

Notes: n = number of patients

an evaluation of subjective satisfaction with a mark of 3 (highest ranked value, dissatisfied) was due in equal measure to the incidence of secondary optical phenomena (2 patients), "ghosts" around letters when reading close up (2 patients) and generally worsened near vision (2 patients). In group B (implantation of LENTIS Mplus X) 1 patient was dissatisfied (score of 3), in whom a refractive surprise occurred with a myopic shift in the right eye, which required subsequent ad-

ditional laser correction. In one case we determined a change in colour perception following surgery, probably due to the influence of chromatic aberration. This was in a 62 year old female patient who had undergone refractive lensectomy with implantation of LENTIS Mplus (OP +18.5D, OL +18D). A detailed overview of subjective satisfaction is illustrated by tables 2, 3 and 4.

DISCUSSION

The main objective of surgical correction of presbyopia is distance and near vision without dependency on correction by eyeglasses. Implantation of the multifocal intraocular lens LENTIS Mplus within the framework of cataract surgery or refractive lensectomy provides excellent results, which are confirmed also by contemporary studies (3, 4). In our cohort we conducted a comparison of two types of this multifocal intraocular lens with an addition of +3 dioptres for near vision (LENTIS Mplus and LENTIS MplusX), focusing on any applicable change in contrast sensitivity and the presence of subjective complaints caused by the influence of secondary optical phenomena.

One of the fundamental quality criteria of intraocular lenses is the high rate of predictability of the refractive result following implantation. In 4 eyes of 3 patients (1.62%) we recorded a myopic shift (range from -2.5D to -3.5D). All the patients concerned were women with preoperative hypermetropia (range +2D to +5.5D). In three cases it concerned implantation of a LENTIS Mplus lens, in one patient implantation of a LENTIS MplusX lens. We resolved the condition by performing additional laser correction by the method of photorefractive keratectomy.

Refractive surprise is always a feared complication in the case of implantation of a multifocal intraocular lens. It is very important to ensure a precise calculation of the dioptric power of the intraocular lens. In our cohort we used the Haigis formula for calculation of the power of the implanted intraocular lens. In eyes with an axial length of less than 22 mm we gave priority to the Hoffer Q formula. In the case of presence of corneal astigmatism we used the possibility of implantation of the toric variant of this intraocular lens. In all the patients the initial incision was made in the place of 90 degrees, and in the case of implantation of the toric variant we selected surgically induced astigmatism (SIA) in a value of 0.50 D. The same procedure is stated also by Venter et al. (5). At present, on the basis of this finding, we furthermore perform measurement of the WTW value (white to white, distance from limbus to limbus (IOLMaster, Carl Zeiss Meditec AG)) in all eyes. The reason for this is the theoretical assumption of the possibility of a greater risk of front-to-back shift of the centre of the optics of this intraocular lens with plate haptics with a total diameter of 11.0 mm in the case of greater scarring of the capsule following surgery in eyes with a low WTW value.

We implanted the toric variant of this multifocal intraocular lens in a total of 92 eyes. We performed the precise placing of the IOL axis not only on the basis of preoperative manual marking on the cornea with the aid of a marker and photography of the anterior segment of the eye with application of a program for localisation of limbal blood vessels. At present we use a navigation system, which not only reduces the invasiveness of the operation (absence of manual marking), but also simultaneously enables visualisation of the axis of placement and precise centration of the intraocular lens during surgery.

Postoperatively, in the period up to 1 month after surgery, a pseudophakic cystoid macular edema (CME) occurred in 5 eyes of 3 patients. These were patients after cataract surgery with implantation of an intraocular lens of the type LENTIS Mplus. Two patients suffered from high blood pressure. All the patients underwent conservative local therapy of CME, in two eyes we applied triamcinolone (4 mg) intravitreally, which in one patient led to an elevation of intraocular pressure with the subsequent necessity to apply temporary anti-glaucomatous medication. These patients still remain under our observation, without the necessity of further treatment. The values of uncorrected visual acuity in the individual patients at the present time are as follows: patient no. 1 (bilateral CME): vision in right eye (VRE) 0.6; vision in left eye (VLE) 0.9; patient no. 2 (bilateral CME): VRE 0.6; VLE 0.7; patient no. 3 (CME in right eye): VRE 0.5; VLE 1.0. In all eyes there was a progressive normalisation of the thickness of the retinal layers. We resolved the incidence of opacification of the posterior capsule, reducing subjective visual acuity always by performing Nd:YAG capsulotomy. We performed the procedure up to 6 months after surgery in a total of 11 eyes (4.5%). In group A we performed Nd:YAG capsulotomy in 9 eyes of 4 patients, in group B in 2 eyes of 2 patients. A low percentage of incidence of opacification of the posterior capsule following implantation of a LENTIS Mplus intraocular lens is also described by Venter et al. (6). One patient from the cohort underwent unilateral implantation. This was a young man (39 years) with a cataract without an anamnesis of trauma or other general pathology. The patient is satisfied and without complaints. An enumeration of postoperative complications is presented in table 5.

Subjective patient satisfaction following the implantation of a multifocal intraocular lens may, even in the case of an excellent refractive result, negatively influence the

Table 5 Postoperative complications

Postoperative complications	Group A (n = 141)	Group B (n = 106)
	number of eyes	
Pseudophakic macular edema	5	0
Refractive surprise	3	1
YAG capsulotomy	9	2
Photorefractive keratectomy	3	1

Notes: n = number of patients

incidence of secondary optical phenomena or the reduction of contrast sensitivity under worsened lighting conditions. Before surgery all the patients were carefully familiarised in detail with the incidence of these phenomena. We recorded a lower incidence of complaints and higher satisfaction after implantation in group B (LENTIS MplusX). The improvement of the shape of this intraocular lens by means of a homogeneous peripheral transition zone in our cohort is therefore confirmed by the further reduction of the incidence of secondary optical phenomena and therefore also of subjective complaints. None of the patients in our cohort had spontaneous subjective complaints with middle distance vision. Excellent results of middle distance vision following the implantation of this rotationally asymmetrical intraocular lens are confirmed also by further studies (7).

Thanks to the shape of the optical part, the multifocal intraocular lens LENTIS Mplus records a minimal reduction in contrast sensitivity. Alio et al. (8) in their study compared contrast sensitivity following implantation of a monofocal intraocular lens and a LENTIS Mplus multifocal intraocular lens (LS-312 MF30 IOL). Their results did not confirm a difference in contrast sensitivity under scotopic and mesopic conditions between these two types of intraocular lenses. In our study we evaluated contrast sensitivity only in patients who had undergone a lens replacement within the framework of refractive lensectomy in both eyes. We did not demonstrate any statistically significant reduction in contrast sensitivity in either type of this intraocular lens. Furthermore, no statistically significant difference was determined in a comparison of both types against one another (Mann-Whitney test).

The incidence of disruptive secondary optical phenomena following the implantation of multifocal intraocular lenses always plays a highly significant role in the subjective evaluation of the result of the operation by the patient. These phenomena may have a disruptive effect, and the perception of them is highly individual. Cases are described in the literature in which the influence of secondary optical phenomena after surgery were so disruptive for the patient that they caused a substantial reduction in quality of life, with the result that the only solution was explantation of the multifocal intraocular lens (9). It is known that explantation of an artificial intraocular lens always involves a high risk of perioperative or postoperative complications, the perception of which in the group of "refractive patients" is multiplied by the high degree

of expectations of the best postoperative result. No examination methods exist for determining patients' capacity for adaptation to the incidence of secondary optical phenomena following the implantation of multifocal intraocular lenses, and for the ophthalmologist it is practically impossible to estimate the precise degree of the capacity for neuroadaptation for the individual patient. The prevention of these complications depends not only on the experience of the indicating doctor, the skill of the surgeon and the degree to which the patient has been instructed, but also the type of multifocal intraocular lens. In our observation we recorded a lower incidence of secondary optical phenomena in both types of this multifocal intraocular lens. In a comparison of both groups we determined a lower incidence of secondary optical phenomena in the group of patients with implantation of a LENTIS MplusX intraocular lens.

CONCLUSION

The multifocal intraocular lenses LENTIS Mplus and LENTIS MplusX provide quality distance and near vision, and thus enable independence of correction by eyeglasses. The excellent refractive results also confirm the high degree of reliability and predictability in patients with significant corneal astigmatism.

In a comparison of the differences in the values of visual acuity and subjective refraction at the individual intervals between both types of intraocular lenses, no significant difference was determined. Following the implantation of both types of this intraocular lens within the framework of refractive lensectomy, there was no statistically significant reduction in contrast sensitivity. Within the framework of evaluation of the objective parameters, we also found no statistically significant difference between the two types of multifocal intraocular lens. In an evaluation of subjective satisfaction we determined a lower incidence of secondary optical phenomena and spontaneous subjective complaints in the group with implantation of a LENTIS MplusX intraocular lens.

The occurrence and subjective perception of secondary, adverse optical phenomena following the implantation of multifocal intraocular lenses is currently the subject of considerable observation. The minimisation of these adverse accompanying physical phenomena, the complete suppression of their occurrence and manifestation, or their utilisation, represents a challenge and a goal within the area of the development of intraocular lenses.

LITERATURE

1. **Berrow, EJ., Wolffsohn, JS., Bilkhu, PS., Dhallu, S.:** Visual performance of a new bi-aspheric, segmented, asymmetric multifocal IOL. *J Refract Surg*, 2014; 30(9): 584–8.
2. **Urminský J., Rozsival P., Feuermanová A., Lorencová V., Jirásková N.:** Implantace multifokální nitrooční čočky. *Čes a slov Oftal*, 2004, No. 1, 30–36.
3. **Alió, JL., Plaza-Puche, AB., Javaloy, J., Ayala, MJ., Vega-Estrada, A.:** Clinical and optical intraocular performance of rotationally asymmet-
4. **Venter, JA., Pelouskova, M., Collins, BM., Schallhorn, SC., Hannan, SJ.:** Visual outcomes and patient satisfaction in 9366 eyes using a refractive multifocal IOL plate-haptic design versus C-loop haptic design. *J Refract Surg*, 2013; 29(4): 252–9.

- ve segmented multifocal intraocular lens. *J Cataract Refract Surg*, 2013; 39(10): 1477–84.
5. **Venter , J., Pelouskova M.:** Outcomes and complications of a multifocal toric intraocular lens with a surface-embedded near section. *J Cataract Refract Surg*, 2013 Jun; 39(6): 859–66.
 6. **Venter, JA., Pelouskova, M., Bull, CE., Schallhorn, SC., Hannan, SJ.:** Visual outcomes and patient satisfaction with a rotational asymmetric refractive intraocular lens for emmetropic presbyopia. *J Cataract Refract Surg*, 2015; 41(3): 585-93.
 7. **Alio, JL., Plaza-Puche, AB., Pinero, DP., Javaloy, J., Ayala, MJ.:** Comparative analysis of the clinical outcomes with 2 multifocal intraocular lens models with rotational asymmetry. *J Refract Surg*, 2011; 37: 1605–1614.
 8. **Alio, JL., Pinero, DP., Plaza-Puche, AB.,**
 - Rodrigues Chan, MJ.:** Visual outcomes and optical performance of a monofocal intraocular lens and a new-generation multifocal intraocular lens. *J Refract Surg*, 2011; 37: 241–250.
 9. **Kamiya, K., Hayashi, K., Shimizu, K., Negishi, K., Sato, M., Bissen-Miyajima, H.:** Multifocal intraocular lens explantation: a case series of 50 eyes. *Am J Ophthalmol*, 2014; 158(2): 215–220.