

# Reconstruction of the Anophthalmic Conjunctival Sac. A Review of Surgical Procedures to Achieve Stability of the Ocular Prosthesis in Our Practice

Ilavská Monika<sup>1</sup>, Kubíková Eliška<sup>2</sup>, Majtánová Nora<sup>3</sup>

<sup>1</sup>Medilux – eye centre, Galanta, Slovakia

<sup>2</sup>Institute of Anatomy, Medical Faculty, Comenius University, Bratislava, Slovakia

<sup>3</sup>Eye Clinic of Slovak Medical University and University Hospital Bratislava, Slovakia

Submitted to the editorial board: December 2, 2024

Accepted for publication: January 23, 2025

Available on-line: February 21, 2025

*The authors of the study declare that no conflict of interests exists in the compilation, theme and subsequent publication of this professional communication, and that it is not supported by any pharmaceuticals company. The study has not been submitted to any other journal or printed elsewhere, with the exception of congress abstracts and recommended procedures.*



MUDr. Monika Ilavská, PhD.

*Korešpondenčná adresa:*

Medilux očné centrum Galanta

Šafárikova 447/20

924 01 Galanta

Slovensko

E-mail: medilux.ilavska@gmail.com

## SUMMARY

**Aim:** A systematic review of surgical procedures on eyelids and the conjunctival sac in the case of instability of an ocular prosthesis from the author's own experience.

**Material and methods:** In a prospective follow-up conducted from March 2022 to July 2024, the study comprised 51 patients with an unstable prosthesis who were referred by a prosthetist. The study examined the demographic data, cause of enucleation of the eyeball, the time interval between the onset of prosthesis instability and the surgical procedure of enucleation, and the surgical methods of correction to provide functional and aesthetic improvement.

**Results:** The 49 patients included 13 women with a mean age of 61.4 years (39–78) and 36 men with a mean age of 56.3 years (22–82). The most common causes of enucleation were trauma and malignant melanoma. The time interval from surgery/enucleation was 24.4 years for trauma etiology. After enucleation for malignant melanoma, the time interval was 4.2 years. In the 49 patients, 61 surgical procedures were performed to improve stability of the prosthesis. Lateral tarsorrhaphy was performed in 10 cases, 4 of which were combined with an orbital periosteal sling. Horizontal shortening of the lower eyelid was performed in 24 cases, 18 times separately and 6 times in combination with another procedure on the lower eyelid. Upper eyelid droop surgery was performed 8 times, including 5 times separately. Surgery for increasing the volume of the conjunctival sac with amniotic membrane transplantation was performed in 17 cases, 7x separately and 9x in combination with procedures on the lower eyelid. 44 patients underwent 1 surgical procedure, 4 patients underwent 2 procedures, and 3 patients underwent 3 procedures. Three patients also underwent hyaluronic acid injection to supplement the volume of the conjunctival sac.

Cosmetically, the result and stability of the ocular prosthesis was achieved in 47 patients out of 49, 2 patients did not attend further procedures.

**Conclusion:** Conjunctival sac changes with instability of the ocular prosthesis have a significant functional and psychological consequences. The causes of instability are varied, which influences the choice of surgical procedures. The surgical procedures presented in this paper may be effective separately, or a combination of them may be required.

**Key words:** conjunctival sac contracture, horizontal shortening of the lower eyelid, upper eyelid ptosis surgery, amniotic membrane transplantation

*Čes. a slov. Oftal., 81, 2025, No. x, p.*

## INTRODUCTION

Enucleation is a surgical procedure performed in the case of painful conditions of the eyeball as a consequence of trauma or disease, or due to the presence of a tumorous pathology, most commonly uveal melanoma [1]. In the surgical procedure the created conjunctival sac remains for the insertion of an individually produced ocular prosthesis, with or without an orbital implant [2]. After the procedure a suitably shaped anophthalmic conjunctival sac maintains good stability of the prosthesis, which imitates the contralateral eye. Anophthalmic socket syndrome (ASS) is a condition in which asymmetry of the ocular aperture occurs, resulting in falling out of the prosthesis (Figure 1). The condition occurs as a consequence of a shift

of the ocular structures and retraction of the extraocular muscles. The result is sulcus superior syndrome with a dropping of the prosthesis, extension and laxity of the lower eyelid and a shallow lower fornix (Figure 2) [3].

The aim of corrective surgery is to achieve static symmetry of the ocular aperture, a correct canthal tilt, correct vector of the lower eyelid and correct shape of fold of the upper eyelid.

Instability of the prosthesis and problems with the conjunctival sac may be caused by changes in the composition and quantity of tears, bacterial or viral infection and dacryocystitis [4]. Irritation by the prosthesis itself causes Stock eye syndrome, characterized by posterior lamellar truncation of the eyelid and growth of eyelashes against the prosthesis (Figure 3) [5,6].

Droop of the upper eyelid occurs in 2–25 % of patients with anophthalmic syndrome (Figure 4,5). This occurs in the case of loss of support of the levator palpebrae superior muscle by the eyeball, but may also occur due to the same causes as in the presence of the seeing eye (ischemia, myasthenia gravis, diabetes mellitus) [7]. Change of position of the eyelids may also result in repeated extraction and insertion of the prosthesis (Figure 6) [8,9]. Drooping of the eyebrows and lower eyelid occurs in the case of loss of support of the levator palpebrae superior muscle and in the case of forced closure of the ocular aperture in order to prevent falling out of the prosthesis (Figure 7).

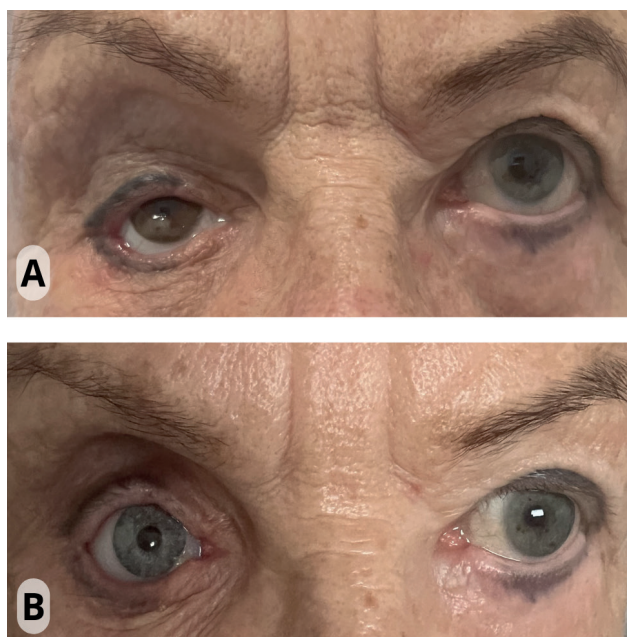
Contractures of the conjunctival sac occur in the early postoperative period, or following a time interval of varying length. They take place directly upon damage to the eye and orbit by primary injury, upon surgical procedure, enucleation of the eyeball or are caused by subsequent changes in the conjunctival sac (Figure 1,8). The severity of contractures also influences the choice of surgical method [9,10].

Surgical procedures are targeted at achieving symmetry of the ocular aperture, enlarging the volume of the conjunctival sac and stability of the ocular prosthesis.

The shape of the ocular aperture can be influenced using permanent lateral tarsorrhaphy, horizontal shortening of the lower eyelid with an orbital periosteal sling [10–15] and upper eyelid droop surgery [16,17], either separately or in combination.

The volume of the conjunctival sac can be influenced using application of an amniotic membrane [9,16–19] or transplantation of a buccal mucosa into the lower or upper conjunctival fornix [9,1].

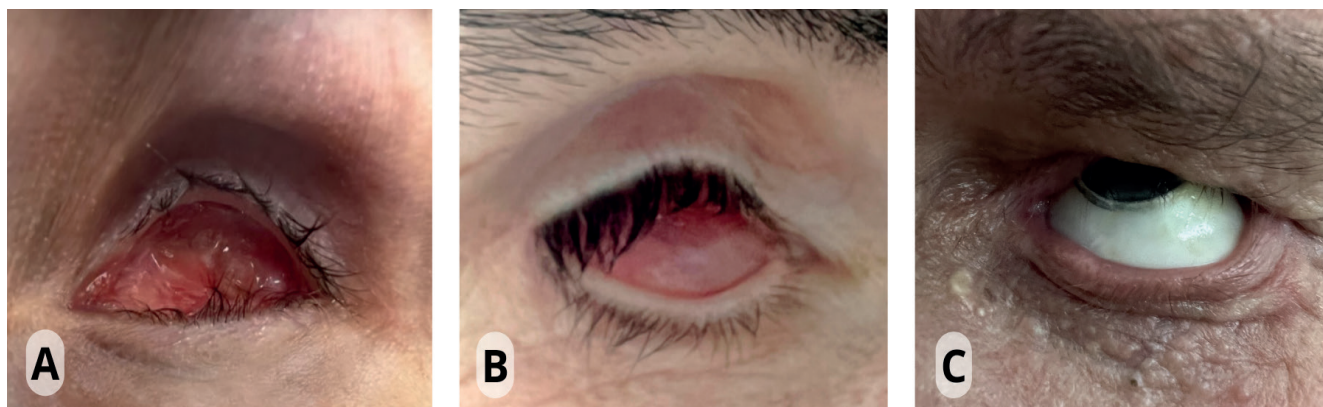
The aim of the study is to evaluate the causes of enucleation of the eye in the given cohort of patients (without orbital implant, with the exception of one patients), to evaluate the time interval between enucleation and onset of instability of the prosthesis, and to evaluate the surgical procedures in the cohort of patients based on the symmetry of the ocular apertures and stability of the prosthesis.



**Figure 2.** Superior sulcus syndrome. Patient post-enucleation due to orbital floor fracture trauma on the right side, not surgically addressed immediately after injury for age and overall condition of patient. (A) Preoperative. (B) Postoperative – tarsorrhaphy and subsequent upper eyelid ptosis and surgery (7 months postoperatively)

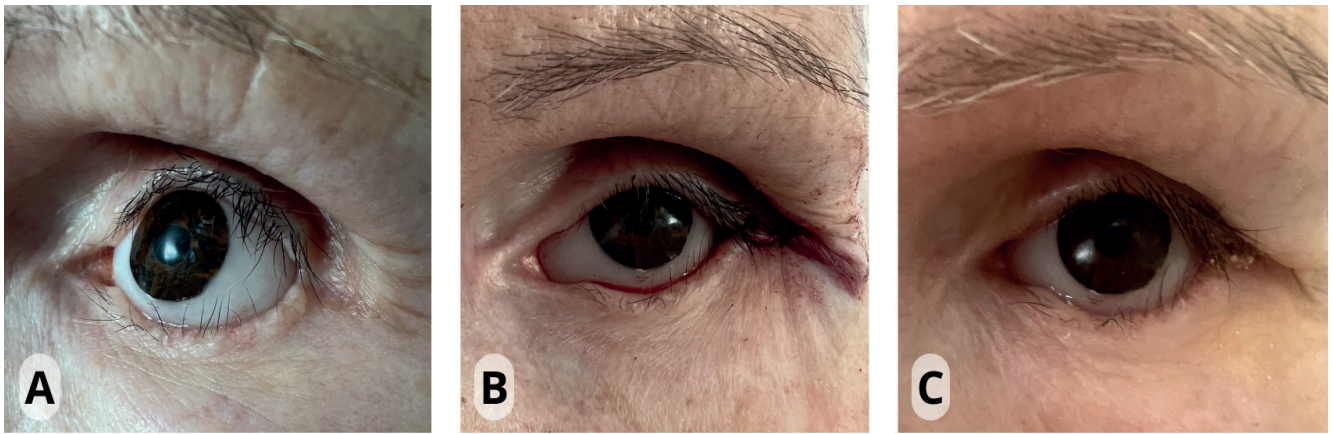## MATERIAL AND METHOD

All the patients reported to the Medilux one-day surgery center due to instability or complete impossibility of wearing an ocular prosthesis. With the exception of one patient they did not have an orbital implant. The parameters observed within the cohort were demographic data, causes of enucleation, time interval from the surgical procedure of enucleation to the onset of instability of the prosthesis and the surgical methods of correction for aesthetic and functional improvement. Informed consent to surgery and the processing of the results was obtained from all patients.

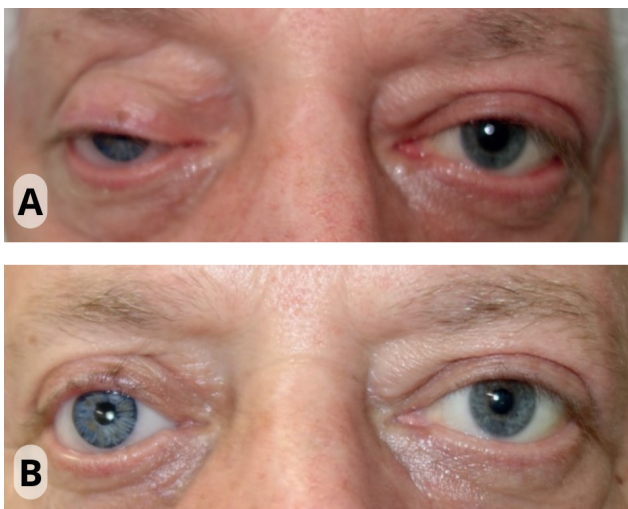


**Figure 1.** Post-enucleation status. (A) Upper and lower fornix adhesions. (B) Ectropion of the lower eyelid and shallow inferior conjunctival fornix. (C) Prosthesis wedged in the lower eyelid due to inferior fornix adhesions

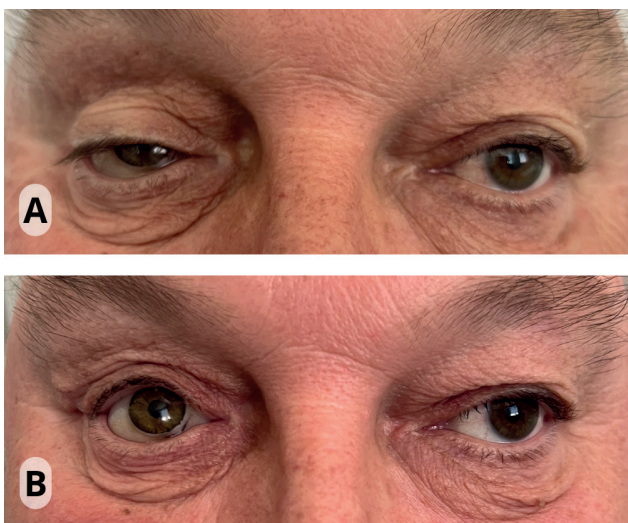




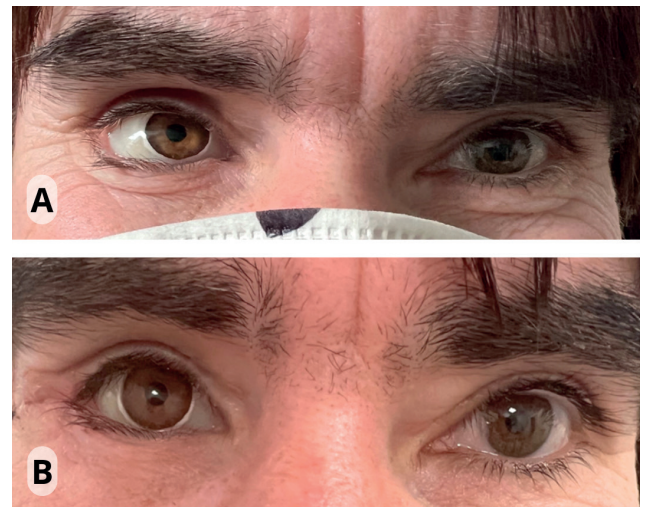**Figure 3.** Stock eye syndrome following multiple tarsorrhaphies at another institution. (A) Preoperative. (B) Postoperative – lateral permanent tarsorrhaphy immediately postoperative. (C) 14 days postoperative



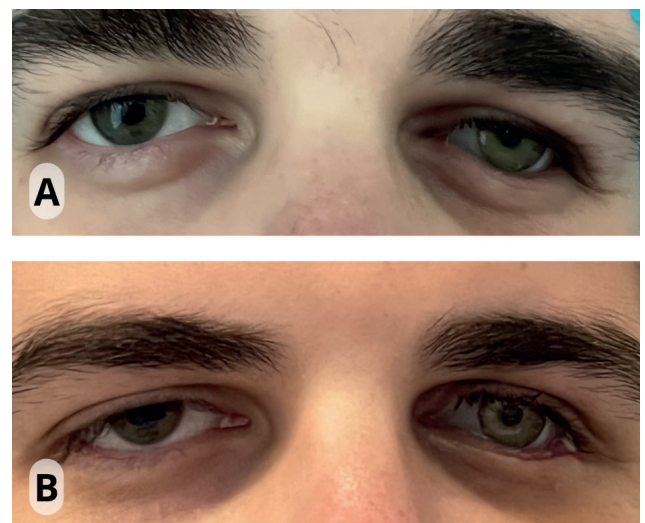**Figure 4.** Right upper eyelid ptosis. Surgery involving shortening of the levator palpebrae superioris muscle aponeurosis. (A) Preoperative. (B) Postoperative



**Figure 5.** Right upper and lower eyelid ptosis. (A) Preoperative. (B) Postoperative upper eyelid ptosis surgery and temporal lower eyelid suspension (3 months postoperative). Patient was subsequently ordered to have a new prosthesis made

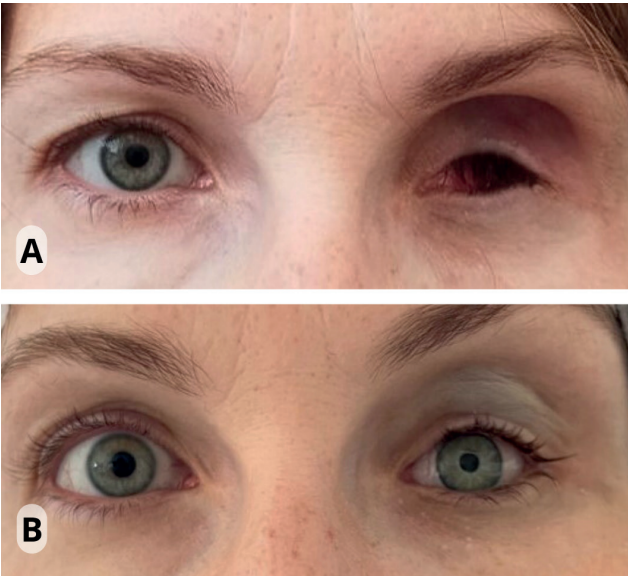


**Figure 6.** Patient after enucleation for childhood retinoblastoma, following horizontal lower eyelid shortening and tarsal fixation to orbital periosteum. (A) Preoperative. (B) Postoperative (2 months postoperative)



**Figure 7.** Patient after enucleation in childhood. (A) Left eyebrow ptosis and altered lower eyelid vector, shallow conjunctival sac. (B) Post-amniotic membrane transplantation for conjunctival sac enlargement and eyebrow fixation to periosteum

In the period from March 2022 to July 2024 a total of 49 patients with an unstable prosthesis following enucleation of the eyeball, who had been referred by a prosthetist, were treated at the above center. The de-



**Obrázok 8.** Patient post-enucleation for malignant melanoma. Six months postoperatively, contractures developed, preventing prosthesis wear. (A) Surgery to enlarge the inferior fornix with amniotic membrane transplantation and subsequent hyaluronic acid application to the upper orbit and upper eyelid. (B) 3 months postoperative

mographic data are presented in Table 1. Malignant melanoma was the cause of enucleation in 9 patients, while 30 patients underwent enucleation of the eye following a severe devastating trauma. Three patients underwent enucleation in early childhood due to retinoblastoma. Complications following retinal detachment were the reason for surgery in two patients, and severe diabetic changes in two patients. 48 patients underwent enucleation of the eyeball without insertion of an orbital implant. One patient had an implanted hydroxyapatite orbital implant with preserved motility of the prosthesis. The patients underwent the surgical procedures presented in Table 2 under local anesthesia, performed by a single surgeon.

Lateral tarsorrhaphy was performed in two layers (suture of anterior and posterior lamella) with excision of the edges of the eyelids. The positioning of the lower eyelid was improved by horizontal shortening of the lower eyelid with or without fixation to the orbital periosteum. Upper eyelid droop surgery with shortening of the levator palpebrae superior muscle was combined with blepharoplasty of the upper eyelid. Transplantation of an amniotic membrane was used in the case of a shallow lower fornix or small volume of the conjunctival sac.

## RESULTS

The evaluation was performed at a time interval of 1–2 months after surgery. Some of the patients had already been observed for more than 2 years and their ocular prosthesis was subsequently replaced. With regard to

**Table 1.** Demographic data in the group of patients after enucleation

Demography	Count	Average age / years	Age range / years
Women	13	62.4	39–78
Men	36	56.3	22–82

**Table 2.** Surgical Procedures to Secure Ocular Prosthesis Stability

Surgical Procedure 2022–2023 Medilux Eye Center Galanta	Count
Lateral tarsorrhaphy	6
Lateral tarsorrhaphy with suspension of the lower eyelid to the orbital periosteum	4
Horizontal shortening of the lower eyelid	18
Horizontal shortening of the lower eyelid with suspension	6
Surgery for upper eyelid ptosis in case of unstable prosthesis	5
Ptosis surgery with horizontal shortening of the lower eyelid	1
Ptosis surgery with suspension of the lower eyelid	2
Isolated surgery of the lower eyelid suspension to the orbital periosteum	1
Disruption of conjunctival adhesions	2
Amniotic membrane (AM) transplantation for deepening the lower fornix	7
AM transplantation with horizontal shortening of the lower eyelid	6
AM transplantation with horizontal shortening of the lower eyelid and placement of fixation sutures on the lower eyelid	1
AM transplantation with suspension of the lower eyelid to the orbital periosteum	2
Total	61



the character of the one-day surgery center, the cohort is not homogeneous. The patients who reported to us had varying degrees of instability of the prosthesis, or were unable to wear it whatsoever. More than one half of the patients removed the prosthesis for the night and did not apply any lubrication. Three patients reported pronounced chronic inflammation of the conjunctivae, which was treated before the surgical procedure with local antibiotic therapy. The regimen measures summarized in the conclusion of the study brought about an improvement of the condition of the conjunctival sac. In the observed period a total of 61 operations were performed in order to improve the stability of an individually produced acrylate prosthesis in the conjunctival sac of patients following enucleation of the eye. Out of the 49 patients in the cohort, 42 patients underwent only one operation, 4 patients underwent 2 procedures and 3 patients required 3 procedures. In some patients it was evident at the initial examination that one procedure would not be sufficient, and that another procedure would be required after a certain period of time (first of all on the lower eyelid and lower fornix, with a subsequent operation for upper eyelid droop). In some cases a new ocular prosthesis were produced after the healing of the surgical wound in the conjunctival sac.

Data on the causes of enucleation and the time interval between the primary operation and the onset of instability of the prosthesis are presented in Table 3. In our cohort, the average time interval from the primary operation was shorter in the group with malignant choroidal melanoma than in the group who had suffered ocular traumas.

A hyaluronic acid injection was applied to three patients in order to supplement the volume of the conjunctival sac. A cosmetic result and better position and stability of the prosthesis was achieved in 47 patients, who were satisfied with the improvement of the positioning of the eyelids. In 2 patients the desired effect was not achieved; these patients did not attend for further procedures. Subsequent follow-up examinations after a time interval were planned for all patients in whom the above procedures were performed in order to evaluate the stability of the result.

## DISCUSSION

Enucleation of the eyeball is performed most frequently due to presence of uveal melanoma, in up to 98% of ca-

ses, and in 1% for other types of tumors [1]. The spectrum of indications for enucleation is in accordance with the literature [21]. The shorter time between the operation and the onset of contractures in the case of a tumor etiology is probably caused by the radical nature of the procedure and the subsequent treatment (radiotherapy), which was not recorded in our cohort.

Achieving symmetry of the ocular aperture is important not only from a cosmetic perspective, but especially in order to secure the stability of the ocular prosthesis. It is difficult to achieve complete symmetry in the size of the prosthesis and the bulb and full upper eyelid excursion. Adequate upper eyelid excursion and a sufficiently deep lower fornix hold the prosthesis in place [14].

Tarsorrhaphy is effective in a larger vertical dimension of the ocular aperture and lagophthalmos, in which the prosthesis remains exposed even after closure of the eyelids. It is suitable to perform tarsorrhaphy in two layers when there is a higher probability of fusion of the eyelids [8,9].

Horizontal shortening of the lower eyelid is indicated in the case of overhanging, extension of the lower eyelid caused by weakening of the orbicularis oculi muscle and extension of the lateral canthal ligament. For correction, a triangle of the tarsus and palpebral conjunctiva is cut out laterally, and the skin is shifted laterally where the adaptation triangle is cut out. In the case of droop of the outer ocular canthus it is appropriate to change the vector of the lower eyelid by fixation to the periosteum with a non-absorbable suture. The authors' experiences have confirmed that it is appropriate to perform this combined approach as the primary procedure for better postoperative results. This is in accordance with the data in the literature [11–14].

Upper eyelid droop surgery may be required primarily or this need may become more pronounced after correction of the position of the lower eyelid. Blepharoplasty of the upper eyelid with excision of the skin is combined with shortening of the levator palpebrae superior muscle ab externum. The suitability of this procedure is also stated by other authors. Before ptosis surgery it is important to resolve the volume of the conjunctival sac and the position of the lower eyelid [7,9,11].

Contractures of the conjunctival sac may be the consequence of a previous surgical procedure, early removal of the conformer (expander) of the conjunctival sac, in-

**Table 3.** Causes of eyeball enucleation and the time interval between the onset of prosthesis instability since primary surgical procedure (enucleation)

Reason for Enucleation	Women	Men	Average Time (years)	Minimum Time (years)	Maximum Time (years)
Malignant Melanoma of the Choroid	5	3	4.2	1	10
Eye Injury	3	26	24.4	1	68
Retinoblastoma	1	3	36.6	24	47
Retinal Detachment	2	1	2	2	2
Complications of Diabetic Retinopathy	1	1	2.5	1	4
Other	1	2	25.4	14	41

correct wearing and shape of the prosthesis, recurrent inflammations or immunological disorders (Stevens Johnson syndrome) [9]. The main role in the process of onset of contractures is played by myofibroblasts. The suitability of amniotic membrane transplant for reconstruction of a contracted conjunctival sac has been confirmed by multiple authors [18–20, 22,23]. It is considered a viable alternative to transplant of the buccal mucosa [20]. The regenerative capacity of the amniotic membrane improves the healing of defects and improves the cosmetic appearance following epithelialization over the course of a few weeks. During this time the prosthesis fulfils the function of a conformer of the conjunctival sac.

Loss of an eye is associated also with changes of the conjunctiva and lacrimal apparatus. The quantity and quality of tears is altered. The accumulated secretion behind the prosthesis may be infected, and the subsequent inflammation causes contractures in the conjunctival sac. Morphological changes of the lacrimal glands also occur, with the onset of dry anophthalmic syndrome of the conjunctival sac [24]. Correct size of the prosthesis (which should maximally fill the conjunctival sac) prevents the accumulation of secretion behind the prosthesis. In such a case the lacrimal film on the surface of the prosthesis keeps it clean, which is confirmed by the fact that patients can wear a well shaped prosthesis for a long period of time. In the case of a poorly produced prosthesis with the accumulation of large quantity of fluid behind it patients are forced to repeatedly remove, clean and insert the prosthesis, which worsens the condition. The frequency of handling influences the quality of the lacrimal film. The same applies in the case of leaving the conjunctival sac without the prosthesis overnight. In this case the oculomotor muscle and the levator palpebrae superior muscle are weakened, which leads to the above-mentioned changes. A damaged surface of the prosthesis may worsen this condition [8,18,25].

#### Practical experiences of authors / take home message

A correctly shaped, sufficiently large and stable prosthesis may remain in the conjunctival sac over-

night. It is suitable to remove and clean the prosthesis once per day, if a large amount of secretion does not accumulate it may be removed once every 2 days. In the case of a feeling of pressure or dryness in the conjunctival sac it is appropriate to apply lubrication in the form of a gel or cream. In the case of acute inflammation of the conjunctiva it is necessary to treat the inflammation with local antibiotics.

In the case of instability of the prosthesis it is first of all necessary to evaluate the condition of the eyelids. In the case of extension and droop of the lower eyelid it is first of all suitable to perform horizontal shortening of the lower eyelid or tarsorrhaphy. Droop of the upper eyelid can be resolved by shortening the aponeurosis of the levator palpebrae superior muscle. Upon loss of volume or truncation of the posterior lamella of the lower eyelid it is suitable to increase the volume of the lower fornix of the conjunctival sac through application of an amniotic membrane or buccal mucosa. Following corrective operations of the conjunctival sac it is suitable to administer antibiotics locally in order to prevent infection, and subsequently corticosteroids locally in the form of cream in order to prevent early contractures. The new prosthesis should have a shape and size equal to or larger than the prosthesis before correction.

## CONCLUSION

Instability of an ocular prosthesis has significant functional and psychological consequences. Resolving these conditions represents a challenge for the surgeon. Stability of the prosthesis may be achieved by one or several procedures. Patient compliance is important, as well as thorough information about the possible postoperative course and the possibility that several surgical procedures will be required. A very important role is played by the prosthetist, since the correct size and shape of the prosthesis is important for maintaining the postoperative result.

## REFERENCES

1. Furdova A, Horkovicova K, Furda R, et al. Two 11-Years Periods Statistics and Trends of Enucleation and Evisceration. *J Craniofac Surg.* 2021 Nov-Dec 01;32(8):2701-2705. doi: 10.1097/SCS.00000000000007727
2. Wu KY, Fujioka JK, Daigle P, Tran SD. The Use of Functional Biomaterials in Aesthetic and Functional Restoration in Orbital Surgery. *J Funct Biomater.* 2024 Jan 29;15(2):33. doi: 10.3390/jfb15020033
3. Rokohl AC, Kopecky A, Trester M, Wawer Matos PA, Pine KR, Heindl LM. Post-enucleation socket syndrome-a novel pathophysiological definition. *Graefes Arch Clin Exp Ophthalmol.* 2022 Aug;260(8):2427-2431. doi: 10.1007/s00417-022-05648-z
4. Adrian T, Lubis RR, Zubaidah TSH. Association between Frequency of Prosthesis Cleaning and the Discharge Characteristics and the Tear Film in Subjects with Anophthalmic Socket after Evisceration with Dermis Fat Graft. *Open Access Maced J Med Sci.* 2018 Nov 23;6(11):2012-2016. doi: 10.3889/oamjms.2018.468
5. Rutgers S, Mombaerts I. The prevalence of anophthalmic socket syndrome and its relation to patient quality of life. *Eye (Lond).* 2021 Jul;35(7):1909-1914. doi: 10.1038/s41433-020-01178-2
6. Ibrahim MF, Abdelaziz ST. Shallow Inferior Conjunctival Fornix in Contracted Socket and Anophthalmic Socket Syndrome: A Novel Technique to Deepen the Fornix Using Fascia Lata Strips. *J Ophthalmol.* 2016;2016:3857579. doi: 10.1155/2016/3857579
7. Custer PL, Maamari RN, Huecker JB, Gordon MO. Anophthalmic Ptosis and the Effects of Enucleation on Upper Eyelid Function. *Ophthalmic Plast Reconstr Surg.* 2021 May-Jun 01;37(3S):S80-S84. doi: 10.1097/IOP.0000000000001823
8. Goel R, et al. *Manual of Oculoplasty.* Jaypee Brothers Medical Publishers; London: 2011. p. 104-113.
9. Quaranta-Leoni FM, Fiorino MG, Quaranta-Leoni F, Di Marino M. Anophthalmic Socket Syndrome: Prevalence, Impact and Management Strategies. *Clin Ophthalmol.* 2021 Aug 6;15:3267-3281. doi: 10.2147/OPTH.S325652
10. Tawfik HA, Raslan AO, Talib N. Surgical management of acquired socket contracture. *Curr Opin Ophthalmol.* 2009 Sep;20(5):406-411. doi: 10.1097/ICU.0b013e328323ed85b

11. Anderson RL. Tarsal strip procedure for correction of eyelid laxity and canthal malposition in the anophthalmic socket. *Ophthalmology*. 1981 Sep;88(9):895-903. doi: 10.1016/s0161-6420(81)80003-6
12. Anderson RL, Gordy DD. The tarsal strip procedure. *Arch Ophthalmol*. 1979 Nov;97(11):2192-2196. doi: 10.1001/archophth.1979.01020020510021
13. Weiss RA, McCord CD Jr, Ellsworth RM. Reconstruction of the anophthalmic socket: lower eyelid malposition and canthal tendon laxity. *Adv Ophthalmic Plast Reconstr Surg*. 1990;8:192-208.
14. Bosniak SL. Reconstruction of the anophthalmic socket: state of the art. *Adv Ophthalmic Plast Reconstr Surg*. 1987;7:313-348.
15. Bosniak SL. Abnormalities of the palpebral aperture. *Adv Ophthalmic Plast Reconstr Surg*. 1990;8:243-258.
16. Nerad, Jeffrey A. *Techniques in Ophthalmic Plastic Surgery: a Personal Tutorial*. [Philadelphia] :Saunders Elsevier, 2010. p. 201-235.
17. Šplíchal L. *Manuál oční plastické a estetické chirurgie: Základní techniky*. Praha: Mladá fronta; 2018. p. 57-103. Czech.
18. Slentz DH, Nelson CC. Novel Use of Cryopreserved Ultra-thick Human Amniotic Membrane for Management of Anophthalmic Socket Contracture. *Ophthalmic Plast Reconstr Surg*. 2019 Mar/Apr;35(2):193-196. doi: 10.1097/IOP.0000000000001264
19. Topcu H, Serefoglu CK, Cetin EA, et al. The current alternative for ocular surface and anophthalmic socket reconstruction, cryopreserved umbilical amniotic membrane (cUAM). *Int Ophthalmol*. 2024 Jun 25;44(1):274. doi: 10.1007/s10792-024-03232-4
20. Ilavská M, Kardos L. Rekonstrukcia spojovkového vaku po enukleácii ocného bulbu v minulosti--dva spôsoby chirurgického riešenia [The reconstruction of conjunctival socket after enucleation of the eye in post--two possibilities of surgical solution]. *Cesk Slov Oftalmol*. 2011 Aug;67(3):97-100. Slovak.
21. Aryasit O, Preechawai P. Indications and results in anophthalmic socket reconstruction using dermis-fat graft. *Clin Ophthalmol*. 2015 May 4;9:795-799. doi: 10.2147/OPTH.S77948
22. Borrelli M, Geerling G, Spaniol K, Witt J. Eye Socket Regeneration and Reconstruction. *Curr Eye Res*. 2020 Mar;45(3):253-264. doi: 10.1080/02713683.2020.1712423
23. Bajaj MS, Pushker N, Singh KK, Chandra M, Ghose S. Evaluation of amniotic membrane grafting in the reconstruction of contracted socket. *Ophthalmic Plast Reconstr Surg*. 2006 Mar-Apr;22(2):116-120. doi: 10.1097/01.iop.0000200887.26015.d4
24. Rokohl AC, Trester M, Naderi P, et al. Dry anophthalmic socket syndrome - morphological alterations in meibomian glands. *Eye (Lond)*. 2021 Dec;35(12):3358-3366. doi: 10.1038/s41433-021-01426-z
25. Penitente PA, Da Silva EVF, Goiato MC, et al. The Inflammation Level and a Microbiological Analysis of the Anophthalmic Cavities of Unilateral Ocular Prosthesis Users: A Blind, Randomized Observational Study. *Antibiotics (Basel)*. 2022 Oct 27;11(11):1486. doi: 10.3390/antibiotics11111486