

PNEUMATIC VITREOLYSIS USING C3F8 GAS IN TREATMENT NAIVE PATIENTS WITH VITREOMACULAR TRACTION

Marková Kateřina, Němec Pavel, Červený Petr, Havlík Jan, Rejmont Leoš, Tesař Jan, Morin Hana, Šín Martin

Department of Ophthalmology 1st Faculty of Medicine of Charles University and Military University Hospital, Prague, Czech Republic

The authors of the study declare that no conflict of interests exists in the compilation, theme and subsequent publication of this professional communication, and that it is not supported by any pharmaceutical company. The study has not been submitted to any other journal or printed elsewhere.

Submitted to the editorial board: February 14, 2024

Accepted for publication: April 3, 2024

Available on-line: July 1, 2024



MUDr. Kateřina Marková
Oční klinika 1. LF UK a ÚVN Praha
U Vojenské nemocnice 1200
169 02 Praha 6
E-mail: markova.katerina@uvn.cz

SUMMARY

Purpose: Evaluation of the effectiveness of pneumatic vitreolysis in disrupting vitreomacular traction in our own cohort of patients.

Methodology: Prospective follow-up of 21 eyes of 18 patients with focal VMT (adhesion width < 1500 µm) who underwent intravitreal injection of 0.3 ml of 100% perfluoropropane between January 2015 and December 2020. The patients were observed for 90 days.

Results: Release of VMT was achieved on the 28th day of observation in 15 out of 21 eyes (71.4%), and by the 90th day in 19 out of 21 eyes (90.5%). The average width of adhesion in our patients was 382 µm (±212 µm). Average best corrected visual acuity in our cohort was initially 0.77 (±0.21), after 28 days 0.74 (±0.30), and after 3 months 0.82 (±0.21). At the end of the follow-up period, we did not observe a statistically significant improvement in vision. Macular holes developed in two eyes, but spontaneously closed within 1 month of observation, and no more complications were observed in the cohort.

Conclusion: Pneumatic vitreolysis by intravitreal injection of C3F8 gas is an effective and inexpensive option for the management of symptomatic vitreomacular traction. The incidence of serious adverse events in our follow-up was significantly lower than in recently published series. The method of management should be selected individually according to the parameters of adhesion, macular hole and associated ocular pathologies.

Key words: intravitreal injection, pars plana vitrectomy, vitreous detachment, C3F8, perfluorocarbons, prospective study

Čes. a slov. Oftal., 80, 2024 No. x, p. xx–xx

INTRODUCTION

Vitreomacular traction (VMT) ranks within the spectrum of disorders of the vitreoretinal interface, i.e., pathologies on the level of the posterior vitreous membrane and the internal limiting membrane of the retina, in the region of the macula. A pre-stage of VMT is vitreomacular adhesion (VMA), wherein upon detachment of the vitreous as part of the normal aging process, the connection of the posterior vitreous membrane with the retina persists in the region of the foveola, but the cytoarchitecture is not disrupted. In the case of VMT, disruption of the architecture of the layers of the neuroretina takes place by means of traction of the vitreous. VMT may occur in isolated form, and in such a case is referred to as idiopathic vitreomacular traction syndrome. VMT and VMA may also be a component of other pathological conditions, for example cystoid macular edema (CME), lamellar defect, complete macular hole (MH), macular pucker or diabetic macular edema (DME) [1,2]. It is estimated that approximately 1.5% of the population is affected by ocular pat-

hologies associated with VMA, and its annual incidence in the USA is 0.6 per 100 000 eyes [3].

The current approaches to symptomatic VMT include observation, pars plana vitrectomy (PPV), intravitreal application of ocriplasmin (Jetrea; TromboGenics NV, Leven, Belgium) and pneumatic vitreolysis (PVL). Each of these methods has its advantages and disadvantages. Observation is a non-invasive procedure. Opinions on the frequency of spontaneous release of vitreomacular traction differ according to the available studies. Hikichi et al. described complete detachment of the posterior vitreous in only 11% of eyes during observation, which for the majority of eyes was over a period of between 1 and 3 years. In 64% of eyes a deterioration of visual acuity (VA) was recorded by 2 rows on a Snellen chart [4]. John et al., in their study using OCT, described a markedly higher degree of spontaneous release of VMT. Their average observation period was 2 years, in which they observed release in 32% of eyes, demonstrated stability of visual acuity during the observation period and a relatively low percentage of cases with progression to the more severe form (16%) [5]. To date it

is not possible to reliably predict the course towards spontaneous release of VMT, or conversely towards the occurrence of complete MH. For this reason, observation is not the best choice for all cases of VMT, and remains reserved rather for cases of less advanced stages of VMT [6]. By contrast with observation, PPV represents the most invasive solution, which, though it has the potential to achieve release of VMT in the majority of patients and still remains the treatment of first choice in this indication, also entails a considerable financial burden and involves risks such as intraocular infection, retinal tears or retinal detachment, or progression of cataract.

Pharmacological vitreolysis by means of intravitreal application of ocriplasmin is a more recent and less invasive solution, which was approved for patients with VMT syndrome by the FDA (US Food and Drug Agency) in October 2012[7]. Ocriplasmin is a recombinant truncated version of human plasmin, which cleaves laminin, fibronectin and type 4 collagen, generating liquefaction of the vitreous and helping release and dissolve vitreous adhesion to the retina [8]. Although in the study Microplasmin for Intravitreal Injection-Traction Release without Surgical Treatment (MIVI-TRUST) the authors demonstrated a higher degree of release of VMT after a single intravitreal injection of ocriplasmin in comparison with an injection of physiological solution (26.5% vs. 10.1%), the success rate for release of traction is nevertheless far lower than in the case of PPV [9]. The method is burdened by adverse side effects such as transitional loss of sight, subluxation of the lens, changes of electroretinogram, changes of the ellipsoid zone of the retina, dyschromatopsia etc. [10]. Furthermore, treatment with ocriplasmin, similarly to PPV, is relatively expensive.

The last method for release of the posterior vitreous is injection of expansive gas. Over the course of 24 to 48 hours, a bubble of 100% SF₆ gas expands to approximately double the injected volume, and remains in the eye for 1 to 2 weeks. Over the course of 72 to 96 hours, a bubble of C₃F₈ gas expands to approximately four times its original volume, and remains within the vitreous cavity for 6 to 8 weeks. This method was described by Chan et al. in 1995 on a group of patients with complete macular hole with VMT, with the use of C₃F₈ gas, in which they achieved a 96% success rate in release of VMT and a 57% success rate in closure of small stage 2 MH [11]. The successful use of this method was later reported in 2001 by Cost et al., in 2006 by Jorge et al., with a 100% success rate in release of vitreomacular traction and an 83% success rate in the closure of stage 2 MH [12,13]. In 2007 Mori et al. published a series of cases with the use of SF₆ gas and positioning, with a similarly high success rate: 95% in release of VMT and 50% in closure of MH [14]. In 2013 Rodrigues et al. conducted a study on idiopathic VMT syndrome with the use of C₃F₈ gas. The success rate in release of VMT was 40% after one month and 60% within six months [2]. In 2019 our colleagues from the Královské Vinohrady University Hospital published a cohort of 14 eyes with VMT with a high success rate in release of tra-

ction following the application of C₃F₈. Within 28 days traction was released in 84.6% of eyes, and over the observation period in total in 92.9% of eyes. The average visual acuity of the observed cohort demonstrated a statistically significant improvement [15].

At our center we conducted a prospective observation of 21 treatment naive eyes with VMT over the course of 3 months, in which intravitreal application of perfluoropropane was performed (C₃F₈).

MATERIAL AND METHODS

The study describes a prospective conceptual series of 21 eyes of 18 patients with VMT who underwent intravitreal application of perfluoropropane during the period from January 2015 to December 2020. The study was conducted in accordance with good clinical practice with respect to the Helsinki declaration, and was approved by the ethical commission of the Military University Hospital in Prague. Written informed consent was obtained from all the participants, each of whom had the option of leaving the study at any time without explanation. Our observation cohort comprised 4 men and 14 women within the age range of 52–90 years (average 74 ± 8 years). 7 out of 21 eyes were phakic. The patients underwent an identical baseline examination, and subsequently a follow-up on the 1st, 7th, 28th and 90th day after application. The inclusion criteria for the study were as follows: VMT up to 1500 µm (focal type) within a radius of 3000 µm from the fovea, demonstrated by optical coherence tomography (OCT), and age of over 50 years. The exclusion criteria were a medical history of intravitreal injection with ocriplasmin, medical history of intravitreal administration of any pharmaceutical, presence of wet form of age-related macular degeneration, DME, CME, MH, retinal vein occlusion, glaucoma and myopia of more than 6 diopters. The primary endpoint was to determine success of release of VMT in the 1st and 3rd month after application of the expansive gas C₃F₈, and the secondary endpoint was to evaluate resulting best corrected visual acuity (BCVA), the development of intraocular pressure during the course of observation, to determine the time scale of disappearance of the gas bubble from the vitreous, and to evaluate the quantity and type of complications of the procedure during the follow-up period of the study. The demographic data, fundamental characteristics and characteristics after treatment are summarized in Table 1.

All the follow-ups incorporated an examination of best corrected visual acuity according to a Snellen chart (Auto chart projector ACP 8, Topcon, Japan), biomicroscopy of the anterior and posterior segment (Slit lamp Topcon and Zeiss), non-contact tonometry (Auto kerato-refractometer TRK-2P, Topcon, Japan) and OCT (Spectralis OCT, Heidelberg Engineering, Heidelberg, Germany).

Mydriasis of the treated eye was attained by application of phenylephrine 10% (Neosynephrin-POS 10%, Ursapharm Arzneimittel GmbH.) and tropicamide 1.0% (Unitropic 1% gtt., Unimed Pharma).

The procedure was performed in an outpatient regimen under topical anesthesia (Benoxi 0.4% gtt, Unimed Pharma) in an operating theater. The surrounding area of the eye and the conjunctival sac were disinfected using Betadine solution (5% povidone-iodine solution in a dilution ratio of 1:16, Egis) within an operating field covered with a sterile screen with an applied eye speculum. We induced hypotonia of the eyeball by means of corneal paracentesis, and we then applied 0.2 ml of 100% perfluoropropane (GOT Multi C3F8, Alchimia) via a pars plana route. The application was performed using a 30Ga needle at a distance of 3.5 mm from the corneal limbus in arterphakic eyes, and 4 mm from the limbus in phakic eyes. At the end, an eye pressure check was performed, potentially followed by reduction of the pressure by the original paracentesis.

After completion of the procedure, rinsing with Betadine solution was repeated, and Ofloxacin 5 mg/ml gtt.1x (Of-taquix 0.05%, Santen OY) and Timolol 5 mg/ml gtt 1x (Arutimol 0.05%, Chauvin) were also applied to the patients.

The patients were left with sterile covering until the evening of the day of application. No regimen adjustments were recommended, and no further anti-glaucomatous or antibiotic medications were indicated after the procedure. The application of gas was performed once only for all eyes.

RESULTS

According to the subsequent OCT examination (Figure 1), release of VMT was achieved in 19 out of 21 eyes (90.5%). In two eyes (9.5%) release was observed at a follow-up already on the 1st day after application, then after one week in

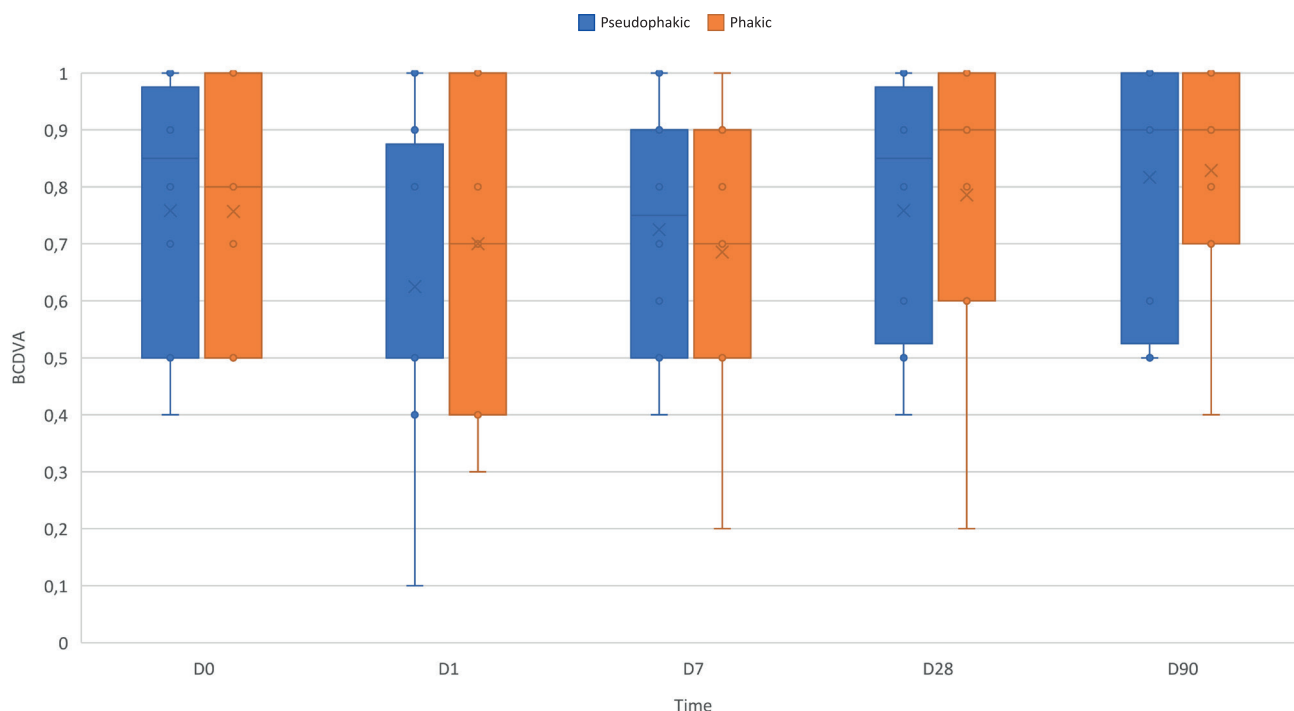
a further 9 eyes (42.9%, total 52.5%), up to the 28th day after application traction was released in a further 4 eyes (19%, total 71.4%). After 3 months release had been achieved in a further 4 eyes (19%), while we did not succeed in releasing VMT in 2 eyes (9.5%) with a single application of gas. The average width of adhesion in our patients was $382 \pm 212 \mu\text{m}$.

Average baseline BCVA in our cohort was 0.77 ± 0.21 , average BCVA after 28 days was 0.74 ± 0.30 , and after 3 months 0.82 ± 0.21 . We observed an improvement or stable BCVA after 1 and 3 months in 14 out of 19 eyes with released VMT (improvement in 8 eyes, stabilization in 6 eyes), while visual acuity did not deteriorate further in either of the eyes with persistent traction. Deterioration of BCVA was observed in 5 eyes, in 4 of which by less than 1 row according to the Snellen chart, in one eye by 2 rows. Elevation of intraocular pressure above 25 mmHg occurred in only one case at the 1st follow-up. The observed values of BCVA and IOP are illustrated in Graphs 1 and 2.

Disappearance of the gas bubble was observed in 2 eyes after one week, in 10 cases after one month, in 8 patients the bubble disappeared within two months and in one case it persisted even after three months.

We statistically analyzed the data in the group of phakic and arterphakic patients for the variables of BCVA and IOP. We set the level of statistical significance at $p < 0.05$. The normal distribution of the groups was tested by a Shapiro-Wilk test and QQ graphs, the assumptions of homogeneity of variance and covariance were tested with Levene's test and Box's M test. 2 eyes were excluded from the statistics due to incomplete data.

We analyzed the influence of measurement over time and phakia on the BCVA and IOP values using the



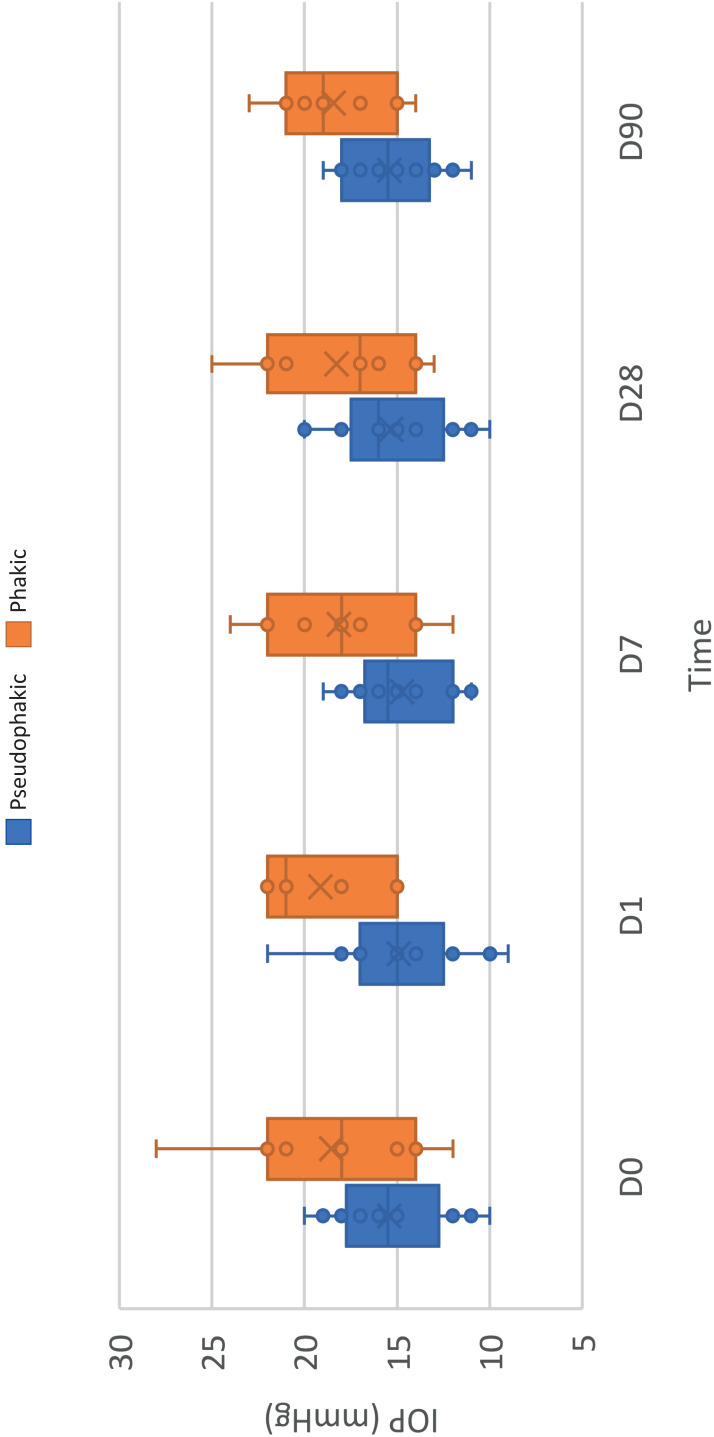
Graph 1. Visual acuity development during follow-up: D0 – on the day of injection, D1 – 1st day after injection, D7 – one week after injection, D28 – one month after injection, D90 – 3 months after injection

Table 1. Follow-up results

Patient no.	Patient's data					Day of treatment			Day 1			1 Week			1 Month			3 Months		
	Sex	Age	Eye	Lens	Width of adhesion (µm)	Other macular diseases	BCDVA	IOP	BCDVA	IOP	VMTS	C3F8	BCDVA	IOP	VMTS	C3F8	BCDVA	IOP	VMTS	C3F8
1	female	52	OD		1033	ERM	0.7	15	0.5	15	*	X	0.6	15	*	Y	0.6	15	*	-
2	male	75	OS	pseudo-phakic	247	ERM	0.5	19	0.5	17	*	X	0.4	17	**	X	0.4	20	-	30. day Y
3	female	73	OS	pseudo-phakic	255	not present	1	17	0.5	17	*	X	0.7	18	**	X	0.8	18	-	Y
4	female	69	OD	pseudo-phakic	384	not present	0.9	20	0.1	22	*	X	0.9	19	**	X	0.9	20	-	Y
			OS	pseudo-phakic	257	not present	0.9	18	0.4	16	*	X	0.8	18	**	X	-	-	-	14. day Y
5	female	75	OS	phakic	351	ERM	0.5	12	0.3	15	*	X	0.2	17	*	X	0.2	17	**	Y
6	female	65	OS	pseudo-phakic	89	not present	0.8	20	0.7	25	**	X	-	-	-	-	1	21	-	Y
7	male	90	OD	pseudo-phakic	96	not present	0.8	12	0.8	12	*	X	0.9	12	*	X	0.9	12	**	-
8	female	78	OD	pseudo-phakic	507	not present	0.5	10	0.4	10	*	X	0.5	11	**	8. day Y	0.5	11	-	-
			OS	pseudo-phakic	687	not present	0.5	11	0.5	9	*	X	0.5	11	**	X	0.5	10	-	29. day Y
9	female	71	OS	phakic	350	not present	0.5	21	0.4	22	*	X	0.5	22	*	X	0.6	21	**	X
10	female	78	OS	pseudo-phakic	295	ERM	0.4	15	0.5	15	*	X	0.5	12	*	X	0.6	14	**	23. day Y
11	female	73	OD	phakic	485	VPMD	0.8	15	1	18	**	X	1	18	-	X	1	14	-	33. day Y
12	female	73	OD	phakic	424	not present	1	18	0.8	21	*	X	0.8	14	**	X	1	16	-	X
13	female	81	OS	pseudo-phakic	581	not present	0.9	16	0.9	15	*	X	0.8	14	*	X	0.9	16	*	X
14	male	67	OS	pseudo-phakic	383	not present	1	17	1	15	*	X	1	16	*	X	1	16	*	X
15	male	75	OS	pseudo-phakic	305	not present	1	14	1	15	*	X	0.9	12	**	X	1	13	-	X

16	female	83	OD	pseudo-phakic	418	not present	1	15	1	14	*	X	1	16	**	X	1	16	-	37. day Y	1	15	-	-
17	female	80	OS	pseudo-phakic	254	VPMD	0.9	18	0.8	18	*	X	0.9	16	*	X	1	16	*	X	1	17	**	41. day Y
18	female	72	OD	phakic	234	NPDR	0.7	22	0.7	21	*	X	0.7	20	*	X	0.8	25	*	X	0.7	21	**	43. day Y
			OS	phakic	255	NPDR	0.8	28	0.7	22	*	X	0.7	24	*	X	0.9	22	*	X	1	23	*	40. day Y

OD – right eye, OS – left eye, C3F8 – perfluoropropane, VMTS – vitreomacular traction syndrome, BCDVA – best corrected distance visual acuity, ARMD – Age-related macular degeneration, IOP – intraocular pressure, ERM – Epiretinal membrane, NPDR – non-proliferative diabetic retinopathy, * – presence of vitreomacular traction, ** – release of vitreomacular traction, X – presence of perfluoropropane bubble, Y – disappearance of perfluoropropane bubble



Graph 2. Intraocular pressure development during follow-up: D0 – on the day of injection, D1 – 1st day after injection, D7 – one week after injection, D28 – one month after injection, D90 – 3 months after injection

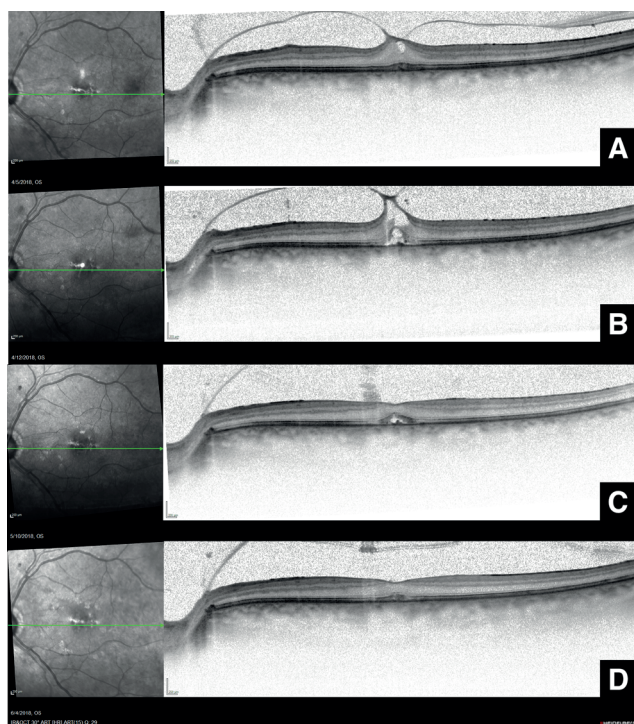


Figure 1. OCT sequence showing gradual vitreous detachment and normalization of neuroretinal stratification after pneumatic vitreolysis using C3F8 – (A) before intravitreal application, (B) one week after application, (C) 1 month after application, (D) 2 months after application

ANOVA method, the assumption of sphericity was tested by means of a Mauchly's sphericity test.

We did not find a statistically significant influence of the individual measurements over time on IOP, while the influence on BCVA was significant after applying correction of lack of sphericity by Greenhouse-Geisser epsilon (GGe) and Huynh-Feldt epsilon (HFe). We did not find a statistically significant influence of the group on BCVA or IOP depending on time, or an influence of time depending on the group. We did not find a statistically significant influence of the group on BCVA. We found a statistically significant influence of the group on IOP, which was significantly higher in the group of arterphakic eyes than in the group of phakic eyes. Paired t-tests with Bonferroni correction demonstrated a significant difference of BCVA between the follow-up examination on the 7th day and the follow-up examinations conducted on the 28th and 90th day after the procedure.

During the course of the observation period we did not observe any retinal tears, retinal detachment or endophthalmitis. Complete macular hole appeared in 2 eyes in our cohort after PVL, closing spontaneously within 1 month.

DISCUSSION

In our study we tested the safety and effectiveness of pneumatic vitreolysis using C3F8 gas. Our success rate in the disruption of VMT (71.4% after 28 days) roughly

corresponds to the results published in the new meta-analysis by Quiroz-Reyez et al. from 2023, who state an average degree of release of VMT of 46% using ocriplasmin, of 68% using gas, and of 100% using PPV [16]. The success rate of PVL can be influenced to a certain extent by the selection of patients according to the finding on OCT, which was published in 2013 by Rodrigues et al. They defined the following as predictive factors for a good anatomical response to treatment: maximum horizontal vitreomacular adhesion of less than 750 μm , maximum foveal thickness of less than 500 μm , and low reflectivity of the vitreous [2]. In eyes with all these characteristics, the anatomical success rate was 100% in their study. Chan et al. identified cellophane maculopathy and the presence of diabetes mellitus as negative prognostic factors for the success of the method. By contrast, in a one-dimensional analysis they demonstrated a higher success rate of eyes with the same or smaller scope of traction than the diameter of the optic nerve papilla, in eyes with stage 2 MH and in eyes not affected by diabetes [3]. In our cohort traction was not released in an eye with traction width of 255 μm and manifestations of non-proliferative diabetic retinopathy, and in an eye with traction width of 581 μm without associated diseases of the macula.

The success rate of PVL is also influenced by the type of expansive gas or sterile air. In a retrospective study, Steinle et al. recorded an 84% success rate in the treatment of VMT with the aid of C3F8 gas [17]. In a separate presentation, the same authors stated an 84% success rate with C3F8 gas, followed by 56% with SF6 gas and 48% with ocriplasmin in release of VMT in a comparative retrospective series of cases of treatment of VMT syndrome (Steinle et al., unpublished data, ARVO 2016, Seattle, May 2, 2016). In a prospective observation by Čokl et al. [18], C3F8 was demonstrated to be more effective in tractions with an adhesion width greater than 500 μm , while in a smaller scope the effect of both gases was comparable. Gruchociak et al. later compared the application of 0.3 ml of undiluted C3F8 gas and 0.3 ml of filtered air. Traction was released in a total of 11 eyes out of 24 one month after application, of which 7 out of 11 with application of C3F8 (64%) and 3 out of 13 with application of air (23%). This difference was statistically significant [19].

The influence of phakia on the success rate in release of VMT has not been entirely demonstrated to date. Data from studies with the use of ocriplasmin show a higher probability of successful release of VMT in phakic eyes than in arterphakic eyes [20,21]. In the case of PVL, no unequivocal results have been published. Although Day et al. published a cohort of 9 eyes, in which 5 were phakic (55.6%), recording that VMT was disrupted in 80% of the phakic eyes and only in 20% of the arterphakic eyes, this result was not statistically significant [7]. Claus et al. achieved release in all 3 arterphakic eyes, while by contrast release of VMT was not achieved in 3 out of 17 phakic eyes [9]. Gruchociak et al and Steinle et al. achieved comparable results in phakic and arterphakic eyes (Steinle 89% vs. 75%, $p = 0.3173$)

[17,19]. Baumann et al. in their study from 2022 were the first to record a statistically significant difference in favor of arterphakic eyes. release of traction was achieved in 100% of arterphakic eyes (10/10) and in only 67.6% of phakic eyes (25/37, $p = 0.03$) [22]. In our cohort, in contrast with the majority of previous study there was a predominance of arterphakic eyes. There were only 7 phakic eyes out of 21, in 6 of which traction was released (86%), of the remaining 14 arterphakic eyes traction was released in 13 (93%). We did not record a statistically significant difference.

It is evident from the observed studies that changes of BCVA in eyes after PVL tend to be small. Rodrigues et al. did not observe any improvement of average BCVA in their study. However, in the case of risk of deterioration of vision due to untreated vitreomacular traction, stabilization of visual acuity may be a sufficiently good result [2]. Neffendorf et al. in their literary synthesis state an average improvement of visual acuity following successful PVL by approximately 1 row on a Snellen chart. They further assume that this change need not fully do justice to the potential symptomatic benefit attained in this group of patients, with regard to the fact that the rectification of metamorphopsia may be at least as important as an improvement of visual acuity [23]. In patients with a basic diagnosis of MH, a greater improvement of BCVA is stated in comparison with those with isolated VMT [19,23] and the same was demonstrated in therapy with ocriplasmin and PPV [24].

With regard to adverse events in connection with PVL, until recently it appeared that it was a very safe method with a minimum of complications in the form of progression of VMT to MH, the onset of retinal tears, retinal detachment or the occurrence of endophthalmitis. However, recently a number of studies have appeared which have partially altered our view of PVL as a good method of first choice due to its effectiveness, safety, and lower financial cost in comparison with PPV.

In 2022 Baumann et al published a retrospective series of 47 eyes with VMT or VMT with MD up to a diameter of 400 μm , in which they performed PVL with C3F8. However, in their cohort 12 out of 33 eyes (36.4%) in the group of isolated VMT and 10 out of 14 eyes (71.4%) in the group with MH underwent vitrectomy after 1 month of observation. The reason was failure to release VMT (6 out of 33), the appearance of a new MH (in 4 of the 33 eyes with VMT), failure to close MH after application (10 out of 14), widening of the original MH, and retinal detachment (in 4 out of 47 eyes, 8.5%) [22]. In comparison with a meta-analysis conducted by Giny et al. from 2016 [8], Baumann et al. observed a larger number of newly occurring MH (12% vs. 4.1%), which in all cases were classified as large MH (more than 555 μm in diameter). At the same time, a markedly higher incidence of retinal detachment was also identified (8.5% vs. 0%).

These results correspond to the observations from the DRCR Retina Network protocols AG and AH published in 2021, in which retinal detachment or retinal cracks appeared in 12% of eyes within 24 weeks, which caused concerns regarding safety in the use of PVL in order to release VMT, and was the reason for premature termination of the study [25].

Our results in terms of adverse events do not correspond with these observations, which may be an error caused by the small size of the cohort.

CONCLUSION

Pneumatic vitreolysis by intravitreal injection of C3F8 gas represents an effective and cheap variant for the solution of symptomatic vitreomacular traction. The incidence of severe adverse side effects in our cohort was markedly lower than in recently published cohorts. It is necessary to choose the method of solution according to the parameters of adhesion, MH and associated ocular pathologies.

REFERENCES

1. Duker JS, Kaiser PK, Binder S, et al. The international vitreomacular traction study group classification of vitreomacular adhesion, traction, and macular hole. *Ophthalmology* 2013 December;120(12):2611-2619. <https://doi.org/10.1016/j.ophtha.2013.07.042>
2. Rodrigues IA, Stangos AN, McHugh DA, Jackson TL. Intravitreal injection of expansile perfluoropropane (C3F8) for the treatment of vitreomacular traction. *Am J Ophthalmol* 2013;155(2):270-276. <https://doi.org/10.1016/j.ajo.2012.08.018>
3. Chan CK, Mein CE, Crosson JN. Pneumatic vitreolysis for management of symptomatic focal vitreomacular traction. *J Ophthalmic Vis Res* 2017 October;12(4):419-423. https://doi.org/10.4103/jovr.jovr_146_17
4. Hikichi T, Yoshida A, Trempe CL. Course of vitreomacular traction syndrome. *Am J Ophthalmol* 1995 January;119(1):55-61. [https://doi.org/10.1016/s0002-9394\(14\)73813-9](https://doi.org/10.1016/s0002-9394(14)73813-9)
5. John VJ, Flynn HW, Smiddy WE, et al. Clinical course of vitreomacular adhesion managed by initial observation. *Retina* 2014 March;34(3):442-446. <https://doi.org/10.1097/IAE.0b013e3182a15f8b>
6. Chan CK, Crosson JN, Mein CE, Daher N. Pneumatic vitreolysis for relief of vitreomacular traction. *Retina* 2017 October;37(10):1820-1831. <https://doi.org/10.1097/IAE.0000000000001448>
7. Day S, Martinez JA, Nixon PA, et al. Intravitreal sulfur hexafluoride injection for the treatment of vitreomacular traction syndrome. *Retina* 2016 April;36(4):733-737. <https://doi.org/10.1097/IAE.0000000000000760>
8. Yu G, Duguay J, Marra K V, et al. Efficacy and safety of treatment options for vitreomacular traction: A Case Series and Meta-Analysis. *Retina* 2016 July;36(7):1260-1270. <https://doi.org/10.1097/IAE.0000000000000909>
9. Claus MG, Feron E, Veckeneer M. Pneumatic release of focal vitreomacular traction. *Eye (Basingstoke)* 2017 March;31(3):411-416. <https://doi.org/10.1038/eye.2016.231>
10. Kaiser PK, Kampik A, Kuppermann BD, et al. Safety profile of ocriplasmin for the pharmacologic treatment of symptomatic vitreomacular adhesion/traction. *Retina* 2015 June;35(6):1111-1127. <https://doi.org/10.1097/IAE.0000000000000448>
11. Chan CK, Wessels IF, Friedrichsen EJ. Treatment of idiopathic macular holes by induced posterior vitreous detachment. *Ophthalmology* 1995 May;102(5):757-767. [https://doi.org/10.1016/s0161-6420\(95\)30958-x](https://doi.org/10.1016/s0161-6420(95)30958-x)
12. Costa RA, Cardillo JA, Morales PH, et al. Optical coherence tomography evaluation of idiopathic macular hole treatment by gas-assisted posterior vitreous detachment. *Am J Ophthalmol* 2001 August;132(2):264-266. [https://doi.org/10.1016/S0002-9394\(00\)00903-X](https://doi.org/10.1016/S0002-9394(00)00903-X)
13. Jorge R, Costa RA, Cardillo JA, et al. Optical Coherence Tomogra-

- phy Evaluation of Idiopathic Macular Hole Treatment by Gas-assisted Posterior Vitreous Detachment. *Am J Ophthalmol* 2006 November;142(5):869-871. <https://doi.org/10.1016/j.ajo.2006.05.062>
14. Mori K, Saito S, Gehlbach PL, Yoneya S. Treatment of Stage 2 Macular Hole by Intravitreal Injection of Expansile Gas and Induction of Posterior Vitreous Detachment. *Ophthalmology* 2007 January;114(1):127-133. <https://doi.org/10.1016/j.ophtha.2006.07.001>
15. Veith M. Treatment of Vitreomacular Traction with Intravitreal Injection of Perfluoropropane. *Cesk Slov Oftalmol*. 2020 January;75(4):182-187. <https://doi.org/10.31348/2019/4/2>
16. Quiroz-Reyes MA, Quiroz-Gonzalez EA, Quiroz-Gonzalez MA, Lima-Gomez V. Pneumatic vitreolysis versus vitrectomy for the treatment of vitreomacular traction syndrome and macular holes: complication analysis and systematic review with meta-analysis of functional outcomes. *Int J Retina Vitreous* 2023 December;9(1):1-16. <https://doi.org/10.1186/s40942-023-00472-x>
17. Steinle NC, Dhoot DS, Quezada Ruiz C, et al. Treatment of vitreomacular traction with intravitreal perfluoropropane (C3F8) injection. *Retina* 2017 April;37(4):643-650. <https://doi.org/10.1097/IAE.0000000000001237>
18. Čokl N, Petrovič MG. Intravitreal injection of perfluoropropane is more efficacious than sulfur hexafluoride in releasing vitreomacular traction. *Acta Clin Croat* 2018;57(2):327-334. <https://doi.org/10.20471/acc.2018.57.02.14>
19. Gruchociak S, Djerada Z, Afriat M, et al. Comparing intravitreal air and gas for the treatment of vitreomacular traction. *Retina* 2020 November;40(11):2140-2147. <https://doi.org/10.1097/IAE.0000000000002733>
20. Haller JA, Stalmans P, Benz MS, et al. Efficacy of intravitreal ocriplasmin for treatment of vitreomacular adhesion: Subgroup analyses from two randomized trials. *Ophthalmology* 2015 January;122(1):117-122. <https://doi.org/10.1016/j.ophtha.2014.07.045>
21. Feng HL, Roth DB, Hasan A, et al. Intravitreal ocriplasmin in clinical practice: Predictors of Success, Visual Outcomes, and Complications. *Retina* 2018 January;38(1):128-136. <https://doi.org/10.1097/IAE.0000000000001505>
22. Baumann C, Sabatino F, Zheng Y, et al. Anatomical and functional outcomes of pneumatic vitreolysis for treatment of vitreomacular traction with and without macular holes. *Graefes Arch Clin Exp Ophthalmol* 2022 July;260(7):2209-2215. <https://doi.org/10.1007/s00417-022-05568-y>
23. Neffendorf JE, Simpson ARH, Steel DHW, et al. Intravitreal gas for symptomatic vitreomacular adhesion: a synthesis of the literature. *Acta Ophthalmol* 2018 November;96(7):685-691. <https://doi.org/10.1111/aos.13547>
24. Enzymatic Vitreolysis with Ocriplasmin for Vitreomacular Traction and Macular Holes. *N Engl J Med* 2012 November;367(21):2052-2054. <https://doi.org/10.1056/nejmc1211068>
25. Chan CK, Mein CE, Glassman AR, et al. Pneumatic Vitreolysis with Perfluoropropane for Vitreomacular Traction with and without Macular Hole: DRCR Retina Network Protocols AG and AH. *Ophthalmology* 2021 November;128(11):1592-1603. <https://doi.org/10.1016/j.ophtha.2021.05.005>