

EVALUATION OF CLINICAL RESULTS OF IMPLANTATION OF TORIC INTRAOCULAR LENSES INCLUDING THEIR ROTATIONAL STABILITY

Pašková Barbora^{1,2}, Marešová Klára^{1,2}, Schreiberová Zuzana^{1,2}, Malušková Miloslava^{1,2}, Karhanová Marta^{1,2}

¹University Hospital Olomouc, Department of Ophthalmology, Czech Republic

²Palacký University in Olomouc, Faculty of Medicine and Dentistry, Department of Ophthalmology, Czech Republic

The authors of the study declare that no conflict of interests exists in the compilation, theme and subsequent publication of this professional communication, and that it is not supported by any pharmaceuticals company. The authors further declare that study has not been submitted to any other journal or printed elsewhere, with the exception of congress abstracts.

Supported by a grant of Palacký University in Olomouc IGA_LF_2022_026 and Ministry of Health, Czech Republic – conceptual development of research organization (FNOI, 00098892).

Submitted to the editorial board: November 16, 2023

Accepted for publication: January 2, 2024

Available on-line: February 12, 2024



MUDr. Barbora Pašková, FEBO
LF UP a FN Olomouc
Zdravotníků 248/7
779 00 Olomouc
E-mail: barbora.paskova@fnol.cz

SUMMARY

Purpose: The aim of the study was to evaluate the clinical results of the implantation of the toric intraocular lens Acrysof IQ Toric SN6AT3_8 (Alcon Laboratories, Inc., Fort Worth, TX, USA), including an evaluation of its rotational stability.

Material and methods: 30 eyes of 16 patients (4 males, 12 females; mean age 68 years) with regular corneal astigmatism ranging from -1.5 to -4.0 Dcyl were included in this retrospective study. All the patients underwent uncomplicated cataract surgery with the implantation of a toric intraocular lens (TIOL) at the Department of Ophthalmology of the Faculty of Medicine and Dentistry of Palacký University in Olomouc and University Hospital Olomouc during the course of 2020. Follow-up examinations were performed 3–6 months after cataract surgery. We monitored the resulting uncorrected distance visual acuity (UDVA), postoperative refraction, rotational stability of the implanted lens and subjective patient satisfaction.

Results: mean preoperative corneal astigmatism was -2.41 ± 0.67 Dcyl. UDVA improved from a mean value of 0.45 ± 0.25 (expressed in decimal Snellen optotype values) to 0.91 ± 0.16 . The spherical equivalent value of 0.41 ± 0.92 improved to -0.11 ± 0.27 postoperatively. The mean deviation from the planned axis was 4.87 ± 4.75 . Subjective satisfaction was rated by patients on a scale of 1–5, with a mean score of 1.5.

Conclusion: TIOL implantation is a safe and effective solution for patients with corneal astigmatism and cataract. Our results demonstrate improved UDVA, rotational stability of the TIOL and subjective patient satisfaction with the outcome of the surgery.

Key words: cataract surgery, astigmatism, toric intraocular lens, rotational stability

Čes. a slov. Oftal., 80, 2024, No. x, p.

INTRODUCTION

Cataract surgery ranks among the most frequent intraocular surgical procedures. The worldwide trend is to operate on ever younger patients with increased demands for resulting postoperative central visual acuity (CVA) and the minimum possible dependency on glasses correction. In the choice of intraocular lens it is therefore desirable to focus not only on spherical but also astigmatic defects. A mild degree of astigmatism (0.25 DCyl) is a relatively common refractive error. Values greater than 1.0 DCyl are present in approximately 20% of the population, and

values greater than 2.0 DCyl are present in 5–10% of the population. In patients with cataract the incidence of astigmatism of ≥ 1.5 DCyl is stated at 15 to 29% of the population [1,2]. In the case of the presence of corneal astigmatism and appropriate patient motivation, it is possible to resolve a spherical and astigmatic refractive error in a single procedure, namely by means of implantation of a toric monofocal intraocular lens (TIOL). At present we have a wide selection of TIOLs available, an example of which is the intraocular lens Acrysof IQ Toric SN6AT3_8 (Alcon Laboratories, Inc., Fort Worth, TX, USA). Its main advantages are the stabilization mechanism open loop haptics,

integrated filter for blocking phototoxic blue light and the possibility of an access incision of 2.2 mm. Upon implantation of a TIOL it is essential to ensure careful performance of biometry, precise marking of the axis and final rotation of the lens into the required position. Even despite a problem-free course of the operation and precise implantation of the TIOL in the predetermined axis, postoperative rotation may occur, with a negative influence on resulting CVA. Postoperative rotation of the TIOL most often takes place immediately after surgery [3,4]. In order to achieve maximum rotational stability it is very important to ensure the complete removal of the viscoelastic material from the capsular sac [5], as well as to ensure that the patient is physically at rest in the first hours after surgery.

The aim of our study was to evaluate the clinical results of implantation of this TIOL, including its rotational stability. We also focused on subjective patient satisfaction following implantation.

MATERIAL AND METHOD

Design of study and characteristics of cohort

We retrospectively evaluated a total of 30 eyes of 16 patients who underwent uncomplicated cataract surgery with implantation of a TIOL at the Department of Ophthalmology at the University Hospital in Olomouc. The average age of the patients (4 men, 12 women) was 68 years (range 41–75 years). The baseline criterion was presence of cataract and corneal astigmatism of ≥ 1.5 Dcyl, as well as patient motivation. The exclusion criteria were irregular corneal astigmatism, condition following refractive laser surgery, complicated cataract surgery, corneal dystrophy, glaucoma pathology or pathology of the macula.

Preoperative examination

Uncorrected distance visual acuity (UDVA) was examined preoperatively in all the patients with the aid of Snellen charts (the results are presented in decimal values of Snellen rows). Intraocular pressure was measured with the aid of a non-con-

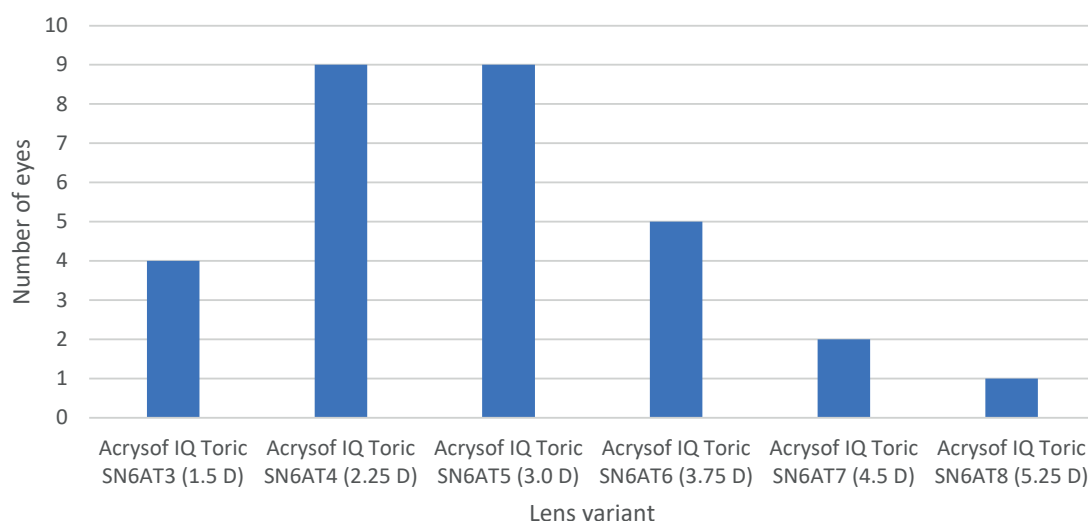
tact tonometer (Canon TX-20P), refraction and keratometry were examined (Nidek ARK-1a), an ophthalmological examination of the anterior and posterior segment was performed in artificial mydriasis on a slit lamp, and biometry was measured (IOLMaster, Carl Zeiss Meditec AG) with the use of the SRK/T formula. The optical density of the TIOL was selected according to the results of biometry. For calculation of the TIOL we used an available online calculator recommended by the manufacturer of the lenses (www.myalcon.cz). The variant Acrysof IQ Toric SN6AT3_8 was subsequently chosen, which led to the lowest refractive deviation.

Surgical technique

All operations were performed by two experienced surgeons, in which circular capsulorhexis, phacoemulsification, irrigation/aspiration and implantation of an Acrysof IQ Toric SN6AT3_8 into the sac with rotation to a predetermined axis were performed under local topical anesthesia, with a temporal incision of the size of 2.2 mm. The models SN6AT3_8 correct regular corneal astigmatism from 1.5 D to 5.25 D. The individual representation of variants of lenses is summarized in Graph 1. The axis was indicated preoperatively by two methods: First of all manually in artificial mydriasis under a slit lamp. In the eye prepared for the surgery, toric markings were placed on the limbus with a marker. The angle of rotation was determined with the aid of the angled beam and the scale on the slit lamp (Fig. 1). The Verion navigation system was subsequently used without inducing artificial mydriasis. In order to create the operating plan, a digital mark was created on the eye, and according to the scanned blood vessels, the system subsequently projected the navigation marks and lines onto the operated eye into a surgical microscope (Fig. 2). Postoperatively the patients remained in a stationary position for at least one hour. They were then given detailed instructions with regard to the necessity of a regimen of physical rest.

Postoperative results

The patients were invited to attend a follow-up examina-



Graph 1. Representation of the Acrysof IQ Toric lens variant in the file

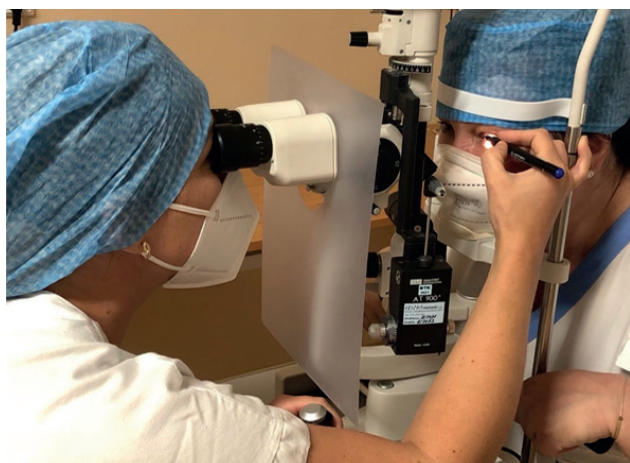


Figure 1. Preoperative manual axis marking in a patient seated behind a slit lamp

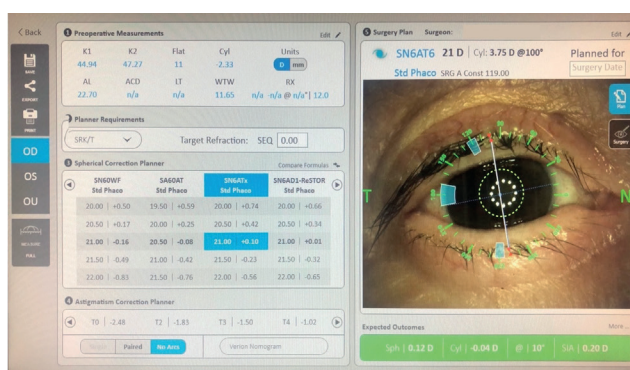


Figure 2. Preoperative axis marking using the VERION navigation system

tion 3–6 months after cataract surgery. Postoperatively we monitored UDVA, postoperative refraction, keratometry, position, rotational stability of the implanted lens and subjective patient satisfaction. Artificial mydriasis was induced in order to determine the rotational stability of the TIOL, and we read the position of the lens with the aid of the angle of the beam on the slit lamp. In order to determine subjective patient satisfaction we used a questionnaire that contained 5 questions relating to patient satisfaction following the implantation of the TIOL. The questions were targeted at satisfaction with distance vision without correction, and the presence of photic phenomena. Subjective satisfaction was rated by patients on a scale of 1–5, on which the following applied: Score 1 – satisfied, no complaints; score 2 – satisfied, minor complaints that are not disruptive; score 3 – dissatisfied, complaints that are disruptive; score 4 – dissatisfied, complaints that are unacceptable for me; score 5 – explantation performed due to dissatisfaction.

Statistical analysis

The statistical software IBM SPSS Statistics version 23 (Armonk, NY: IBM Corp.) was used for the analysis of data. A Wilcoxon signed-rank test or paired Student's t-test was used for the comparison of the quantitative parameters measured

before and after surgery, depending on the normality of the data. A Shapiro-Wilk test was used for verification of normal distribution. Spearman's rank correlation coefficients were calculated in order to assess dependencies. The concordance between the measurements of keratometry (Nidek ARK-1a and Zeiss IOLMaster), or the concordance between the axis of implantation and the resulting axis was assessed with the aid of an ICC coefficient. The division of negative and positive deviations from the planned axis (rotation in a clockwise and anticlockwise direction) was compared with even distribution with the aid of a Chi-squared test. All the tests were performed on a level of significance of 0.05.

RESULTS

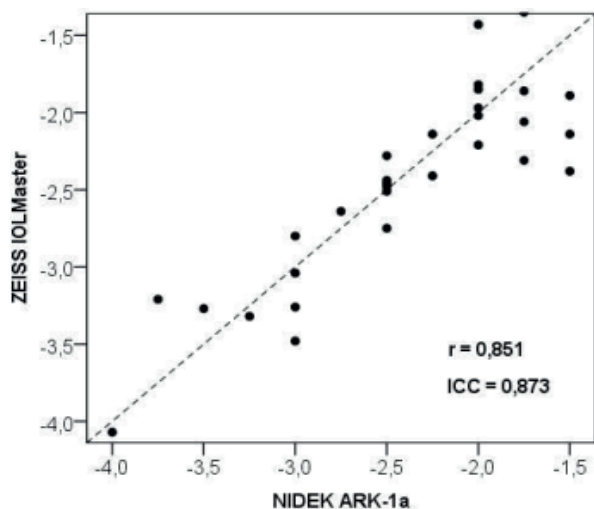
The mean value of preoperative corneal astigmatism was -2.41 ± 0.67 Dcyl (Nidek ARK-1a). Upon measurement of biometry, the mean value of corneal astigmatism was -2.46 ± 0.67 DCyl (IOLMaster, Carl Zeiss Meditec AG). No significant difference was demonstrated between the keratometry values obtained with the aid of the two instruments Nidek ARK-1a and IOLMaster ($p = 0.380$). The value of the Spearman's rank correlation coefficient of $r = 0.873$ attests to a high correlation (Graph 2).

UDVA improved after surgery from a mean value of 0.45 ± 0.25 (expressed in decimal values) to a value of 0.91 ± 0.16 . A statistically significant improvement of postoperative UDVA was achieved ($p < 0.0001$). The value of spherical equivalent (SE) of 0.41 ± 0.29 improved postoperatively to -0.11 ± 0.27 . The spherical value changed from 0.31 ± 0.01 D to 0.01 ± 0.30 D.

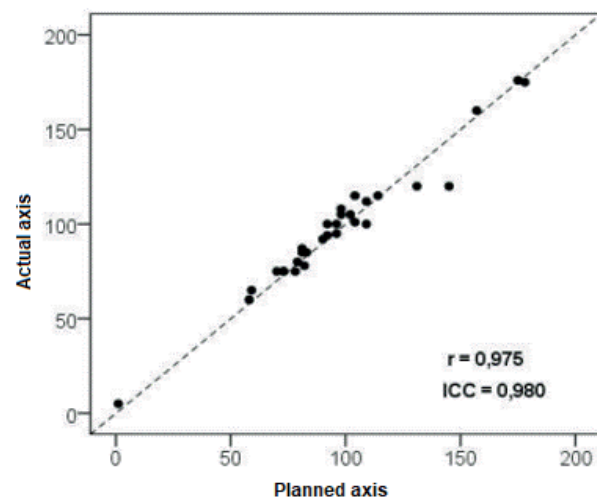
The mean deviation from the planned axis was $4.87 \pm 4.75^\circ$ (minimum 0° , maximum 25°). No significant difference was demonstrated between the axis of implantation and the resulting axis ($p = 0.075$). The Spearman's rank coefficient for correlation between the axis of implantation and the resulting axis of $r = 0.975$ attests to a very high correlation. The value of the ICC coefficient = 0.980 attests to a high level of concordance (Graph 3). Rotation in a clockwise direction occurred in 73.3% of cases, and in an anticlockwise direction in 26.7% of cases. Upon a comparison of positive and negative deviations from the planned axis with an even distribution, no significant difference was demonstrated ($p = 0.063$) (Graph 4).

Mean residual refraction following implantation of a TIOL measured by the instrument Nidek ARK-1a was -0.52 ± 0.49 DCyl. In comparison with preoperative corneal keratometry of -2.4 ± 0.68 DCyl measured by Nidek ARK-1a, a significant reduction of values was attained ($p < 0.0001$) (Graph 5).

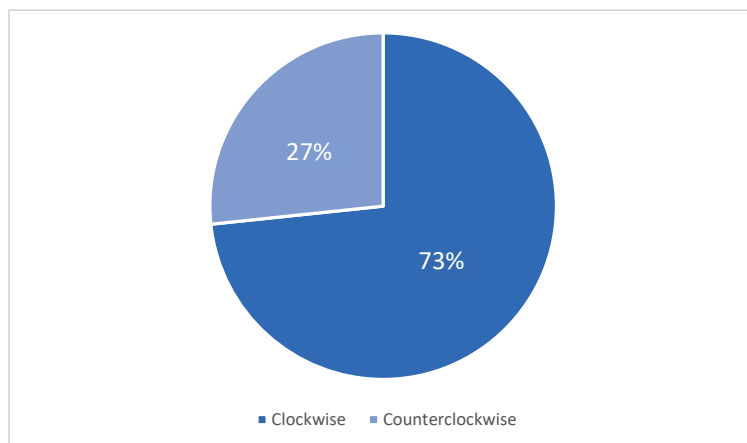
Subjective patient satisfaction was evaluated on a scale of 1–5. The average score was 1.5 (Table 1). In a targeted question relating to pseudophakic dysphotopsia, 20 eyes had no complaints (score 1), while mild complaints (score 2) were described in 5 eyes, and we recorded complaints which patients found disruptive (score 3) in 5 eyes. In the group with a score of 3 the patients stated negative dysphotopsia in 4 eyes, and in 1 eye the patient stated a disruptive impression of glare type.



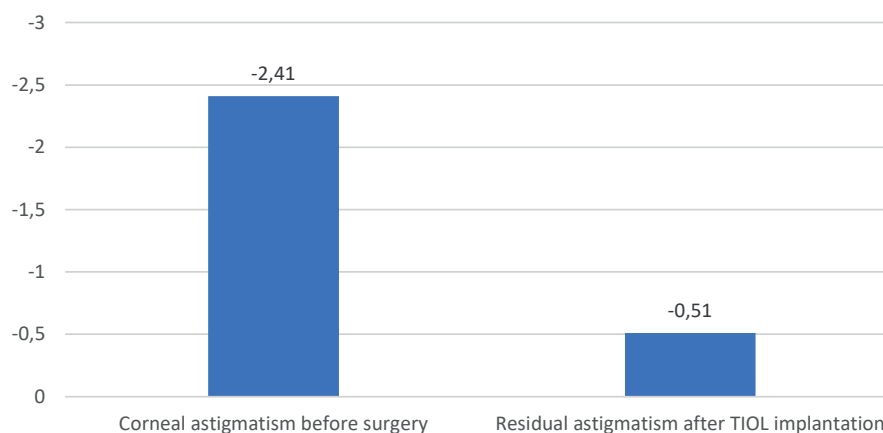
Graph 2. Comparison of keratometry measurements of two instruments Nidek ARK-1a and Zeiss IOLMaster
ICC – Interclass Correlation Coefficient, r – Spearman's rank correlation coefficient



Graph 3. Comparison of the planned implantation axis and the actual TIOL axis
TIOL – toric intraocular lens, ICC – Interclass Correlation Coefficient, r – Spearman's rank correlation coefficient



Graph 4. Percentage of the direction of rotation of the implanted TIOL
TIOL – toric intraocular lens



Graph 5. Comparison of preoperative corneal astigmatism and residual postoperative astigmatism
TIOL – toric intraocular lens

DISCUSSION

A key parameter for implantation of a TIOL is the pre-operative value of corneal astigmatism. According to the literature, it is recommended to correct values of astigmatism of ≥ 1 DCyl [6,7]. In order to attain the most precise possible postoperative result, it is appropriate to measure keratometry on two different instruments. In our observation we obtained the values of astigmatism with the aid of the automatic keratometer Nidek ARK-1a and the optic biometer IOLMaster. We did not demonstrate a significant difference between the measured values ($p = 0.380$). In any case, we certainly recommend performance of the measurements on both instruments. However, should a significant difference between the values of corneal astigmatism be recorded in any patient, it is appropriate to focus on a potential disorder of the stability of the tear film. In a study conducted by Rögglä V. et al. [8], the value of astigmatism changed by more than 0.5 DCyl in 34.4% of eyes following the application of artificial tears.

In our cohort we also evaluated an improvement of SE from 0.41 ± 2.92 to -0.11 ± 0.27 and a change of spherical diopters from 0.31 ± 2.01 D to 0.01 ± 0.30 D. These results are also confirmed by postoperative UDVA, which was ≥ 0.63 in 100% of patients. An analogous effect is described in the literature, in which CVA of ≥ 0.5 is attained in 70–100% of patients following implantation of a TIOL [4,9]. Holland et al. [10] in their study compared the results of implantation of a toric Acrysof IOL and its non-toric variant in values of astigmatism of ≥ 0.75 DCyl, in which 92.2% with a TIOL had UDVA of ≥ 0.5 , as against 81.4% with the non-toric variant of the lens.

An uncomplicated course of the operation is a fundamental prerequisite for the correct positioning of the TIOL and for minimizing the possibility of decentration. When marking the toricity axis it is recommended that the patient is in a sitting position in order to prevent cyclotorsion. The study conducted by Ciccio A.E. et al. [11] describes cyclotorsion from 0.5° to 17.5° , with a mean value of 4.05° . Upon manual marking, the deviation from the planned axis is within a range up to 4.9° [12]. An indisputable advantage of this method is that it is undemanding in terms of equipment. The risks include washing out or expansion of the ink mark during the operation, and subsequent imprecision in the implantation of the TIOL. On the other hand, it is possible to make use of the image perioperatively with the aid of navigation systems, not only for the final centration

of the lens, but also in the location of the access incisions and displaying the size of capsulorhexis. In our study we used both systems of marking the axis.

The diameter of capsulorhexis should be 0.5 mm smaller than the optic part of the lens. The diameter of the optic part of the Acrysof IQ Toric lens is 6 mm, and therefore the optimal size of capsulorhexis is 5.5 mm. Excessively small capsulorhexis may have an adverse impact on the contraction of the capsule and subsequent undesirable rotation of the TIOL [13,14]. Implantation of a TIOL is especially difficult in patients with insufficiently induced mydriasis, which we encounter for example in patients with diabetes mellitus or perioperative development of IFIS (Intraoperative Floppy Iris Syndrome) [15]. A characteristic trait in patients with IFIS is the development of a perioperative triad: an unstable “fluttering” iris, insufficiently wide pupil, and progressive myosis with a tendency towards prolapse of the iris into the corneal incisions [16]. A narrow pupil prevents the possibility of performing optimal capsulorhexis, and reduces the visualization of the toric marks located in the periphery of the optics of the TIOL, which may subsequently lead to incorrect rotation of the intraocular lens [15]. In order to induce greater mydriasis and thereby attain better visualization of the posterior pole, it is generally recommended to administer 0.2 mg/ml adrenaline, or viscoelastic material with a high hyaluronic acid content into the anterior chamber, to patients with the development of IFIS. It is possible to expand the pupil manually with the aid of pupil expanders. Another variant is iris hooks, which we can furthermore align into the relevant axis of astigmatism and thereby attain a more precise location of the TIOL [17]. Although insufficiently induced mydriasis in these patients is considered a risk factor in the adequate placing of the TIOL, it is not unequivocally regarded as a contraindication in the implantation of toric lenses. It has not yet been confirmed by any study as to whether perioperative development of IFIS can influence the resulting stability of the TIOL. Patients with congenital or acquired zonulopathy are absolutely unsuitable candidates for implantation of a TIOL. A relative contraindication is corneal scars causing irregular astigmatism, which may not be fully eliminated by the implantation of a TIOL. It is also necessary to consider TIOL carefully for patients with a diagnosed retinal pathology, corneal dystrophy, glaucoma or uveitis, in whom the resulting CVA may not be satisfactory with reference to the primary diagnosis [18]. We took all these factors into account in our study in the

Table 1. Patient satisfaction questionnaire after TIOL implantation

Satisfaction rating	Number of patients
1 satisfied, no difficulties	20
2 satisfied, I have a mild discomfort that doesn't bother me	5
3 dissatisfied, I have difficulties that bother me	5
4 dissatisfied, I have difficulties that cannot be accepted	0
5 explantation performed due to dissatisfaction	0

TIOL – toric intraocular lens

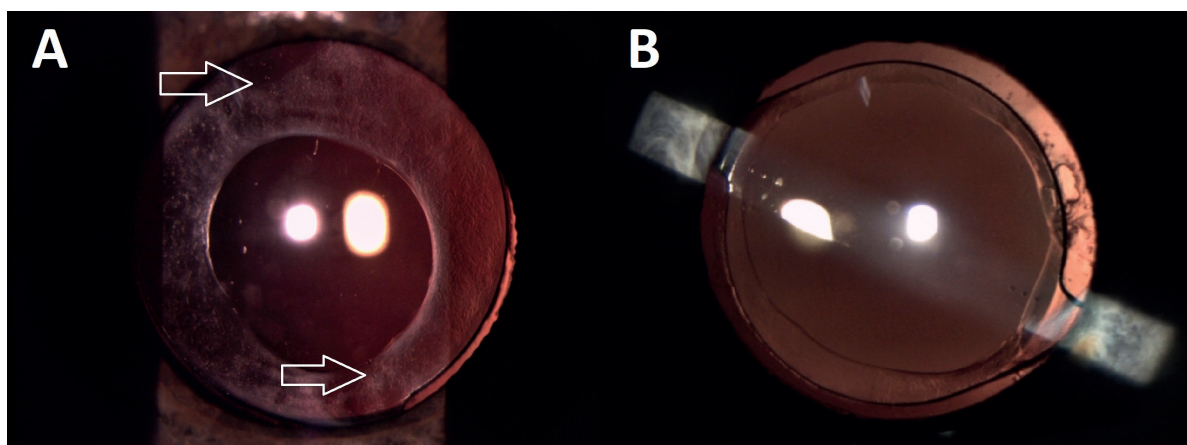


Figure 3. (A) Less visible markers of toricity (arrows) in smaller capsulorhexis, (B) Very good visibility of toricity markers

exclusion criteria. Nevertheless, it is necessary to be aware that it is precisely in patients with another ocular pathology, which may influence visual functions, that correction of a toric error has a significant impact on resulting visual acuity and patient satisfaction. Another significant factor in the careful consideration of implantation of a TIOL is evaluation of the alpha angle. In the case that it is greater than 0.5 mm, the development of postoperative refractive surprise may occur to a greater extent [19,20]. However, we did not examine the alpha (or kappa) angle in our cohort.

The core part of our study was a comparison of the rotational stability of the lens. We did not demonstrate a significant difference between the axis of implantation and the resulting axis, which is an ideal postoperative state. This especially concerns the results of precise work of the operating surgeon, as well as good stability of the IOL. In our cohort the mean deviation from the planned axis was 4.87°. Similar results are shown by the study conducted by Miyake et al. [4], in which rotation was less than 5° in 76.7% of eyes 2 years after cataract surgery. The postoperative position of the TIOL may be influenced by several factors. An important role is played also by the type and material of the lens. The basic types of TIOL haptics include plate and loop. In plate type haptics a total and symmetrical connection of the sac takes place within two weeks, which leads to lesser rotation in the later postoperative period. In lenses with a loop haptic design, asymmetrical fusion takes place in a clockwise direction, and later rotation of the lens is more common [21]. Postoperative rotation of a TIOL by more than 10° most often occurs within 10 days of cataract surgery [4]. Hydrophobic acrylate TIOLs manifest high rotational stability, in which adhesion is generated between the posterior capsule and the lens. Weinand et al. [22] state that the average postoperative rotation was 0.9–1.8° at 6 months after the implantation of an acrylate TIOL. A similar study was conducted also by Koshy et al. [23], in which postoperative rotation was 2.7 ± 2.0°. Kwartz et al. [24] state mean postoperative rotation of 2–3° at 2 years after cataract surgery. With regard

to the direction of postoperative rotation of the Acrysof IQ Toric lens, there is no clear statement in the literature as to whether rotation takes place clockwise [4,25], anticlockwise [26], or if it occurs at all [27]. In the study by Shah GD et al. [28], rotation occurred in a clockwise direction in 76.2% of cases and in an anticlockwise direction in 28.3% of cases. We attained the same results also in our own study, in which there was a tendency of clockwise rotation of the TIOL in 73.3% of cases.

Rotation of a TIOL and deviation from the axis may have a negative influence on quality of vision. It has been demonstrated that rotation of the lens by 10° reduces the effect of toricity by 1/3, rotation by 20° reduces the toricity effect by 2/3 and rotation by 30° entirely cancels out the corrective effect [29]. Deviation by 5° is acceptable, and the limit for surgical revision is a deviation of 10° [10]. In our cohort rotation by more than 10° occurred in 2 cases, in which the maximum value of deviation from the axis was 25°. In this case an Acrysof IQ Toric SN6T3 lens was implanted, which means lower cylindrical correction. Postoperatively UDVA was 1.0 and subjective patient satisfaction was high, with a score of 1. In the second case rotation from the axis was recorded at 11°, with UDVA of 1.0 and also with high patient satisfaction. With reference to the excellent postoperative UDVA and high patient satisfaction, we did not indicate surgical rotation or explantation of the lens in either case. The resulting axis may be influenced among other factors by imprecise preoperative marking and/or postoperative reading of the position. Monitoring of the position of the TIOL can be performed in artificial mydriasis under a slit lamp. Limiting factors are: imprecise reading of the value on the scale, incorrect head position of the patient, as well as imperfect visualization of the toricity markers in small capsulorhexis and phimosis of the anterior capsule (Fig. 3). Today other, more precise methods are now available, such as photography of the anterior segment and subsequent analysis in software created for comparing the planned and resulting axis of toricity.

Residual refractive error and residual astigmatism may have an influence on resulting patient satisfaction and

worse CVA. The causes of origin may vary, from imprecisely performed biometric examination [30] to positional error of the TIOL. In the study conducted by Bauer NJ et al. [31], the value of residual astigmatism following the implantation of an Acrysoft IQ Toric lens was ≤ 1.00 DCyl in 91% of eyes. These results are also confirmed by our study, in which the value of postoperative residual astigmatism was -0.52 ± 0.49 DCyl. Residual refraction of -0.75 DCyl is usually still well tolerated by the patient. In the case of appearance of disruptive deviations from the emmetropic plan, it is appropriate to consider the supplementing of laser corneal refractive surgery [32].

The last examined parameter was subjective patient satisfaction. According to the literature it generally applies that patients with an implanted monofocal TIOL are highly satisfied [9]. Postoperative patient satisfaction may be influenced by the occurrence of negative dysphotopsias. Patients with an implanted Acrysoft IQ Toric lens state a lower frequency of postoperative glare in comparison with the group of patients who underwent a corneal relaxation incision [33]. Positive dysphotopsias are 3.5 times more frequent following the implantation of multifocal intraocular lenses [34]. Their intensity and frequency is reduced

over the course of time thanks to neuroadaptation. In our cohort of 30 eyes, high patient satisfaction with a score of 1 was recorded in 66.7% of eyes.

A weakness of our study is the fact that the operations were performed by two surgeons. Nevertheless, these were highly experienced operating surgeons (KM, IŠ). Another weakness of the study is the fact that we did not evaluate best corrected visual acuity (BCVA) before and after cataract surgery. This was a retrospective study, and this data was unfortunately not available for all of the patients.

CONCLUSION:

Based on our experience, implantation of a TIOL is a safe and effective solution for patients with corneal astigmatism and cataract. The presented results document an improvement of UDVA, rotational stability of the TIOL and subjective patient satisfaction with the result of the operation.

Acknowledgements

Irena Šínová, MD, PhD, FEBO who together with Klára Marešová, MD, PhD, FEBO operated on the patients included in the study.

REFERENCES

- Maedel S, Hirschschall N, Chen YA, Findl O. Rotational performance and corneal astigmatism correction during cataract surgery: aspheric toric intraocular lens versus aspheric nontoric intraocular lens with opposite clear corneal incision. *J Cataract Refract Surg*. 2014;40(8):1355-1362.
- Břešťák M, Mašek P, Pašta J. 60 let nitrooční čočky. *Oftalmologie*. Hradec Králové: Nucleus HK;2010.130.
- Inoue Y, Takehara H, Oshika T. Axis Misalignment of Toric Intraocular Lens: Placement Error and Postoperative Rotation. *Ophthalmology*. 2017;124(9):1424-1425.
- Miyake T, Kamiya K, Amano R, Iida Y, Tsunehiro S, Shimizu K. Long-term clinical outcomes of toric intraocular lens implantation in cataract cases with preexisting astigmatism. *J Cataract Refract Surg*. 2014;40(10):1654-1660.
- Horn JD. Status of toric intraocular lenses. *Curr Opin Ophthalmol*. 2007;18(1):58-61.
- Mendicute J, Irigoyen C, Aramberri J, Ondarra A, Montés-Micó R. Foldable toric intraocular lens for astigmatism correction in cataract patients. *J Cataract Refract Surg*. 2008;34(4):601-607.
- Statham M, Apel A, Stephensen D. Comparison of the AcrySof SA60 spherical intraocular lens and the AcrySof Toric SN60T3 intraocular lens outcomes in patients with low amounts of corneal astigmatism. *Clin Exp Ophthalmol*. 2009;37(8):775-779.
- Röggla V, Leydolt C, Scharthmüller D, et al. Influence of Artificial Tears on Keratometric Measurements in Cataract Patients. *Am J Ophthalmol*. 2021;221:1-8.
- Lubiński W, Kaźmierczak B, Gronkowska-Serafin J, Podborczyńska-Jodko K. Clinical Outcomes after Uncomplicated Cataract Surgery with Implantation of the Tecnis Toric Intraocular Lens. *J Ophthalmol*. 2016;2016:3257217.
- Holland E, Lane S, Horn JD, Ernest P, Arleo R, Miller KM. The AcrySof Toric intraocular lens in subjects with cataracts and corneal astigmatism: a randomized, subject-masked, parallel-group, 1-year study. *Ophthalmology*. 2010;117(11):2104-2111.
- Ciccio AE, Durrie DS, Stahl JE, Schwendeman F. Ocular cyclotorsion during customized laser ablation. *J Refract Surg*. 2005;21(6):S772-S774.
- Visser N, Berendschot TT, Bauer NJ, Jurich J, Kersting O, Nuijts RM. Accuracy of toric intraocular lens implantation in cataract and refractive surgery. *J Cataract Refract Surg*. 2011;37(8):1394-1402.
- Elmohamady MN, Elhabbak A, Gad EA. Circular YAG laser anterior capsulotomy for anterior capsule contraction syndrome. *Int Ophthalmol*. 2019;39(11):2497-2503.
- Singh A, Kapoor G, Baranwal VK, Kalra N. Rotational stability of Toric intraocular lenses. *Med J Armed Forces India*. 2022;78(1):68-73.
- Brožová M. Trendy soudobé oftalmologie, svazek 12. Praha (Česká Republika): Galén; 2019. Multifokální nitrooční čočky-typy a indikace; p. 13-35.
- Chang DF, Campbell JR. Intraoperative floppy iris syndrome associated with tamsulosin. *J Cataract Refract Surg* 2005;31:664-663.
- Ganesh S, Brar S, Chakma A. A new intraocular lens marker to guide the implantation of toric intraocular lenses in small and mid-dilating pupils. *Indian J Ophthalmol*. 2023;71(5):2251-2253.
- Singh VM, Ramappa M, Murthy SI, Rostov AT. Toric intraocular lenses: Expanding indications and preoperative and surgical considerations to improve outcomes. *Indian J Ophthalmol*. 2022;70:10-23.
- Park CY, Oh SY, Chuck RS. Measurement of angle kappa and centration in refractive surgery. *Curr Opin Ophthalmol*. 2012;23:269-275.
- Piracha AR. Using angle alpha in premium IOL screening. *Cataract Refract Surg Today*. 2016;3:24-25.
- Mallias I, Mylova P, Tassiopoulou A. Correction of astigmatism with toric intraocular lenses. *Ophthalmology Journal*. 2017;2:49-53.
- Weinand F, Jung A, Stein A, Pfützner A, Becker R, Pavlovic S. Rotational stability of a single-piece hydrophobic acrylic intraocular lens: new method for high-precision rotation control. *J Cataract Refract Surg*. 2007;33(5):800-803.
- Koshy JJ, Nishi Y, Hirschschall N, et al. Rotational stability of a single-piece toric acrylic intraocular lens. *J Cataract Refract Surg*. 2010;36(10):1665-1670.
- Kwartz J, Edwards K. Evaluation of the long-term rotational stability of single-piece, acrylic intraocular lenses. *Br J Ophthalmol*. 2010;94(8):1003-1006.
- Garzón N, Poyales F, de Zárate BO, Ruiz-García JL, Quiroga JA. Evaluation of rotation and visual outcomes after implantation of monofocal and multifocal toric intraocular lenses. *J Refract Surg*. 2015;31(2):90-97.
- Oshika T, Fujita Y, Hirota A, et al. Comparison of incidence of repositioning surgery to correct misalignment with three toric intraocular lenses. *Eur J Ophthalmol*. 2020;30(4):680-684.

27. Potvin R, Kramer BA, Hardten DR, Berdahl JP. Toric intraocular lens orientation and residual refractive astigmatism: an analysis. *Clin Ophthalmol*. 2016;10:1829-1836.
28. Shah GD, Praveen MR, Vasavada AR, Vasavada VA, Rampal G, Shastry LR. Rotational stability of a toric intraocular lens: influence of axial length and alignment in the capsular bag. *J Cataract Refract Surg*. 2012;38(1):54-59.
29. Novis C. Astigmatism and toric intraocular lenses. *Curr Opin Ophthalmol*. 2000;11(1):47-50.
30. Raman S, Redmond R. Reasons for secondary surgical intervention after phacoemulsification with posterior chamber lens implantation. *J Cataract Refract Surg*. 2003;29(3):513-517.
31. Bauer NJ, de Vries NE, Webers CA, Hendrikse F, Nuijts RM. Astigmatism management in cataract surgery with the AcrySof toric intraocular lens. *J Cataract Refract Surg*. 2008;34(9):1483-1488.
32. Veselá M, Baráková D, Bujalková D, Garajová D. The Effect of Toric Multifocal Lens Rotation on Visual Quality. *Cesk Slov Oftalmol*. 2016;72(2):3-11.
33. Mingo-Botín D, Muñoz-Negrete FJ, Won Kim HR, Morcillo-Laiz R, Rebolleda G, Oblanca N. Comparison of toric intraocular lenses and peripheral corneal relaxing incisions to treat astigmatism during cataract surgery. *J Cataract Refract Surg*. 2010;36(10):1700-1708.
34. de Silva SR, Evans JR, Kirthi V, Ziaei M, Leyland M. Multifocal versus monofocal intraocular lenses after cataract extraction. *Cochrane Database Syst Rev*. 2016;12: Art. No.: CD003169. doi: 10.1002/14651858.CD003169.pub4