

# CURRENT VIEW OF THE SPECTRUM OF PACHYCHOROID DISEASES. A REVIEW

Stěpanov A.

Department of Ophthalmology, University Hospital Hradec Králové and Faculty of Medicine, Charles University in Hradec Králové, Czech Republic

*The author of the study declares that no conflict of interests exists in the compilation, theme and subsequent publication of this professional communication, and that it is not supported by any pharmaceuticals company. The author further declares that the study has not been submitted to any other journal or printed elsewhere, with the exception of congress abstracts and recommended procedures.*

Received: 5 October 2022

Accepted: 3 March 2022

Available on-line 20 February 2023:



Assoc. prof. Alexandr Stěpanov,  
MD, PhD, MBA, FEBO  
Oční klinika FN Hradec Králové  
a LF v Hradci Králové,  
Univerzita Karlova  
Sokolská 581  
500 05 Hradec Králové  
E-mail: stepanov.doctor@gmail.com

## SUMMARY

**Introduction:** The term "pachychoroid" (greek pachy- [παχύ] - thick) was first used by Warrow et al. in 2013. It is defined as an abnormal and permanent increase in choroidal thickness  $\geq 300 \mu\text{m}$ , which is caused by dilatation of the choroidal vessels of the Haller's layer, thinning of the Sattler's layer and the choriocapillaris layer.

**Methodology:** Literary research focused on the current view of pachychoroid spectrum diseases, including clarification of the pathophysiological theories of the formation of "pachychoroid".

**Results:** It is assumed that "pachychoroid" disease has an autosomal dominant type of heredity. Depending on the further activity of various exogenous and/or endogenous factors, pachychoroid diseases may appear. According to the current knowledge, the spectrum of pachychoroid disease covers six clinical entities: pachychoroid pigment epitheliopathy, central serous chorioretinopathy, pachychoroid neovascularopathy, polypoid choroidal vascularopathy, focal choroidal excavation and peripapillary pachychoroid syndrome. In this study, we describe the clinical symptoms and objective findings of focal choroidal excavation and peripapillary pachychoroid syndrome. The current pathophysiological theory of pachychoroid diseases is based on impaired venous outflow from the choroid ("venous overload choroidopathy") and thickening of the sclera in the eyes of affected patients.

**Conclusion:** Pachychoroid diseases should be included in the differential diagnosis of characteristic features observed during multimodal imaging analysis of choroidal changes.

**Key words:** pachychoroid, focal choroidal excavation, peripapillary pachychoroid syndrome, venae vorticosae, choroidopathy of venous congestion

Čes. a slov. Oftal., 79, 2023, No. x, p. x-xx

## INTRODUCTION

In 2013 Warrow et al. introduced the term "pachychoroid", which is the main symptom of enlargement of subfoveal choroidal thickness to a value of  $>300 \mu\text{m}$  [1]. At the beginning of 2019, Cheung et al. proposed the division of the spectrum of pachychoroid pathologies into the following 6 units: pachychoroid pigment epitheliopathy (PPE), central serous chorioretinopathy (CSC), pachychoroid neovascularopathy (PNV), polypoid choroidal vascularopathy (PCV), focal choroidal excavation (FCE) and peripapillary pachychoroid syndrome (PPS) [2].

The chief anatomical feature of the spectrum of pachychoroid diseases is enlargement of the thickness of the choroid as a consequence of venous dilation (pachyvessels) in the Haller's layer, with their hyperpermeability demonstrated according

to angiography with indocyanine green (ICG-A) [3]. Further symptoms include thinning of the choriocapillaris layer and the Sattler's layer [4]. The first four clinical units of the spectrum of pachychoroid diseases in the macular zone (PPE, CSC, PNV, PCV) are considered a continuous process, in which the individual findings can be recorded in a single patient [5,6]. Their objective finding and clinical course have been described in detail in previous publications from our centre [6,7]. In this article we shall focus on FCE, PPS and the pathophysiology of the pachychoroid state. The characteristics of the individual pathologies on the spectrum of pachychoroid diseases are presented in summary in Table 1.

### Focal choroidal excavation

FCE was first described in 2006 by 2006 Jampol et al. in a 62-year-old patient with severe myopia, without

ocular symptoms [8]. Before 2006 FCE was considered a congenital malformation of the posterior segment of the eye, constituting a "microstaphyloma of the choroid".

The aetiology of the disease incorporates the following potential causes [9]:

1. congenital condition
2. upon a background of pachychoroid
3. in connection with inflammation (white dot syndrome) etc.
4. degenerative (Stargardt's disease, Best's disease, pattern dystrophy of the macula etc.)

From a histopathological perspective, FCE represents an inverse type of PED, in which the thinning of the choriocapillaris layer and Sattler's layer as a consequence of pachyvessels leads to the development of ischaemia (compartment syndrome), focal damage to the complex of the RPE/Bruch's membrane with subsequent deepening of both the choroid and RPE [9].

Risk factors include mild myopia, age of 40–50 years, the temporal quadrant of the macula is frequently affected, and there is a higher prevalence in the Asiatic population [10,11]. In most cases patients have no ocular complaints.

A typical objective finding covers mild dysgrouping of pigment or yellow placoid lesions in the macular region [12]. Deepening of the choroid is evident on OCT, with a physiological condition of the neuroretina above the place of the depression (Fig. 1). In the majority of cases it is possible to record a classic image of a pachychoroid state in the region surrounding the choroidal depression – pachyvessels of the Haller's layer with thinning of the choriocapillaris and the Sattler's layer [13]. The morphological description and division are based primarily on the OCT examination. The most frequently used classification of the disease is according to the connection of the neuroretina and RPE: conforming type (connection remains) and nonconforming type (connection disrupted) [11].

Shinojima et al. described three types of FCE according to shape [10]:

1. cone shape, most common type
2. bowl shape, higher incidence of RPE defects on OCT and degenerative changes in angiography
3. mixed

FCEs can also be classified according to their location, as foveal or extrafoveal on the basis of whether the centrum of the fovea is involved in the deepening [14]. Lee et al. demonstrated that up to three quarters of symptomatic cases have foveal type of FCE and nonconforming type [12].

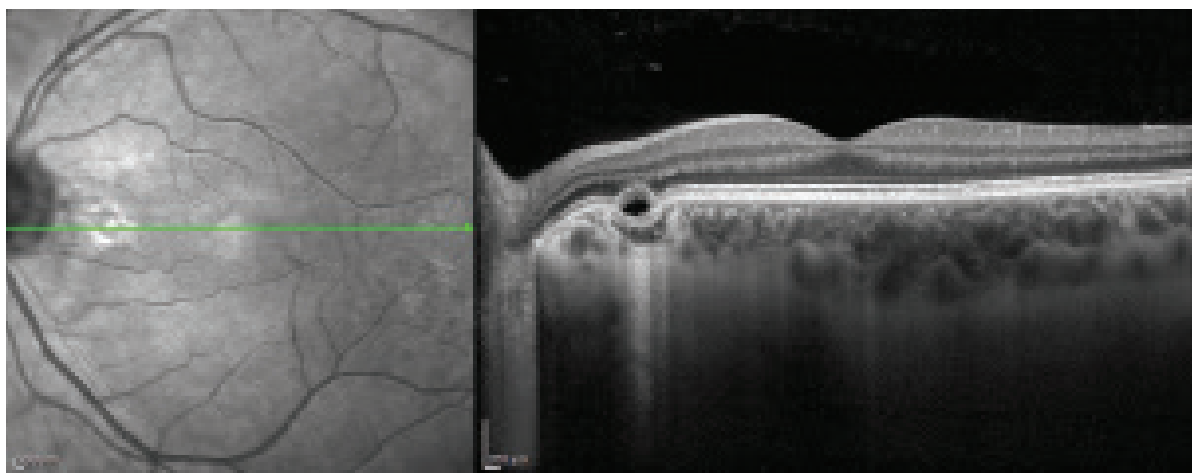
On autofluorescence it is possible to record focal hypoautofluorescence, on FAG the finding is within the norm or window defects of the RPE are evident [15]. On ICG-A a typical finding is focal hypofluorescence correlating in the late phase with a loss of the choriocapillaris layer.

The condition does not require treatment due to the patient's good visual acuity and stable finding over time [14].

### **Peripapillary pachychoroid syndrome**

Peripapillary pachychoroid syndrome is a relatively new pathological unit from the spectrum of pachychoroid diseases. It was first described in 2018 by Phasukkijwatana et al., who defined PPS in the following manner: 1) presence of intraretinal and/or subretinal fluid in the nasal part of the macula ensuing from the temporal margin of the optic nerve disc, demonstrated according to OCT examination, 2) thickening of the choroid in this region [16].

It is assumed that this concerns a variant of CSC in the peripapillary zone with typical symptoms: dilated choroidal veins, hyperpermeability of the choroid and subretinal exudation (Fig. 2) [17]. On the border of the retina/optic nerve is a layer of glial cells (Kuhnt



**Figure 1.** Linear horizontal transfoveal OCT scan of left eye: focal choroidal excavation of nasal part of macula

intermediary tissue), which continues to the Jacobi layer (glial tissue between the choroid and the optic nerve) [18]. Ablation of the juxtapapillary retina and choroid probably deforms these layers and enables transudation of the

fluid into the neuroretina. The pathophysiology is linked with hyperpermeability of the choroid on the basis of a defect of the outer blood-retinal barrier (RPE). Risk factors include mild hypermetropia, age of 70–80 let, smaller

**Table 1.** Comparison of clinical units of spectrum of pachychoroid diseases

	PPE	CSC	PNV	PCV	PPS	FCE
Age (years)	27–89	39–51	52–73	61–75	7. decade	40–50
Symptoms	Usually without symptoms	Decreased vision, metamorphopsia, micropsia or minor hyperopic shift	It may be asymptomatic or have symptoms associated with CSC	Decreased vision	Usually without symptoms	Usually without symptoms, or blurred vision and metamorphopsia
Clinical signs	Dysgrouping of the RPE	Serous neuroretinal detachment with or without PED	Occult CNV, vascular complex "tangled network" under irregular RPE ablation	Occult CNV, proliferation of choroidal capillaries under the RPE and development of aneurysms in the form of polyps	Fluid in the nasal part of the macula arising from the temporal edge of the optic disc	Choroidal thinning (rather than thickening) in the region of the choroidal recess with an intact neuroretina
AF	Mixed dotlike hypo and hyper-AF	Mixed dotlike hypo and hyper-AF larger area than PPE	Irregular AF in the affected area	Granular hypo-AF, annular lesion with central hypo-AF and surrounding hyper-AF	Focal hyper-AF	Focal hypo-AF
FAG	Window defects of the RPE	Leakage at the level of RPE, "ink spot" or "chimney smoke", irregular hyper/hypo fluorescence in chronic CSC	Less obvious hyperfluorescence with late fluorescein leakage	CNV pooling	Peripapillary pooling	Normal finding or window defects of the RPE
ICGA	Choroidal hyperpermeability	Multifocal hyperfluorescence, increases in the middle phase, which disappears in the late phase, choroidal hyperpermeability	Irregular mid-phase hyperfluorescence and late discrete hyperfluorescence corresponding to occult CNV	Gradual gradation of hyperfluorescence of polyps	Focal leakage of the peripapillary zone	Late phase hypo fluorescence correlated with loss of the choriocapillaris layer
OCT	Focal RPE abnormalities	Serous neuroretinal detachment, PED, focal RPE abnormalities	Signs of occult CNV	Signs of occult CNV with aneurysmal lesions	Pachy-vessels and pachychoroid temporal to head of the optic	Choroidal thinning (rather than thickening) in the region of the choroidal depression with an intact neuroretina
OCTA	No signs of CNV	No evidence of CNV or secondary occult CNV	Occult CNV, "tangled network" vascular complex under irregular RPE ablation	Occult CNV, proliferation of choroidal capillaries under the RPE and development of aneurysms in the form of polyps	No signs of CNV	No signs of CNV, focal loss of the choriocapillaris layer
Recommendations	Observation	Observation Non-steroidal antiphlogistics Micropulse laser PDT Anti-VEGF (off-label)	Anti-VEGF PDT	Anti-VEGF PDT	Observation	Observation

PPE – pachychoroid pigment epitheliopathy, CSC – central serous chorioretinopathy, PNV – pachychoroid neovasculopathy, PCV – polypoid choroidal vasculopathy, AF – fundus autofluorescence, CNV – choroidal neovascular membrane, FAG – fluorescein angiography, ICGA – indocyanine green angiography, OCT – optical coherence tomography, OCTA – optical coherence tomography angiography, PED – pigment epithelial detachment, RPE – retinal pigment epithelium, VEGF – vascular endothelial growth factor, PDT – photodynamic therapy

excavation of the optic nerve papilla and male sex [16].

A typical FAG symptom is pooling of the affected peripapillary region with ablation of the neuroretina. On ICG-A it is possible to record pachyvessels of the choroid with progressively grading infiltration. Another symptom is irregular mottling of the peripapillary retinal pigment epithelium (RPE), which is better visible in autofluorescence. Edema of the optic nerve papilla is present in some patients [19].

At present no recommended treatment exists for PPS. Intravitreal anti-VEGF injections and topical or systemic carboanhydrase inhibitors are ineffective [16].

### **Pathophysiological theories of the origin of pachychoroid diseases**

#### ***The influence of venous outflow, “venous overload choroidopathy”***

The original theory of the pathophysiology of pachychoroid diseases (mainly CSC) was founded on the increased vascular hyperpermeability of the choroid in connection with a degeneration of the RPE, vascular abnormalities, ischaemia due to various different causes, and compression of the choriocapillaris [2]. With advances in modern multimodal examination methods (OCT, OCT-A and wide-angle ICG-A), deterioration of venous outflow from the choroid has come to the forefront of the pathophysiology of pachychoroid diseases. Arterial blood from the short posterior ciliary arteries provides nourishment to the choriocapillaris layer in the choroid, and is subsequently drained via a system of vorticos veins through the sclera. Although the pathways of choroidal venous drainage are functionally independent in each ocular quadrant, numerous anastomoses exist between them [20]. If congestion occurs in one of the vorticos veins, the blood directed into its ampulla may flow out retrogradely into the neighbouring quadrant via already existing anastomoses or new collaterals. This is followed by overloading of the entire system of vorticos veins, an increase of venous pressure and a dilation of the choroidal capillaries [21]. Anastomoses of vorticos veins appear in virtually the same number in the upper nasal, upper temporal and lower temporal quadrant [17]. They have been described less frequently in the lower nasal

quadrant. In patients with PPS, anastomoses of vorticos veins are found predominantly in the peripapillary region. In the human body, an increase of venous pressure may lead to vascular dilation and remodelling, with a subsequent increase of venous counterpressure. A typical example is the formation of varicose veins. In the same manner, expanded veins and anastomoses in the eye increase venous outflow pressure from the choriocapillaris, with subsequent transudation and damage to the choriocapillaris layer.

#### ***The influence of the sclera***

In 2021, Imanaga et al. came to the conclusion that the thickness of the sclera in eyes with CSC is greater than in healthy individuals [22]. Thickening of the sclera has two consequences:

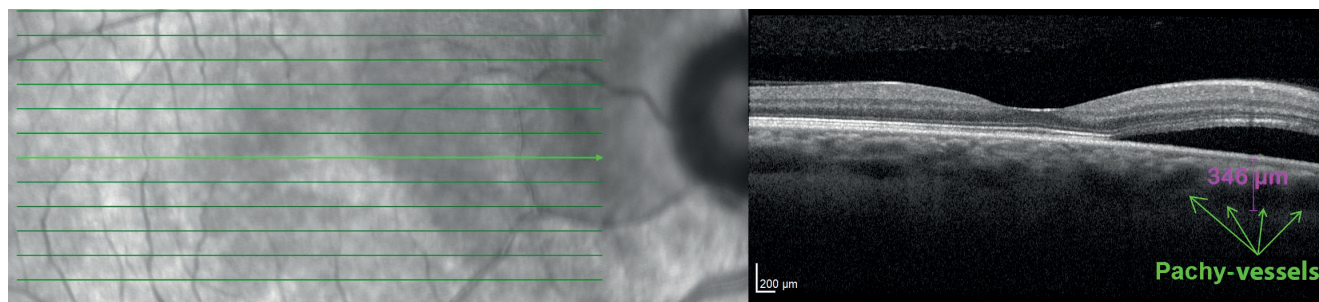
1) the permeability of tissue is indirectly linked with its thickness. Greater scleral thickness extends the length of the compressed vortex vein, with a subsequent increase in the effect of Starling's resistance.

2) enlargement of the valvular effect of the vortex veins passing through the longer scleral wall.

#### ***Choriocapillaris and pachyvessels***

The relationship between ischaemia of the choriocapillaris layer and the dilated vessels of the choroid remains controversial. For example, it is not clear as to which change is primary and which is secondary. Some authors are of the opinion that ischaemia of the choriocapillaris layer occurs secondarily. Gal-Or et al. determined that the presence of pachyvessels is linked with a decrease of the blood supply to the choriocapillaris layer on average by 60% [23].

With regard to the fact that thickening of the choroid occurs proportionately to an enlarged luminal region in diseases of the pachychoroid spectrum, it is difficult to draw the conclusion that dilated pachyvessels mechanically compress the choriocapillaris layer, with subsequent ischaemia and degeneration [24]. Another theory is linked with the activation of the sympathetic  $\alpha$ -adrenoreceptor, with subsequent focal vasoconstriction of the arterioles of the choroid, and ischaemia of the choriocapillaris layer with increased resistance to blood flow. The result is secondary passive



**Figure 2.** Linear horizontal transfoveolar OCT scan of right eye: peripapillary pachychoroid syndrome, neuroretinal ablation in peripapillary zone

overpressure in the surrounding large veins of the choroid, and the formation of dilated pachyvessels [25].

## CONCLUSION

The spectrum of pachychoroid diseases is currently composed of 6 clinical units – PPE, CSC, PNV, PCV, FCE and PPS. The first 4 states are considered to represent a continuous process of the progression of the pathology,

in which the individual findings can be recorded in the macula of a single patient. FCE represents an inversion of the PED type, with deepening of the choroid. The last clinical unit, namely PPS, is a variant of CSC in the peripapillary zone. The current pathophysiological theory of the origin of pachychoroid diseases is based on a deterioration of venous outflow from the choroid (“venous overload choroidopathy”) and a thickening of the sclera in the eyes of affected patients.

## REFERENCES

1. Warrow DJ, Hoang QV, Freund KB. Pachychoroid pigment epitheliopathy. *Retina*. 2013;33(8):1659-1672.
2. Cheung CMG, Lee WK, Koizumi H, Dansingani K, Lai TYY, Freund KB. Pachychoroid disease. *Eye (Lond)*. 2019;33(1):14-33.
3. Borooah S, Sim PY, Phatak S, et al. Pachychoroid spectrum disease. *Acta Ophthalmol*. 2021;99(6):e806-e822.
4. Akkaya S. Spectrum of pachychoroid disease. *Int Ophthalmol*. 2018;38(5):2239-2246.
5. Ayachit G, Ayachit A, Nadgir H, Joshi S. Validating the pachychoroid disease spektrum using multimodal imaging. *Indian J Ophthalmol*. 2018;66(7):1022-1024.
6. Stěpanov A, Studnicka J, Jirásková N. Pachychoroid Disease of the Macula – Case Report. *Cesk Slov Oftalmol*. 2018;74(5):208-211.
7. Stěpanov A, Studnicka J, Středová M, Jirásková N. Pachychoroid disease of the macula. *Cesk Slov Oftalmol*. 2018;74(1):3-8.
8. Jampol LM, Shankle J, Schroeder R, et al. Diagnostic and therapeutic challenges. *Retina* 2006;26:1072-1076.
9. Verma S, Kumar V, Azad S, et al. Focal choroidal excavation: review of literature. *Br J Ophthalmol*. 2021;105(8):1043-1048.
10. Shinojima A, Kawamura A, Mori R, et al. Morphologic features of focal choroidal excavation on spectral domain optical coherence tomography with simultaneous angiography. *Retina Phila Pa*. 2014;34:1407-1414.
11. Margolis R. The expanded spectrum of focal choroidal excavation. *Arch Ophthalmol* 2011;129:1320.
12. Lee CS, Woo SJ, Kim Y-K, et al. Clinical and spectral-domain optical coherence tomography findings in patients with focal choroidal excavation. *Ophthalmology* 2014;121:1029-35.
13. Chung H, Byeon SH, Freund KB. Focal choroidal excavation and its association with pachychoroid spectrum disorders: a review of the literature and multimodal imaging findings. *Retina* 2017;37:199-221.
14. Obata R, Takahashi H, Ueta T, et al. Tomographic and angiographic characteristics of eyes with macular focal choroidal excavation. *Retina Phila Pa*. 2013;33:1201-1210.
15. Chung CY, Li SH, Li KKW. Focal choroidal excavation-morphological features and clinical correlation. *Eye Lond Engl*. 2017;31:1373-1379.
16. Phasukkijwatana N, Freund KB, Dolz-Marco R, et al. Peripapillary pachychoroid syndrome. *Retina*. 2018;38(9):1652-1667.
17. Spaide RF, Ledesma-Gil G. Choriocapillaris vascular parameters in normal eyes and those with pachychoroid and without disease. *Retina*. 2021;41(4):679-685.
18. Hogan MJ, Alvarado JA, Weddell JE. *Histology of the Human Eye. An Atlas and Textbook*. 1971.
19. Castro-Navarro V, Behar-Cohen F, Chang W, et al. Pachychoroid: current concepts on clinical features and pathogenesis. *Graefes' Archive for Clinical and Experimental Ophthalmology*, 2021;259(6):1385-1400.
20. Oyster CW. *The Human Eye: Structure and Function*. 1999, pp. 766.
21. Matsumoto H, Hoshino J, Mukai R, et al. Chronic choriocapillaris ischemia in dilated vortex vein region in pachychoroid neovascularopathy. *Sci Rep*. 2021;11(1):16274.
22. Imanaga N, Terao N, Nakamine S, et al. Scleral Thickness in Central Serous Chorioretinopathy. *Ophthalmol Retina*. 2021;5(3):285-291.
23. Gal-Or O, Dansingani KK, Sebro D, et al. Inner choroidal flow signal attenuation in pachychoroid disease: Optical Coherence Tomography Angiography. *Retina*. 2018;38(10):1984-1992.
24. Lee M, Lee H, Kim HC, Chung H. Changes in Stromal and Luminal Areas of the Choroid in Pachychoroid Diseases: Insights Into the Pathophysiology of Pachychoroid Diseases. *Invest Ophthalmol Vis Sci*. 2018;59(12):4896-4908.
25. Saito M, Saito W, Hashimoto Y, Yoshizawa C, Fujiya A, Noda K, Ishida S. Macular choroidal blood flow velocity decreases with regression of acute central serous chorioretinopathy. *Br J Ophthalmol*. 2013;97(6):775-780.