

VOGT-KOYANAGI-HARADA DISEASE: THE CLINICAL SPECTRUM AND MANAGEMENT OF CASE SERIES IN A TERTIARY EYE CENTRE IN NORTHERN PART OF MALAYSIA

Hasan Nur Atiqah^{1,2}, Mustapha Mushawiahti², Wan Abdul Halim Wan Haslina²

¹Department of Ophthalmology, Hospital Sultanah Bahiyah, Malaysia

²Department of Ophthalmology, Faculty of Medicine, University Kebangsaan Malaysia Medical Center, Malaysia

The authors have no conflict of interest in this work.

Submitted to the editorial board: June 14, 2023

Accepted for publication: December 22, 2023

Available on-line: January 29, 2024



Dr Nur Atiqah Hasan
Department of Ophthalmology
University Kebangsaan Malaysia
Medical Center
Cheras
56000 Kuala Lumpur, Malaysia
E-mail: syikk_1201@yahoo.com

SUMMARY

Aims: We present the clinical spectrum, the initial clinical presentation with management trends in treating 14 Vogt-Koyanagi-Harada (VKH) disease cases in a tertiary center in the Northern part of Malaysia.

Case series: There were 14 cases of Vogt-Koyanagi-Harada (VKH) disease retrospectively reviewed over five years (from 2015 to 2020). The mean age at presentation was 37.7 years (range 21–64 years), with female predominance (85.7%). All cases presented with acute uveitic stage and bilateral eye involvement. Of them, 11 (78.6%) were probable VKH, and three (21.4%) were incomplete VKH. All patients attended with acute panuveitis at first presentation. The main posterior segment involvement was disc edema in 57.1% (16 out of 28 eyes) and exudative retinal detachment (ERD) in 35.7% (10 out of 28 eyes). Most of them presented with blindness (3/60 and worse) and moderate visual impairment (6/18–6/60); 35.71% each, followed by mild visual impairment (6/12–6/18), and severe visual impairment (6/60–3/60); 7.1% each. Ten patients (71.4%) required combination second-line immunomodulatory treatment during subsequent visits, and only four patients (28.6%) responded well to corticosteroid therapy. Most of the cases achieved no visual impairment (64.3%), followed by mild visual impairment (21.4%) and moderate visual impairment (14.3%), and none were severe or blind at the end of follow-up.

Conclusion: VKH is a potentially blinding illness if there is inadequate control of the disease in the acute stage. Most of our patients achieved good visual outcomes with early immunomodulatory treatment and systemic corticosteroids.

Keywords: Vogt-Koyanagi-Harada Disease, immunomodulatory, corticosteroid, panuveitis

Čes. a slov. Oftal., 80, 2024, No. 3, p. 140–144.

INTRODUCTION

Vogt-Koyanagi-Harada (VKH) is a systemic autoimmune disease, affecting the melanin-containing cells, mainly in the eyes, meninges, ear, and skin. It accounts for 6–8% of the Asian population [1,2], with adult females predominant [3,4]. In Japan, 6.8–9.2% of uveitis cases are due to VKH [9]. This is similarly found in the Singapore population, where VKH was found to be the commonest cause of panuveitis (32.8%), accounting for 7.2% of all uveitis cases that were treated from 1997–2001 [16]. This disease has a strong genetic association with HLA-DRB1*0405 [5–7]. Eye involvement is usually bilateral [8,9] rather than unilateral.

It presents in four phases: prodromal, acute uveitic, convalescent, and chronic recurrent. Patients may present with ocular manifestations, such as optic disc

swelling, panuveitis, and exudative retinal detachment (ERD). Extraocular manifestations include neurological (headache and meningismus), auditory (tinnitus and hearing loss), and integumentary changes (alopecia, poliosis, and vitiligo) also can occur.

Early and aggressive treatment with systemic corticosteroids is still the mainstay of treatment of acute VKH, to halt the inflammatory process quickly. Inadequate treatment in the initial stage may lead to recurrent disease. As the frequency of ocular inflammatory attacks increases, the occurrence of ocular complications increases, and it is associated with an inferior visual prognosis. Immunomodulatory treatment (IMT) can be started concurrently in patients, as it can take from weeks to months to achieve a full effect, thus allowing corticosteroid withdrawal.

The first International Workshop on VKH disease recommended new revised diagnostic criteria to assist

diagnosis of VKH in 2001. These are summarized in Table 1 [18]. The disease is categorized as (a) 'complete VKH' if the patient presents with ocular, neurological, auditory, and integumentary involvement; (b) 'incomplete VKH' if the patient presents with ocular and either neurological/auditory or integumentary involvement; and (c) 'probable VKH' if only ocular presentation is present [4,5,18]. Patients can present with VKH in the acute/early or chronic/late stage.

Herewith, we present 14 cases of VKH in a tertiary eye center in the Northern part of Malaysia over five years.

MATERIAL AND METHODS

This was a retrospective review of patients with Vogt-Koyanagi-Harada disease, treated in the Ophthalmology Clinic of Hospital Sultanah Bahiyah between 2015 and 2020. Fourteen patients were identified from the hospital records with informed consent and adhered to the Declaration of Helsinki. A detailed history and ocular examination were collected, including visual acuity (VA) with Snellen Chart, intraocular pressure (IOP), slit lamp examination, fundus evaluation using a super field aspheric lens, and indirect ophthalmoscopy using a 20D aspheric lens. An Ultrasound B scan was performed in required cases, and fundus photography was recorded. Baseline blood investigations, including complete blood count (CBC), erythrocyte sedimentation rate (ESR), renal profile (RP), liver function test (LFT), random blood sugar (RBS), chest X-ray, Mantoux test, serology for hepatitis B, hepatitis C, HIV and syphilis were obtained.

The International Classification of Disease 11 (2018) classified visual impairment into two groups: distance

and near visual impairment. Distance vision impairment included mild-presenting visual acuity worse than 6/12, moderate-presenting visual acuity worse than 6/18, severe-presenting visual acuity worse than 6/60, and blindness-presenting visual acuity worse than 3/60 [19].

RESULTS

A total of 28 eyes of 14 patients were evaluated. Among them, 85.7% (12/14) were female. Most of them were Malay, 78.5% (11/14), followed by Chinese, 14.2% (2/14), and Indian, 7.14% (1/14). The mean age at presentation was 37.7 years (range 21–64 years).

All patients presented initially in the acute uveitic phase and with bilateral eye involvement. Among the 14 cases, 78.6% (11/14) were probable VKH, 21.4% (3/14) were incomplete VKH, and none were complete VKH. Among them, ten eyes (35.7%) developed hypopigmented fundus with a 'sunset glow' appearance at the end of the study.

The most common presenting symptom was blurring of vision in 92.8% (26 out of 28 eyes). At first presentation, most of them presented with blindness (3/60 and worse) and moderate visual impairment (6/18–6/60); 35.7% each, followed by mild visual impairment (6/12–6/18) and severe visual impairment (6/60–3/60); 7.1% each. All patients attended with acute panuveitis at first presentation. Main posterior segment involvement was disc edema in 57.1% (16 out of 28 eyes) and exudative retinal detachment (ERD) in 35.7% (10 out of 28 eyes), Figure 1. During the follow-up, ten eyes (35.7%) developed hypopigmented fundus with a sunset glow appearance. Extraocular manifestations were present in three cases. Integumentary finding (vitiligo) was found in one

Table 1. Diagnostic criteria of Vogt-Koyanagi-Harada disease

Complete Vogt-Koyanagi-Harada disease (VKH) (criteria 1 to 5 must be present)
1. No history of penetrating ocular trauma or surgery preceding the initial onset of uveitis
2. No clinical or laboratory evidence suggestive of other ocular disease
3. Bilateral ocular involvement (A or B must be met, depending on stage of disease when the patient is examined). <u>A. Early (acute) manifestation of disease</u> -There must be evidence of a diffuse choroiditis (with or without anterior uveitis, vitreous inflammatory reaction, or optic disc hyperemia), which may manifest as one of the following: 1) Focal areas of subretinal fluid, or 2) Bullous serous retinal detachments. -With equivocal fundus finding; both of the following must be present: 1) Focal areas of delay in choroidal perfusion, multifocal areas of pinpoint leakage, large placoid areas of hyperfluorescence, pooling within subretinal fluid, and optic nerve staining by fluorescein angiography, and 2) Diffuse choroidal thickening, without evidence of posterior scleritis. <u>B. Late manifestation of disease</u> -History suggestive of prior presence of findings -Ocular depigmentation; sunset glow fundus or Sugiura's sign -Other ocular sign: 1) Nummular chorioretinal depigmented scar, or 2) Retinal pigment epithelium clumping and/or migration, or 3) Recurrent or chronic anterior uveitis.
4. Neurological/auditory findings (may have resolved during the time of examination); menigismus, tinnitus or cerebrospinal fluid pleocytosis
5. Integumentary findings (not preceding onset of central nervous system or ocular disease); alopecia, or poliosis, or vitiligo.
Incomplete Vogt-Koyanagi-Harada disease (criteria 1 to 3 and either 4 or 5 must be present as defined in complete VKH)
Probable Vogt-Koyanagi-Harada disease (isolated ocular disease; criteria 1 to 3 must be present)

patient, while another two patients had neurological (headache) and auditory (tinnitus) findings each.

In most cases, the fluorescent angiography (FA) finding was multiple spots of pinpoint hyperfluorescence in the early arteriovenous phase (Figure 2), with dye pooling within the retinal detachment (RD) in the late phase of the angiogram.

During the initial presentation, 28.5% (4 out of 14 cases) received oral and topical corticosteroids, while the majority of them, 71.4% (10 out of 14 cases) received intravenous corticosteroids. IMT, either Azathioprine or Cyclosporin, was started concurrently during the tapering of corticosteroids in 71.4% (10 out of 14 cases) with a recurrence of the disease.

The most common complications were cataracts, comprising 42.8% (12 out of 28 eyes), and secondary

glaucoma in 28.5% (8 out of 28 eyes), which required subsequent cataract removal and antiglaucoma medications, respectively. None of them required any glaucoma filtering surgery.

Most of the cases achieved no visual impairment (64.3%), followed by mild visual impairment (21.4%), moderate visual impairment (14.3%), and none were severe or blind at the end of follow-up (Table 2).

DISCUSSION

Vogt-Koyanagi-Harada disease is an important cause of panuveitis, affecting, more frequently, pigmented skin individuals such as Amerindian, Hispanic [12,13], and Asian patients,

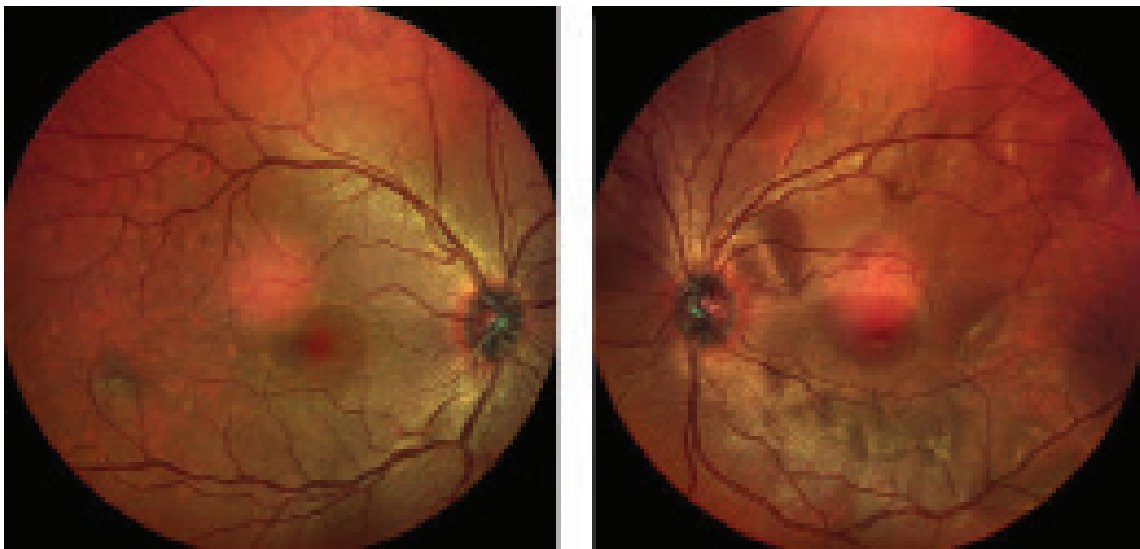


Figure 1. A patient presented in the acute uveitic stage with bilateral eye multifocal exudative retinal detachment

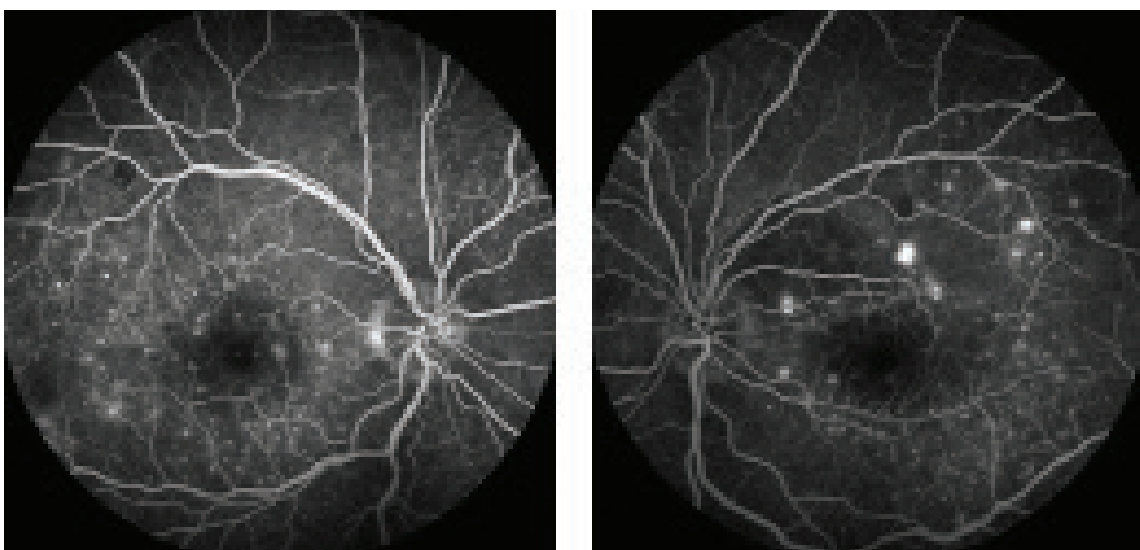


Figure 2. FFA showing bilateral eye multiple pinpoint hyperfluorescence at RPE level
FFA – Fluorescein angiography, RPE – Retinal pigment epithelium

including those from Japan [6], Singapore [10], and Malaysia [8]. K. Diallo et al., who conducted a multicentric study in France, found that North African was the primarily represented ethnicity 58%, followed by Southeast Asian 49%, Caucasian 20%, and Hispanic 2% [13]. Malaysia is a known multiracial country in the Southeast Asian region. In our study, most cases were from the Malay population; most probably because the study was conducted in a Malay-populated area. The epidemiological features of our case series were similar to those of most previous studies, in which females were affected more frequently [3,4,10]. However, our age distribution differs slightly from most previous studies, which typically occurred in the second to fifth decades of life. In contrast, our study shows it in the third to seventh decades of life.

The most striking characteristics of our patients were that all of them presented with the acute uveitic stage, and the majority had poor vision on initial presentation.

The mainstay of treatment is prompt, high-dose systemic corticosteroids, administered either orally or through a short intravenous delivery, followed by slow tapering of oral corticosteroids throughout a minimum 6-month period. IMT is formally indicated in corticosteroid refractory or intolerant cases.

Atsuko et al. found that initial treatment with repeated high-dose intravenous corticosteroid therapy might benefit pediatric VKH disease [14]. Chee SP et al. also found that higher doses of systemic corticosteroids may be required to ensure adequate immunosuppression in VKH patients [16]. However, in our study, only four patients responded to systemic corticosteroids. To halt the disease progress, the remain-

ing ten patients required IMT, either Azathioprine or Cyclosporine. The same applies to a study conducted by Herbot et al. They found that if a combination of systemic steroidal and non-steroidal immunosuppressants is given within 2–3 weeks of the onset of initial VKH disease, the disease outcome can be improved, thus avoiding evolution to chronic disease and ‘sunset glow fundus’ [17].

Recent literature has suggested treatment with IMT as first-line therapy for VKH. Oo EEL et al. found that high-dose corticosteroid with IMT within three months improved visual outcomes and a reduced risk of developing chronic recurrent uveitis, compared with IMT given if clinically indicated [10]. Paredes et al. described IMT given within six months of diagnosis with or without corticosteroids was associated with a superior visual outcome, compared to corticosteroids as monotherapy or with delayed addition of IMT [11]. Similarly, in our study, most patients were treated concurrently with IMT while on a tapering dose of corticosteroids due to recurrences, and they achieved good final visual outcomes.

Recently, Zhong Z et al. from China found that the IMT with cyclosporine plus corticosteroids was non-inferior to the biologic strategy with adalimumab plus corticosteroids concerning visual improvement [15]. However, unlike in the previous study, our patients were still waiting to receive biologic agents.

CONCLUSION

VKH is a severe, potentially blinding illness, and inadequate disease control can result in permanent defects in visual function. Corticosteroid therapy is still the first choice treatment for acute VKH. However, most patients

Table 2. Clinical characteristics, vision at presentation, outcome and treatment

Case no	Sex	Age	Extraocular Manifestation	Presenting VA-Snellen chart (RE, LE)	Final VA-Snellen chart (RE, LE)	Medical Treatment
1	F	32	None	6/36 and CF	6/24 and 6/36	Intravenous Corticosteroid, Azathioprine
2	F	44	Integumentary	HM and HM	6/9 and 6/9	Intravenous Corticosteroid, Azathioprine
3	M	21	Neurological	3/60 and 6/9	6/9 and 6/9	Intravenous Corticosteroid, Azathioprine
4	F	47	None	PL and 1/60	PL and 6/12	Intravenous Corticosteroid, Azathioprine
5	M	25	None	4/60 and 4/60	6/12 and 6/9	Intravenous Corticosteroid, Azathioprine, Cyclosporine
6	F	35	None	6/24 and 3/60	6/9 and 6/9	Intravenous Corticosteroid, Azathioprine
7	F	64	None	6/24 and 6/15	6/9 and 6/9	Intravenous Corticosteroid, Azathioprine
8	F	40	None	6/9 and 6/12	6/9 and 6/9	Oral Corticosteroid
9	F	33	None	6/18 and 6/12	6/9 and 6/9	Oral Corticosteroid
10	F	60	None	PL and PL	6/18 and CF	Intravenous Corticosteroid, Azathioprine
11	F	55	None	CF and CF	6/9 and 6/9	Oral Corticosteroid
12	F	63	Auditory	5/60 and 6/36	6/12 and 6/24	Oral Corticosteroid
13	F	37	None	6/60 and 6/36	6/9 and 6/12	Intravenous Corticosteroid, Azathioprine
14	F	38	None	CF and CF	6/9 and 6/9	Intravenous Corticosteroid, Azathioprine

F – Female, M – Male, VA – Visual Acuity, RE – Right Eye, LE – Left Eye, CF – Counting Finger, HM – Hand Movement, PL – Perception of Light

require long-term immunosuppression, and treatment options for second-line immunomodulatory treatment have been reported to result in significant control of inflammation and better visual outcomes.

Acknowledgments

Ophthalmologist and staff of Ophthalmology Department, Hospital Sultanah Bahiyah, Alor Setar, Kedah, Malaysia.

REFERENCES

1. Lodhi SAK, Lokabhi, RJM, Peram V. Clinical spectrum and management option in Vogt-Koyanagi-Harada disease. *Clin Ophthalmol.* 2017;11:1399-1406.
2. Kharel R, Shah DN, Chaudhary M. Presumed Vogt-Koyanagi-Harada (VKH) disease in Nepalese population; a rare entity. *Clini Ophthalmol Res.* 2016;4:97-100.
3. Agrawal A, Biswas J. Unilateral Vogt-Koyanagi-harada disease, report of two cases. *Mid E Afr J Ophthalmol.* 2011;8:82-84.
4. Usui Y, Goto H, Sakai H, Takeuchi M, Usui M, Rao NA. Presumed Vogt-Koyanagi-Harada disease with unilateral ocular involvement: report of three cases. *Graef Arch Clin Exp Ophthalmol.* 2009;247:1127-1132.
5. Pranav S, Sadhana S, Ranju K. Vogt-Koyanagi-Harada Disease: A case Series in a Tertiary Eye Centre. *Hind Case Rep Ophthalmol Med.* 2021. doi 10.1155/2023/8848659
6. Shindo Y, Inoko H, Yamamoto T, Ohno S. HLA-DRB1 typing of Vogt-Koyanagi-Harada's disease by PCR-RFLP and the strong association with DRB1*0405 and DRB1*0410. *Br J Ophthalmol.* 1994;78(3):223-226.
7. Shindo Y, Ohno S, Yamamoto T, Nakamura S, Inoko H. Complete association of HLA-DRB1*04 and-DQB1*04 alleles with Vogt-Koyanagi-Harada's disease. *Hum Immunol.* 1994;39(3):169-176.
8. Samy AM, Ngah NF, Khialdin SM, Azli NA, Hussin NH, Anee A. Association between HLA-DRB1*04 and Malay patient with Vogt-Koyanagi-Harada syndrome in Malaysia: A case control study. *Malaysian Journal of Ophthalmology.* 2019;2:84-97. doi 10.35119/MYJO.V112.11
9. Ohguro N, Sonoda KH, Takeuchi M, Matsumura M, Mochizuki M. The 2009 prospective multi-center epidemiologic survey of uveitis in Japan. *Jpn J Ophthalmol.* 2012;56:432-435. doi 10.1007/s10384-012-0158-z
10. Oo EEL, Chee SP, Yan Wong KK, Htoon HM. Vogt-Koyanagi-Harada Disease managed with Immunomodulatory Therapy within 3 months of disease onset. *Am J Ophthalmol.* 2020 Dec;220:37-44.
11. Paredes I, Ahmed M, Foster CS. Immunomodulatory therapy for Vogt-Koyanagi-Harada patients as first-line therapy. *Ocul Immunol Inflamm.* 2006;14:87-90.
12. Deák G, Koreishi AF, Goldstein DA. Do not discount the diagnosis of VKH based on race: self-reported race and ethnicity of patients with Vogt-Koyanagi-Harada disease in a predominantly white population. *J Ophthalmic Inflamm Infect* 2023 Mar 29. <https://doi.org/10.1186/s12348-023-00329-2>
13. Diallo K, Revuz S, Clavel-Refregiers G et al. Vogt-Koyanagi-Harada disease: a retrospective and multicentric study of 41 patients. *BMC ophthalmology.* 2020 (20): 395. <https://doi.org/10.1186/s12886-020-01656-x>
14. Katsuyama A, Kusuhara S, Awano H, Nagase H, Matsumiya W, Nakamura M. A case of probable Vogt-Koyanagi-harada disease in a 3-year-old girl. *BMC ophthalmology.* 2019 (19):179. <https://doi.org/10.1186/s12886-019-1192-0>
15. Zhong Z, Dai L, Wu Q, et al. A randomized non-inferiority trial of therapeutic strategy with immunosuppressants versus biologics for Vogt-Koyanagi-Harada disease. *Nature Communications.* June 2023 (14): 3768.
16. Chee SP, Jap A, Bacsal C. Spectrum of Vogt-Koyanagi-Harada disease in Singapore. *Int Ophthalmol.* 2009;27:137-142. doi 10.1007/s10792-006-9009-6
17. Herbot Jr, Abu El Asrar A, Takeuchi M. Catching the therapeutic window of opportunity in early initial-onset Vogt-Koyanagi-Harada uveitis can cure the disease. *Int Ophthalmol.* 2019;39:1419-1425.
18. Read RW, Holland GN, Rao NA et al. Revised diagnostic criteria for Vogt-Koyanagi-Harada disease; report of an international committee on nomenclature. *Am J Ophthalmol.* 2001;131(5):647-652.
19. International Classification of Disease-11 for Mortality and Morbidity-2018 [Internet]. Available from: <http://id.who.int/icd/entity/1103667651>.