

# ASSOCIATION OF FUCHS HETEROCHROMIC IRIDOCYCLITIS WITH MULTIPLE SCLEROSIS

Brichová Michaela<sup>1</sup>, Lízrová Preiningerová Jana<sup>2</sup>,  
Heissigerová Jarmila<sup>1</sup>, Jeníčková Dagmar<sup>1</sup>, Klímová  
Aneta<sup>1</sup>, Svozílková Petra<sup>1</sup>

<sup>1</sup>Department of Ophthalmology, 1<sup>st</sup> Faculty of Medicine, Charles  
University and General University Hospital, Prague, Czech Republic

<sup>2</sup>Department of Neurology, 1<sup>st</sup> Faculty of Medicine, Charles  
University and General University Hospital, Prague, Czech Republic

The authors of the study declare that no conflict of interests exists in the compilation, theme and subsequent publication of this professional communication, and that it is not supported by any pharmaceuticals company. The authors further declare that study has not been submitted for printing to any other journal.

Submitted to the editorial board: December 13, 2023

Accepted for publication: January 23, 2024

Available on-line: March 15, 2024



MUDr. Michaela Brichová  
Oční klinika 1. LF UK a VFN  
U nemocnice 2  
128 08 Praha 2  
E-mail: michaela.brichova@vfn.cz

## SUMMARY

**Purpose:** To draw attention to the higher proportion of Fuchs heterochromic iridocyclitis (FHI) cases in patients with multiple sclerosis (MS).

**Materials and Methods:** Retrospective study of data collected at the Center for the Diagnosis and Treatment of Uveitis.

**Results:** An analysis of the medical records of 3016 patients with uveitis (in the years 2003–2020) was performed with a focus on MS. MS-associated uveitis was diagnosed in 90 patients (3%): anterior uveitis (n = 7), intermediate uveitis (n = 23), retinal vasculitis (n = 24), and panuveitis (n = 36). A clinical examination revealed signs of FHI in the anterior segment in 11 out of 90 cases (12%). Atypical manifestations of FHI included a higher incidence of bilateral involvement (45%), retinal vasculitis (27%), and vitreous snowballs (18%). The diagnosis of FHI preceded the diagnosis of MS in 4 cases. The median latency was 10.5 (range 8–15) years. In 4 patients, the diagnosis of demyelinating disease was established within one year of the diagnosis of FHI. We recommended a neurological examination for optic neuritis (n = 1), paresthesia (n = 3), relapse of motor deficit (n = 1), and screening of etiology in cases with involvement of the posterior segment (n = 3). In the other 3 cases, the diagnosis of MS preceded the diagnosis of FHI, with a median latency of 13 (range 8–19) years.

**Conclusion:** We detected clinical symptoms of FHI in 12% of uveitis cases associated with MS, more often in bilateral manifestations of intra-ocular inflammation. Based on our experience, we recommend an investigation of the medical history of patients with FHI for manifestations of sensitive, sensory and motor deficits, especially in bilateral cases.

**Key words:** Fuchs heterochromic iridocyclitis, Fuchs heterochromic syndrome, multiple sclerosis

Čes. a slov. Oftal., 80, 2024, No. x, p.

## INTRODUCTION

Uveitis, a general term for inflammation of the uveal structures (iris, ciliary body, choroid or retina), covers a highly heterogeneous group of diseases with immune-mediated or infectious causes. Traditionally uveitis is classified according to the primary anatomical localization of the inflammation, as anterior uveitis, intermediate uveitis, posterior uveitis and panuveitis.

Multiple sclerosis (MS) is an autoimmune disorder of the central nervous system (CNS) characterized by inflammation, demyelination and damage to the axons in the CNS [1]. The most common ocular manifestation of MS is optic neuritis, followed by further ocular findings such as internuclear ophthalmoplegia, paresis

of the extraocular muscles or nystagmus. The prevalence of uveitis in patients with MS is within the range of 1–3%, and is therefore approximately 10 times more common than in the regular population [2,3]. The cause of uveitis in patients with MS is unknown. Nevertheless, certain concordances in risk factors and pathophysiology have triggered a debate concerning whether the presence of both disorders in a single patient is rather a matter of chance or whether it is necessary to consider uveitis a manifestation of MS [3].

Published studies state a significant contribution of MS to the etiology of uveitis affecting the posterior segment: intermediate uveitis, retinal vasculitis, and panuveitis [2–9]. An understanding of the relationship between MS and uveitis is important for patient therapy, both for ophthalmologists and for neurologists.

Fuchs Heterochromic Iridocyclitis (FHI) is a chronic, non-granulomatous anterior uveitis [10–13]. The disorder was first described by Ernest Fuchs in 1906 [10]. FHI constitutes up to 20% of all cases of anterior uveitis, and is the second most common form of non-infectious anterior uveitis [11,12]. FHI is characterized by a mild course of inflammation, with the presence of small to medium-sized star-shaped precipitates scattered throughout the entire corneal endothelium, heterochromia of the iris, small Koeppe's nodules of the iris and a mild degree of vitritis. Posterior synechiae and cystoid macular edema are absent in FHI [13,14]. A common manifestation is formation of posterior subcapsular cataract (70% of patients), whereas the development of secondary glaucoma is less common (25% of patients). Cataract and glaucoma represent sight-threatening complications [15,16]. In the typical form the inflammation appears unilaterally. In 10% of patients uveitis may be bilateral, in which case one of the fundamental characteristics is absent, namely heterochromia of the iris [17]. Most cases of FHI are idiopathic. Some studies have published a possible correlation of FHI with infections (toxoplasmosis, toxocariasis, herpes simplex virus), as well as retinitis pigmentosa or ocular trauma [18–23]. Since 2004 a number of studies have documented an association of FHI with rubella or cytomegalovirus infection [24–26]. The variability of the presumed or confirmed etiology of FHI led to a proposal to rename this uveitis Fuchs Heterochromic Syndrome [27,28].

This study investigated the incidence of FHI in patients with MS.

## MATERIAL AND METHODS

This is a retrospective study of data collected at the Center for the Diagnosis and Treatment of Uveitis at the Department of Ophthalmology of the General University Hospital in the years 2003–2020.

Classification of the type of uveitis was performed by an uveitis specialist, and governed by the stan-

dardization of uveitis nomenclature (SUN) [29]. Diagnosis of FHI was based on the recommendations of the International Uveitis Study Group [30]. Clinical and demographic data were obtained by means of an overview focusing on the laterality of the clinical picture, intraocular manifestation, age at the time of diagnosis of FHI and diagnosis of MS, and the reason for recommendation of a neurological examination.

## RESULTS

A total of 3016 patients with uveitis were analyzed. In 3% (90 cases) intraocular inflammation was associated with multiple sclerosis. The median observation period was 167 (range 6–388) months. In our cohort of patients with uveitis in combination with MS, the following types of uveitis were present: anterior uveitis ( $n = 7$ ), intermediate uveitis ( $n = 23$ ), posterior uveitis ( $n = 24$ ) and panuveitis ( $n = 36$ ). In this cohort a finding of FHI corresponded in 12% of patients (Table 1). An analysis of the clinical manifestations of FHI (Table 2) detected that an isolated manifestation of intraocular inflammation was present in the anterior segment (Fig. 1) in 6 cases. FHI was associated with retinal vasculitis in 3 patients, and intermediate uveitis in 2 patients (Fig. 2). Unilateral involvement with typical heterochromia was present in 6 patients (Fig. 3 A, B), while in 5 patients (45% of the cohort) the inflammation was bilateral.

The total number of patients with FHI in our cohort of 3016 was 245 (8%). Bilateral manifestation was recorded in 27 (11%) of these. Diagnosis of MS was present in 18% of patients with bilateral FHI and in 2% of patients with unilateral FHI.

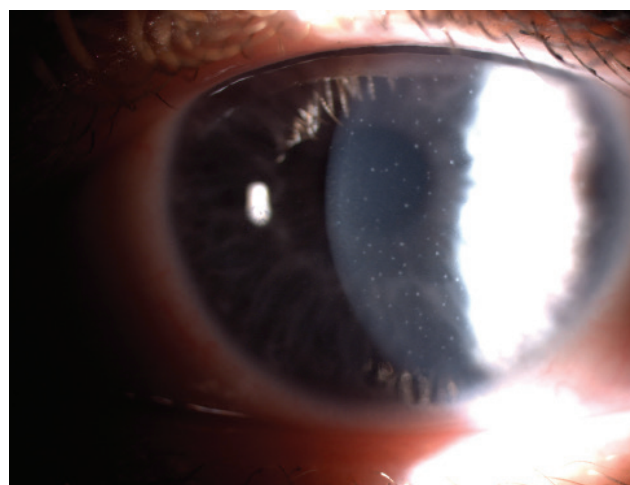
Diagnosis of MS preceded diagnosis FHI in 3 cases (8, 13 or 19 years), and four cases of MS were diagnosed within one year of determination of the diagnosis of FHI. Diagnosis of FHI preceded diagnosis of MS in 4 cases, with a latency of 8–15 years.

A neurological examination was indicated for optic neuritis ( $n = 1$ ), paresthesia ( $n = 3$ ), an episode of

**Table 1.** Types of uveitis in Uveitis + MS cohort and in Uveitis no MS cohort

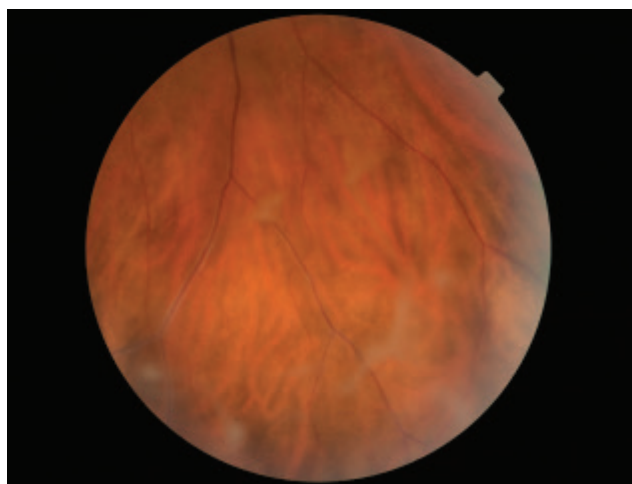
	Uveitis + MS cohort	Uveitis no MS cohort
All uveitis (n) %	(90) 3%	(2926) 97%
Uveitis by type		
Anterior	(7) 8 %	(1730) 60 %
Intermediate	(23) 25 %	(244) 8 %
Posterior	(24) 27 %	(553) 19 %
Panuveitis	(36) 40 %	(399) 13 %
FHI (n) %	(11) 12 %	(234) 7 %

FHI – Fuchs heterochromic iridocyclitis, MS – multiple sclerosis



**Figure 1.** Star-shaped small keratic precipitates

motor deficits (n = 1) and within the framework of investigation of the etiology in cases with affliction of the posterior segment involvement (n = 3).

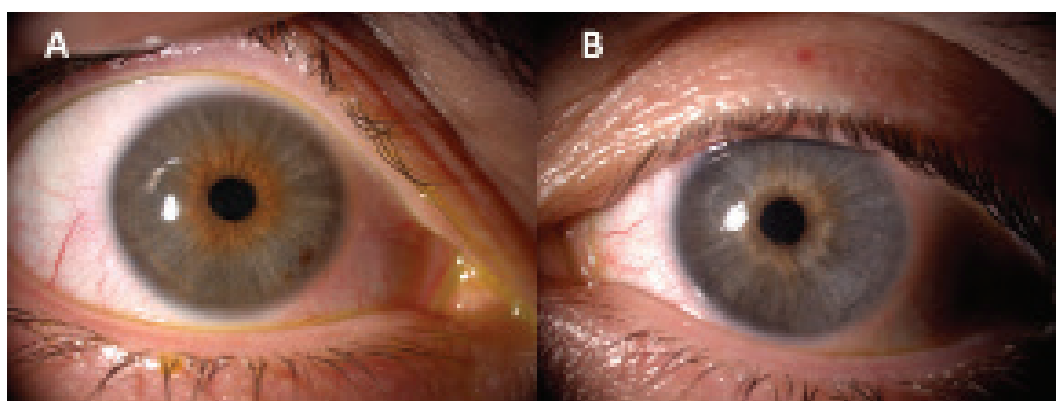


**Figure 2.** Snowballs and white sheathing of vessel

## DISCUSSION

Uveitis affects 1–3% of patients with MS. The prevalence of MS in large cohorts of patients with uveitis is stated at 0.9–1.7% [2,3]. Our cohort of 3016 patients with uveitis contains a higher proportion of cases of uveitis together with MS (3%), which we attribute to the decades of existence of specialized clinics for uveitis and MS within the same academic institution. The proportion of types of uveitis (based on the SUN classification) in our cohort of uveitis and MS is in accordance with the published data. Panuveitis, as the most common clinical manifestation of uveitis in patients with MS, was present in 40% of cases, followed by posterior uveitis (27%), intermediate uveitis (25%) and anterior uveitis (8%). Biousse et al. published similar results: panuveitis was found in 39.3% of patients, followed by intermediate uveitis in 35.7% of cases [7]. However, in further studies intermediate uveitis was the most common manifestation in association with MS, observed in 61%, 80% and 86% of cases respectively [3,5,8].

FHI is one of the most common forms of anterior



**Figure 3.** Iris atrophy in left eye (A), unaffected right eye (B)

**Table 2.** Characteristics of uveitis

N°	Sex	Dg. of FHI (age)	Dg. of MS (age)	Laterality	Atypical features of FHI	Indikace neurologického vyšetření
1	M	22	22	OD	none	optic neuritis
2	F	20	21	ODS	none	paraesthesia
3	F	35	43	OS	none	motor deficits
4	F	41	42	OS	vasculitis	screening of etiology of retinal vasculitis
5	M	18	33	ODS	vasculitis	paraesthesia
6	F	28	28	OD	snowballs	screening of etiology of intermediate uveitis
7	F	47	39	OD	none	Dg. of MS preceded Dg. of FHI
8	F	36	23	OD	none	Dg. of MS preceded Dg. of FHI
9	M	37	48	ODS	vasculitis	screening of etiology of retinal vasculitis
10	F	31	41	ODS	snowballs	paraesthesia
11	F	44	25	ODS	none	Dg. of MS preceded Dg. of FHI

FHI – Fuchs heterochromic iridocyclitis, MS – multiple sclerosis, M – male, F – female, OD – right eye, OS – left eye, Dg – diagnosis

uveitis, constituting as many as 8% of cases of uveitis in reference centers [17,19,20]. The results of our analysis and the predominant unilateral involvement (88% of 245 cases of FHI) correspond with the published data in the references [17,19,20].

FHI was represented in our cohort of patients with uveitis and MS in a greater number than expected. We found symptoms of FHI in 16 eyes of 11 patients. The most significant result of our analysis is on one hand the high identification of bilateral manifestations of FHI with MS (45%), and conversely the significantly more frequent incidence of MS in patients with bilateral manifestation of FHI (18% of 27 cases) in comparison with unilateral FHI (2% of 218 cases). Findings on FHI and its clinical manifestation, such as bilateral involvement of the eyes, are rare and only occasionally analyze the data of the Central European population [13–17].

A higher incidence of MS in patients with FHI has not been described in the literature, and represents a challenge to examine common risk factors between these two diseases [32]. The pathogenic relationship between uveitis and MS is unknown. However, autoimmune responses in the eye and in the central nervous system take place by means of a failure of immune regulation mechanisms, which in susceptible individuals may trigger infectious disease. Genetic factors constitute only part of the risk of development of multiple sclerosis or uveitis, nonetheless both diagnoses share the risk factors HLA-DR-15 and HLA-DR-51. Similarities can also be deduced in the case of viral pathogens associated with FHI and MS. In addition to other factors, FHI

is associated with infections by toxoplasmosis, toxocariasis, rubella, cytomegalovirus, herpes simplex virus and chikungunya virus [18–26,33,34]. In many cases of FHI, viral etiology was demonstrated by PCR examination of anterior chamber aqueous humour samples [22,25,35–37]. The intrathecal IgG response in patients with MS incorporates antibodies against the neurotropic virus panel. A finding of an antibody against the measles virus (M), rubella virus (R) and varicella-zoster virus (Z) in the cerebrospinal fluid is termed the MRZ reaction, which is highly specific to MS [24–26,36–38]. The rubella virus may hypothetically be a connecting risk between FHI and MS. Another shared factor in the pathogenesis of autoimmune disorders may be the role of gut microbiota. Dysbiosis may contribute to immune mediated diseases, including uveitis and MS, or may trigger them [39,40].

## CONCLUSION

The prevalence of MS in patients with uveitis is low, and as a result patients with uveitis are not routinely referred to a neurologist, or do not undergo MR of the brain. We detected clinical symptoms of FHI in 12% of cases of uveitis associated with MS. The above findings indicate that a stronger correlation could exist between FHI and MS, specifically in the case of FHI with bilateral involvement. Based on our experiences, we recommend an investigation of the medical history of patients with FHI for manifestations of sensitive, sensory and motor deficits. Our observation could provide a stimulus for further research in this area.

## REFERENCES

1. Brownlee WJ, Hardy TA, Fazekas F, Miller DH. Diagnosis of multiple sclerosis: Progress and challenges. *Lancet*. 2017;389(10076):1336–1346.
2. Gordon LK, Goldstein DA. Gender and uveitis in patients with multiple sclerosis. *J Ophthalmol*. 2014;2014:565262.
3. Olsen TG, Frederiksen J. The Association between multiple sclerosis and uveitis. *Surv Ophthalmol*. 2017;62(1):89–95.
4. Le Scannff J, Seve P, Renoux C, et al. Uveitis associated with multiple sclerosis. *Mult Scler* 2008;14(3):415–417.
5. Jouve L, Benrabah R, Heron E, et al. Multiple sclerosis-related uveitis: Does MS treatment affects course? *Ocul Immunol Inflamm*. 2017;25(3):302–307.
6. Schmidt S, Wessels L, Augustin A, Klockgether T. Patients with multiple sclerosis and concomitant uveitis/periphlebitis retinae are not distinct from those without intraocular inflammation. *J Neurol Sci*. 2001;187(1–2):49–53.
7. Biousse V, Trichet C, Bloch-Michel E, Roullet E. Multiple sclerosis associated with uveitis in two large clinic-based series. *Neurology*. 1999;52(1):179–181.
8. Messager W, Hildebrandt L, Mackensen F, et al. Characterisation of uveitis in association with multiple sclerosis. *Br J Ophthalmol*. 2015;99(2):205–209.
9. Cunningham ET Jr, Pavesio CE, Goldstein DA, Forooghian F, Zierhut M. Multiple sclerosis-associated uveitis. *Ocul Immunol Inflamm*. 2017;25(3):299–301.
10. Fuchs E. Ueber komplikationen der heterochromie. *Z Augenheilk*. 1906;15:191–212.
11. Abano JM, Galvante PR, Siopongco P, Dans K, Lopez J. Review of epidemiology of uveitis in Asia: pattern of uveitis in tertiary hospital in Philippines. *Ocul Immunol Inflamm*. 2017;25(supl):S75–S80.
12. Tsirouki T, Dastiridou A, Symeonidis C, et al. A focus on the epidemiology of uveitis. *Ocul Immunol Inflamm*. 2018;26(1):2–16.
13. Mohamed Q, Zamir E. Update on Fuchs' uveitis syndrome. *Curr Opin Ophthalmol*. 2005;16(6):356–363.
14. Jones NP. Fuchs' heterochromic uveitis: an update. *Surv Ophthalmol*. 1993;37(4):253–272.
15. Tugal-Tutkun I, Guney-Tefekli E, Kamaci-Duman E, Corum I. A cross-sectional and longitudinal study of Fuchs uveitis syndrome in Turkish patients. *Am J Ophthalmol*. 2009;148(4):510–515.
16. Accorinti M, Spinucci G, Pirraglia MP, et al. Fuchs' heterochromic iridocyclitis in an Italian tertiary referral centre: epidemiology, clinical features, and prognosis. *J Ophthalmol*. 2016;2016:1458624.
17. Jones NP. Fuchs' heterochromic uveitis: a reappraisal of the clinical spectrum. *Eye (Lond)*. 1991;5(Pt6):649–661.
18. Sun Y, Ji Y. A literature review on Fuchs uveitis syndrome: an update. *Surv Ophthalmol*. 2020;65(2):133–143.
19. Teyssot N, Cassoux N, Lehoang P, Bodaghi B. Fuchs heterochromic cyclitis and ocular toxocariasis. *Am J Ophthalmol*. 2005;139(5):915–916.
20. Chowers I, Zamir E, Banin E, Merin S. Retinitis pigmentosa associated with Fuchs' heterochromic uveitis. *Arch Ophthalmol*. 2000;118(6):800–802.
21. Ganesh SK, Sharma S, Narayana KM, Biswas J. Fuchs' heterochromic iridocyclitis following bilateral ocular toxoplasmosis. *Ocul Immunol Inflamm*. 2004;12(1):75–77.
22. Mitchell SM, Phylactou L, Fox JD, Kilpatrick MW, Murray PI. The detection of herpesviral DNA in aqueous fluid samples from patients with Fuchs' heterochromic cyclitis. *Ocul Immunol Inflamm*. 1996;4(1):33–38.

23. Babu K, Adiga M, Govekar SR, Kumar BR, Murthy KR. Association of Fuchs heterochromic iridocyclitis in a South Indian patient population. *J Ophthalmic Inflamm Infect*. 2013;3(1):14.
24. Chan NS, Chee SP, Caspers L, Bodaghi B. Clinical features of CMV-associated anterior uveitis. *Ocul Immunol Inflamm*. 2018;26(1):107-115.
25. Quentin CD, Reiber H. Fuchs heterochromic cyclitis: rubella virus antibodies and genome in aqueous humor. *Am J Ophthalmol*. 2004;138(1):46-54.
26. Chee SP, Jap A. Presumed Fuchs heterochromic iridocyclitis and Posner-Schlossman syndrome: comparison of cytomegalovirus-positive and negative eyes. *Am J Ophthalmol*. 2008;146(6):883-889.
27. Kreps EO, Derveaux T, De Keyser F, Kestelyn P. Fuchs' uveitis syndrome: no longer a syndrome? *Ocul Immunol Inflamm*. 2016;24(3):348-357.
28. Cunningham ET Jr, Baglivo E. Fuchs heterochromic iridocyclitis – syndrome, disease, or both? *Am J Ophthalmol*. 2009;148(4):479-481.
29. Jabs DA, Nussenblatt RB, Rosenbaum JT. Standardization of uveitis nomenclature for reporting clinical data. Results of the First International Workshop. *Am J Ophthalmol*. 2005;140(3):509-516.
30. Bloch-Michel E, Nussenblatt RB. International Uveitis Study Group recommendations for the evaluation of ocular inflammatory disease. *Am J Ophthalmol*. 1987;103(2):234-235.
31. Shugaiv E, Tuzun E, Kurtuncu M, et al. Uveitis as a prognostic factor in multiple sclerosis. *Mult Scler*. 2015;21(1):105-107.
32. Abraham A, Nicholson L, Dick A, Rice C, Atan D. Intermediate uveitis associated with MS: Diagnosis, clinical features, pathogenic mechanisms, and recommendation for management. *Neurol Neuroimmunol Neuroinflamm*. 2020;8(1):e909.
33. Mahendradas P, Shetty R, Malathi J, Madhavan HN. Chikungunya virus iridocyclitis in Fuchs' heterochromic iridocyclitis. *Indian J Ophthalmol*. 2010;58(6):545-547.
34. Aggarwal RK, Luck J, Coster DJ. Horner's syndrome and Fuchs' heterochromic uveitis. *Br J Ophthalmol* 1994;78(12):949.
35. Anwar Z, Galor A, Albin TA, Miller D, Perez V, Davis JL. The diagnostic utility of anterior chamber paracentesis with polymerase chain reaction in anterior uveitis. *Am J Ophthalmol*. 2013;155:781-786.
36. Fierz W. Multiple sclerosis: an example of pathogenic viral interaction? *Virology*. 2017;14(1):42.
37. de Groot-Mijnes JD, de Visser L, Rothova A, et al. Rubella virus associated with Fuchs heterochromic iridocyclitis. *Am J Ophthalmol*. 2006;141(1):212-214.
38. Jarius S, Eichhorn P, Franciotta D, et al. The MRZ reaction as a highly specific marker of multiple sclerosis: re-evaluation and structured review of the literature. *J Neurol*. 2017;264(3):453-466.
39. Kodati S, Sen HN. Uveitis and the gut microbiota. *Best Pract Res Clin Rheumatol*. 2019;33(6):101500.
40. Cryan JF, O'Riordan KJ, Sandhu K, Peterson V, Dinan TG. The gut microbiome in neurological disorders. *Lancet Neurol*. 2020;19(2):179-194.