

THERAPY FOR VITREOUS SEEDING CAUSED BY RETINOBLASTOMA. A REVIEW

Kodetová M.¹, Švojgr K.², Širc J.³, Vaněček J.¹, Pochop P.¹

¹Department of Ophthalmology, 2nd Faculty of Medicine, Charles University and Motol University Hospital, Prague, Czech Republic

²Department of Pediatric Hematology and Oncology, 2nd Faculty of Medicine, Charles University and Motol University Hospital, Prague, Czech Republic

³Institute of Macromolecular Chemistry, Academy of Sciences of the Czech Republic, Prague, Czech Republic

The authors of the study declare that no conflict of interests exists in the compilation, theme and subsequent publication of this professional article, and that it is not supported by any pharmaceuticals company. The study has not been submitted to in any other journal or published elsewhere.

Received: March 20, 2023

Accepted: May 3, 2023

Available on-line: July 30, 2023



MUDr. Martina Kodetová
Oční klinika dětí a dospělých 2. LF
UK a FN Motol Praha
V Úvalu 84
150 06 Praha 5
E-mail: martina.kodetova@fnmotol.cz

SUMMARY

Retinoblastoma is the most common primary malignant intraocular tumor in children. Seeding, specifically the dispersion of the tumor into the adjacent compartments, represents a major parameter determining the degree of retinoblastoma according to the International Classification of Retinoblastoma. In this article we focused on vitreous seeding, one of the main limiting factors in the successful "eye preservation treatment" of retinoblastoma. This article presents an overview of the history of vitreous seeding of retinoblastoma, established treatment procedures and new-research modalities. The introduction of systemic chemotherapy in the treatment of retinoblastoma at the end of the 1990s represented a significant breakthrough, which enabled the progressive abandonment of radiotherapy with its attendant side effects. However, the attained concentrations of chemotherapeutics in the vitreous space during systemic chemotherapy are not sufficient for the treatment of vitreous seeding, and the toxic effects of systemic chemotherapy are not negligible. A significant change came with the advent of chemotherapy in situ, with the targeted administration of chemotherapeutic drugs, namely intra-arterial and intravitreal injections, contributing to the definitive eradication of external radiotherapy and a reduction of systemic chemotherapy. Although vitreous seeding remains the most common reason for the failure of intra-arterial chemotherapy, this technique has significantly influenced the original treatment regimen of children with retinoblastoma. However, intravitreal chemotherapy has made the greatest contribution to increasing the probability of preservation of the eyeball and visual functions in patients with advanced findings. Novel local drug delivery modalities, gene therapy, oncolytic viruses and immunotherapy from several ongoing preclinical and clinical trials may represent promising approaches in the treatment of vitreous retinoblastoma seeding, though no clinical trials have yet been completed for routine use.

Key words: retinoblastoma, vitreous seeding, eye preservation treatment, intravitreal chemotherapy

Čes. a slov. Oftal., 80, 2024 No. 3, p. 123–129

INTRODUCTION

Retinoblastoma (Rb) is the most common malignant intraocular tumor in childhood age, with an incidence of 1 in 13844 born children in European countries [1], while in the Czech Republic it is diagnosed on average in 6 to 7 children annually [2]. According to heredity, the pathology is divided into two forms. Hereditary Rb (approximately 40% of cases), characterized by embryonic mutation of the retinoblastoma (Rb1) gene, is usually diagnosed in children at around the age of one year, and the finding may be either bilateral or multifocal, though in 10–15% of cases is only unilateral. The non-hereditary form of Rb mostly afflicts only one eyeball, forms one lesion, and appears more frequently in older children between 1 and 3 years of

age. These patients have a mutated Rb1 gene only in the tumor tissue [3]. The growth of Rb begins with a small, semi-transparent lesion in the sensory part of the retina, after which it progressively takes on a whitish coloring, and a dilated afferent and efferent vessel appears. Upon further growth the tumor leaves the retina, and an exophytic or endophytic image of growth may occur. A very rare form of Rb is diffuse growth of Rb [4,5]. Localized intraocular Rb is divided into groups A to E based on the advanced stage of the pathology according to the ICRB (International Classification of Retinoblastoma), which helps determine the probability of preserving the eyeball, as well as of preserving visual functions [2,6], Table 1. Rb seeding constitutes the dispersion of tumor particles into the adjacent compartments, and is the main parameter for determining

the degree of Rb according to the ICRB (groups C, D and E). Seeding of intraocular Rb may occur into 4 different anatomical localities (Table 2) [7].

In this article we have focused on vitreous seeding. On the basis of morphology, vitreous seeding is divided into 3 groups: dust (Fig. 1), spheres (Fig. 2) and clouds (Fig. 3) [7,8]. These three types differ not only in their morphology, but also in their response to treatment [8]. Vitreous seeding is one of the main limiting factors in the successful “eye-preservation treatment” of retinoblastoma.

THERAPY FOR VITREOUS SEEDING

History

Historically the first recorded treatment of Rb was enucleation of the eyeball. This therapy was proposed a life-preserving procedure by James Wardrop in 1809 [9]. Almost one hundred years later this was followed by external radiotherapy, which represented the first possibility of eye-preservation treatment, thanks to Hilgartner’s demonstration of the radiosensitivity of Rb in 1903 [10]. However, in addition to ocular complications (cataract, irradiation retinopathy, vitreous hemorrhage, glaucoma), external radiotherapy also increases the later effects of the pathology, which are local effects in connection with orbital growth defect, endocrinopathy, secondary brain tumors, post-radiation sarcomas, and in the case of hereditary retinoblastoma the procedure above all increases the risk of secondary malignancies [9]. In recent decades, conservative therapy of retinoblastoma has experienced rapid development. The introduction of systemic chemotherapy (the currently used protocol of six cycles of VEC – Vincristine, Etoposide, Carboplatin) and focal therapy (cryotherapy, transpupillary thermotherapy and brachytherapy) at the end of the 1990s enabled the progressive abandonment of external radiotherapy. The risks of systemic chemotherapy include the onset of secondary leukemias and myelodysplastic syndrome potentiated by eto-

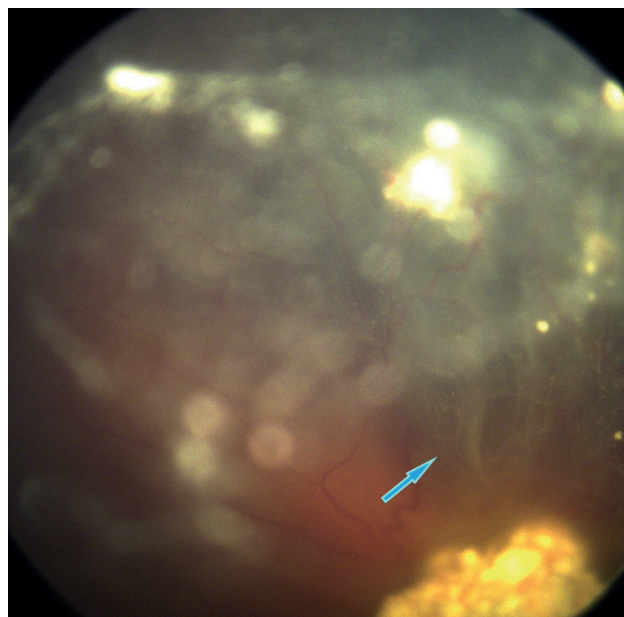


Figure 1. Classification of vitreous seeds: **dust**

Table 2. Four distinct anatomic sites of intra-ocular retinoblastoma [7]

tumor dispersion into the vitreous gel following endophytic disruption of ILM and hyaloid at tumor apex
tumor suspension spreading into the retro-hyaloidal space secondary to endophytic disruption of the ILM at tumor base alone, and partial or complete posterior vitreous detachment
tumor suspension into the subretinal space created by exophytic growth
tumor suspension into the aqueous fluid of the posterior and anterior chambers secondary to disruption of the anterior hyaloid

ILM – internal limiting membrane

Table 1. International Classification of Retinoblastoma (ICRB) [6]

A	Small tumor	Rb ≤ 3 mm in size
B	Large tumor Macula Juxtapapillary Subretinal fluid	Rb > 3mm in size or Macular Rb location (≤ 3 mm to foveola) Juxtapapillary Rb location (≤ 1.5 mm to disc) Clear subretinal fluid (≤ 3 mm from margin)
C	Focal seeds	Subretinal seeds ≤ 3 mm from Rb Vitreous seeds ≤ 3 mm from Rb Both subretinal and vitreous seeds ≤ 3 mm from Rb
D	Diffuse seeds	Subretinal seeds > 3 mm from Rb Vitreous seeds > 3 mm from Rb Both subretinal and vitreous seeds > 3 mm from Rb
E	Extensive Rb	Extensive Rb occupying > 50% of globe or Neovascular glaucoma Opaque media from hemorrhage in anterior chamber, vitreous, or subretinal space Invasion of postlaminar optic nerve, choroid (> 2 mm), sclera, orbit, anterior chamber

Rb - Retinoblastoma

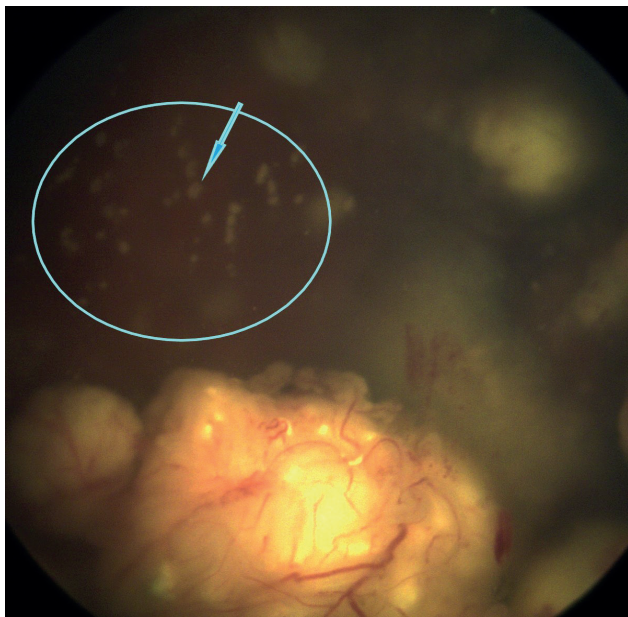


Figure 2. Classification of vitreous seeds: **spheres**

poside [11,12], as well as loss of hearing caused by ototoxic carboplatin [13]. However, the attained concentrations of chemotherapeutics are not sufficient for the treatment of vitreous seeding. A significant change occurred 10 years later, when the advent of chemotherapy in situ with targeted administration of chemotherapeutics by means of intra-arterial, intravitreal and most recently also intracameral injection, significantly increased the probability of preserving the eyeball and visual functions, and thereby contributed to the definitive eradication of external radiotherapy and a reduction of systemic chemotherapy [10].

Super-selective intra-arterial chemotherapy (Ophthalmic artery chemosurgery)

Intra-arterial chemotherapy may also be effective in the treatment of vitreous seeding. However, this therapy is not available in all centers, since it represents a complicated method, requiring an experienced, specialized radiological team [14,15]. Although vitreous seeding remains the most common reason for failure of OAC (ophthalmic artery chemosurgery), this technique has had a marked influence on the original therapeutic schema of children with retinoblastoma. A two-year study conducted by Abramson et al. determined an 83% probability of preservation for eyes with seeding treated by OAC for eyes without any previous treatment, and a 76% probability of preservation for eyes in which treatment by a conventional method had failed [16]. The first attempts to administer an intra-arterial injection in the therapy of Rb were described by Reese et al. in 1958, and subsequently by Kiribuchi, with administration of a triethylenemelamine infusion into the arteria (a) carotis and 5-fluorouracil into the a. frontalis and a. supraorbitalis [17]. Selective intra-arterial therapy has been used in Japan since 1988, and despite several years of experience with a number of

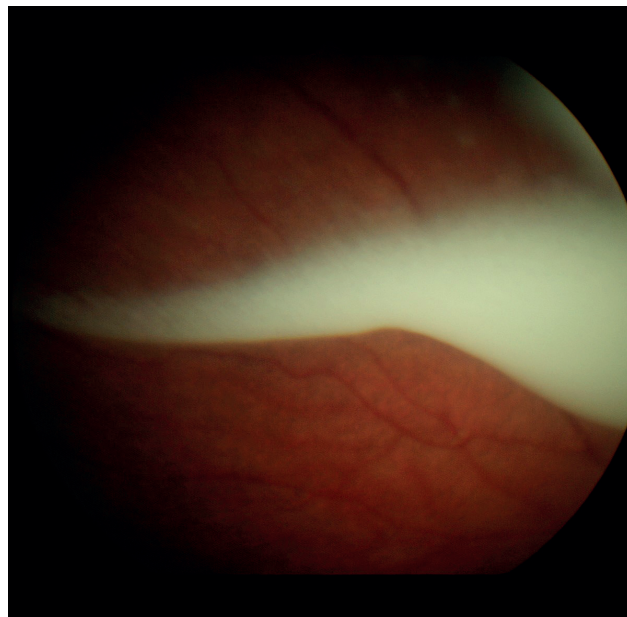


Figure 3. Classification of vitreous seeds: **clouds**

patients exceeding 400, was not expanded to other centers [18,19]. The modern era of OAC began after the introduction of the new technique in 2006 at the Memorial Sloan-Kettering Cancer Center by Abramson and Gobin [20], who described a modified method of super-selective intra-arterial application directly into the arteria ophthalmica (OA), in contrast with the selective intra-arterial application of their Japanese colleagues, in which the infusion of the cytostatic was applied into the a. carotis interna with temporary balloon occlusion of the a. carotis interna (ICA) distally from the OA. The modification according to the American authors is used in retinoblastoma centers to this day. The limit for performance of the procedure is a minimum weight of the child of 6 kg, and a minimum age of 3 months [16]. The procedure is performed under general anesthesia. Cannulation of the a. femoralis is performed, and anticoagulation therapy is administered with Heparin 75IU/kg [21]. A special microcatheter with a diameter of 450 µm is fed through the femoral artery into the ipsilateral ICA and OA, the cytostatic is then applied directly into the OA by infusion for a period of 30 minutes. If a number of chemotherapeutics are administered, a Melphalan infusion is always applied first of all. A limitation of this method may be represented by vascular anomaly, anomaly of spacing of the OA, upon which it is not possible to complete OAC successfully. In rare cases it is not possible to cannulate the OA via the ICA, which may be caused by previous injury to the ostia of the OA, or by small size or anatomical abnormalities; for these cases authors have published the method of cannulation of the a. carotis externa [16].

The chemotherapeutics (CHT) used are melphalan, topotecan and carboplatin, used either in monotherapy or in combination [22]. The most commonly applied is the alkylating cytostatic melphalan, the use of which in pedia-

tric oncology is limited by its severe toxic effects, primarily bone marrow suppression [23]. Munier et al. state a dosage of melphalan of 0.35 mg/kg, not exceeding a dose of 7.5 mg, on average 3 injections at 3-weekly intervals [17]. Another cytostatic, which is administered rather in combination with melphalan, is topotecan, which is ranked among topoisomerase I inhibitors. A clinical trial on intra-arterial therapy in patients with Rb using combined treatment of melphalan 0.5 mg/kg and topotecan 0.5–1 mg demonstrated a good synergic effect without an increase of hematological toxicity in comparison with monotherapy by melphalan [24]. Carboplatin is classed among platin derivatives, and its use in the form of OAC has been connected with an observation of thinning of the retinal vessels, since pharmaceuticals on a platin base have a sclerotizing effect [21]. Abramson et al. stipulated the following initial doses of cytostatic agents for their patients: melphalan 0.4 mg/kg, topotecan 0.2–4 mg and 50 mg of carboplatin [25].

After the procedure we may observe transient eyelid edema [26], hyperemia and chemosis of the conjunctivae [20], or forehead hyperemia, and madarosis [25,26]. Temporary changes in the region of the orbit and ocular adnexa, such as eyelids edema, ptosis, congested orbit with temporary dysfunction of the extraocular muscles, have been described by Shields et al. These complications subsided within the range of 2 to 6 months, in which the longest persisting condition was blepharoptosis, for 4 to 6 months [21]. Several cases of stenosis of the OA, occlusion of the central retinal artery or occlusion of a branch of the retinal artery have been published; however, this depends on the experience of the attending team [17,21,25]. Several authors have described atrophy of the choroid, diffuse or sectoral [17,21]. Abramson et al. also recorded the following in their patients: vitreous hemorrhage, optic nerve swelling, suprachoroidal hemorrhage and in a number of cases also phthisis of the eyeball [25]. Hypotension, bradycardia and bronchospasm were recorded during the procedure in certain cases [25,27], in very rare cases central strokes have been published [28]. In some patients transient cytopenia (neutropenia/thrombocytopenia) has developed, in the majority of cases without the necessity of hospitalization or the administration of transfusion preparations [20,21,25,26].

Intravitreal chemotherapy

Intravitreal chemotherapy (IViC) represents a fundamental breakthrough in the treatment of eyes with vitreous seeding. The first mentions of the use of intravitreal therapy for Rb appeared in 1960, when Ericson and Rosengren used the alkylating cytostatic thiotepa. However, the pioneer of the concept not only of intravitreal but also intra-arterial chemotherapy with the use of melphalan was the Japanese ophthalmologist Akihiro Kaneko [29]. In 2012 a study on the intravitreal application of melphalan was published by Munier et al., supporting the IViC method as a promising therapeutic technique in which preservation of the eyeball was attained in 87% of eyes with active recurrent or persistent seeding, and in 81% of eyes with active vitreous seeding primarily planned for enucleation in order to control the tumor [30]. Munier et

al. defined the method of safe application of an intravitreal injection for Rb, in which procedures are used for preventing the extraocular spreading of tumor cells along the channel of injection [31]. This method was subsequently established also in further specialized retinoblastoma centers. It is important to ensure strict adherence to the indication criteria, including examination of the pars plana region by ultrasound biomicroscopy: 1. transparent optic media, 2. absence of invasion of the tumor into the anterior or posterior chamber, 3. absence of a tumor in the place of injection, 4. absence of vitreous seeding in the place of injection, 5. absence of retinal detachment in the place of application. The procedure is always performed under general anesthesia, in mydriasis and under a surgical microscope. In order to prevent reflux, transient hypotonia of the eyeball is performed by paracentesis of the anterior chamber with a 25G incision on the corneal limbus, without perforation of the Descemet's membrane. A 32G needle on a tuberculin syringe is subsequently guided tangentially to the periphery of the anterior chamber in parallel with the iris, and a sample of intraocular fluid with a volume of 0.1–0.15 ml is aspirated (depending on the planned quantity of applied chemotherapeutic), which we then send for cytopathological examination. We subsequently apply an intravitreal injection in the place of planned application 2.5–3.5 mm from the limbus, depending on the age of the patient using a 32G needle on a tuberculin syringe, perpendicular through the conjunctiva and sclera until it reaches the vitreous cavity. We inject the contents of the syringe as a bolus within 5 s, with visualization of the end of the needle by microscope. In order to prevent the spread of tumor cells along the injection channel we use the method of triple freezing without indentation (6 sec. each cycle) during the course of extraction of the needle. Following the application, we delicately take hold of the eyeball with conjunctival forceps approximately 1 mm from the limbus, and carefully move it around in all directions, thereby ensuring an even distribution of the pharmaceutical within the vitreous cavity [31].

The most commonly used chemotherapeutics for IViC are melphalan and topotecan, frequently in combination [32–35]. From a practical perspective it is important not to overlook spontaneous hydrolysis of the cytostatic, since in the case of melphalan a progressive decrease of activity takes place one hour after the dilution of the pharmaceutical [36]. All the remainder of the diluted solution must be liquidated. In order to alleviate the financial costs pharmacists therefore recommend the storage of an already pre-filled syringe at a temperature of -20 °C; the stability of a cytostatic thus stored is as long as 6 months [37]. Intravitreally administered melphalan manifests retinal toxicity, and may commonly lead to a deterioration or loss of function of the retina [30,32,35]. Melphalan binds well to melanin, and as a result in dark eyes there is a greater disposition to retinal toxicity and therefore also a worse ERG (electroretinography) recording, as well as the finding on the ocular fundus [32,35,38]. In a study conducted by the authors Francis et al., each injection of melphalan was associated with a significant decrease of ERG response, by approximately 5.3–5.8 μ V, increased toxicity was recorded in more pigmented eyes, and upon

administration of intra-arterial chemotherapy at an interval shorter than 1 week from IViC. Retinal toxicity following IViC with melphalan appears fairly promptly, approximately within 1 week, after which it is generally stable and there is no further decrease of ERG amplitude, which also explains the fact that the interval between individual IViCs does not play such a role in increasing the toxicity of the retina [35]. A common side effect is salt and pepper localized retinopathy in the place of injection (sometimes referred to as melphalan pigment epitheliopathy) [35,39,40]. Here there was also an assumption that the repeated application of injections in the same place could lead to an increase of retinal toxicity [35], but this was not confirmed in a study conducted in 2017 [32]. Francis et al. described the toxic effects of intravitreally administered melphalan on the anterior segment in the form of recess of the iris, cataract, depigmentation or thinning of the iris and scleromalacia [41]. Reflux of the vitreous, retinopathy, hemorrhage into the vitreous, endophthalmitis and retinal detachment have also been described in connection with the treatment of retinoblastoma by intravitreal injection [10,42]. Determining the optimal dosage of melphalan has been the subject of several publications. Ghassemi and Shields initially used a melphalan dose of 8 µg/0.1 ml, in which they documented a rapid regression of vitreous seeding with minimal side effects; however, recurrence of seeding occurred. 50 µg of melphalan demonstrated a fast and long-term effect, but in such a high dose pronounced complications were recorded, such as cataract, vitreous hemorrhage, subretinal hemorrhage, severe hypotonia and phthisis of the eyeball leading to enucleation. A dose of 20–30 µg/0.1 ml had a good therapeutic response, without serious side effects [43]. Shields et al. stipulated as standard a dose of 20–30 µg/0.1 ml with an average number of 6 injections [44], which in a further publication they revised to an average of 4 injections of melphalan and 3 injections of topotecan [34]. Munier et al. also inclined towards a dose of melphalan of 20–30 µg. [30].

In contrast with melphalan, topotecan (TPT) has a longer intraocular half-life. In vivo experiments on a rabbit model excluded retinal toxicity following the use of topotecan [45], even upon the use of higher doses (as high as 50 µg per week) [46]. Retinal toxicity of TPT was also not confirmed by the authors of the retrospective study by Nadelmann et al., who used a dose of 20–30 µg for patients with retinoblastoma [47]. Ghassemi et al. examined the effect of a combination of topotecan and melphalan, and determined very good effectiveness of this combination upon a dosage of TPT 20 µg/0.1 ml and 40 µg of melphalan [33]. The German authors Schluter et al. used a dose of 25 µg of melphalan in combination with 20 µg of TPT, in this case eye treatment was combined with brachytherapy [40]. Limited data are available about the effect and toxicity of intravitreally administered carboplatin [48].

The authors of the article recorded a different response to IViC treatment according to the morphological type of seeding. A different regression time of the tumor was observed, as well as the number of applied injections, and the cumulative and average dose of melphalan necessary

for controlling seeding. The dust type manifested a more rapid regression upon a smaller number of injections and lower dose of melphalan, while the opposite applied in the case of the clouds type [8,40]. Classification of seeding may therefore help predict the time, number of injections and dose of melphalan leading to total regression of seeding [11]. Yousef et al. classified the therapeutic response within 3 types: type 0 (complete suppression), type I (calcific seeds) and type II (amorphous seeds) [49].

Periocular therapy

Several authors have assessed the effects of periocular application of CHT on an animal model, with the aim of attaining higher intravitreal concentrations with negligible systemic absorption and zero systemic side effects [50]. In contrast with systemic administration of carboplatin, 10 times higher concentrations were attained in patients with Rb through periocular application, with negligible levels of the cytostatic in the blood [50,51]. A number of scientific groups have attempted local periocular application of CHT (carboplatin, topotecan) in various forms, specifically administration of CHT in depot gel [52], solid polymer [53–55], a system of iontophoresis [56], or a miniature catheter placed on the sclera [51]. However, complete regression of seeding was attained only rarely, and despite the fact that minimal systemic toxicity was attained local adverse effects were frequently recorded, including orbital pseudocellulitis in as many as 50% of cases, optic atrophy and scarring in the periorbital region [57]. In our in vivo experiments with topotecan delivered by episcleral bi-layered hydrogel implant in a rabbit eye model, these local side effects were not recorded [54,55]. At the moment of writing, the first phase of a clinical trial of a new episcleral carrier with topotecan entitled “Chemoplaque” is under way in Canada [58].

Gene therapy and oncolytic virus therapy

Intravitreal application of a suicide gene – the gene herpes thymidine kinase – on an adenovirus carrier, followed by intravenous ganciclovir therapy, was observed in the first phase of a clinical trial on patients with bilateral retinoblastoma and vitreous seeding not responding to standard treatment; control of the tumor was achieved in one out of eight patients [59]. Within the framework of preclinical trials, a conditionally replicating oncolytic adenovirus has been examined by other scientific groups. One of these oncolytic adenoviruses, VCN-01, replicates itself selectively in tumor cells with a high incidence of free E2F-1 (E2F Transcription Factor 1), as a consequence of a dysfunctional Rb1 pathway [60]. The authors assumed that VCN-01 may provide targeted therapeutic activity also in the case of chemo-resistant Rb. Retinoblastoma cells have been successfully destroyed in in vitro experiments. In xenograft retinoblastoma models in mice, necrosis of the tumor and a higher number of preserved eyeballs were achieved following intravitreal administration of VCN-01 in comparison with standard chemotherapy, as well as prevention of metastases into the CNS. On a rabbit immunocompetent model, VCN-01 was not replicated in the retina, and mini-

mal local side effects were recorded, with a minimal short-term transition of the virus into the blood circulation. The initial first phase of the clinical trial demonstrated the feasibility of intravitreal application, the appearance of markers of viral replication in tumor cells, and led to a suppression of vitreous seeding without systemic complications with a local inflammatory reaction in the vitreous body [60].

Immunotherapy

Retinoblastoma cells exprimate the ganglioside GD2 [61,62], monoclonal antibodies anti-GD2 are approved in the treatment of neuroblastoma [63], though as yet there is not sufficient clinical experience for their use in the treatment of Rb. GD2 together with the adhesive neural cell glycoprotein CD171, which is also highly exprimated on the surface of Rb cells, are the target for modern therapy using CART (chimeric antigen receptor T) cells. The application of these two types of cells had a cytotoxic effect on the cellular lines of retinoblastoma [64]. Further scientific groups subsequently developed local immunotherapy founded upon GD2 CART cells. In order to increase stability, the cells were applied intravitreally in hydrogel. In orthoptic xenograft animal models a complete regression of the tumor was recorded, without signs of recurrence or toxicity for the eye [65].

CONCLUSION

In recent decades we have witnessed the development of new therapeutic methods, which have significantly increased the probability of preserving the eye and in some cases also visual functions in patients suffering from retinoblastoma with an advanced finding. In the case of dissemination of the tumor in the vitreous space, the technique of IViC has been primarily responsible for this improvement. Despite the indisputable effectiveness of this therapy, work is still continuing on the development of new therapeutic techniques which could attain the same effect without the necessity of perforating the patient's sclera. Some oncologists and ophthalmologists consider transscleral application of a cytostatic into the eye of a patient with a malignant tumor to be a somewhat risk-laden procedure with regard to the generalization of the pathology, even despite all the measures that are applied accompanying such treatment. Several different therapeutic procedures have been proposed in order to attain an adequate concentration of cytostatic agents by other means, and some of these methods appear to be promising. Nevertheless, it shall still be necessary to conduct further series of tests which demonstrate their indisputable safety and efficacy, in order for the routine and widespread use of these methods to become feasible.

REFERENCES

1. Stacey AW, Bowman R, Foster A, et al. Global Retinoblastoma Study Group. Incidence of Retinoblastoma Has Increased: Results from 40 European Countries. *Ophthalmology*. 2021 Sep;128(9):1369-1371.
2. Švojgr K. Retinoblastom, *Onkologie* 2016;10(5):215-217.
3. Abramson DH, Scheffer AC. Update on retinoblastoma. *Retina*. 2004 Dec;24(6):828-848.
4. Shields JA, Shields CL. Intraocular tumors: atlas and textbook. 2nd ed. Philadelphia: Lippincott Williams & Wilkins, a Wolters Kluwer business; 2008. Chapter 15. Retinoblastoma: Introduction, Genetics, Clinical Features, Classification; 294-295.
5. Shields JA, Shields CL, Materin M. Diffuse infiltrating retinoblastoma presenting as a spontaneous hyphema. *J Pediatr Ophthalmol Strabismus* 2000;37:311-312.
6. Shields CL, Mashayekhi A, Au AK, et al. The International Classification of Retinoblastoma predicts chemoreduction success, *Ophthalmology* 2006;113:2276-2280.
7. Munier FL. Classification and management of seeds in retinoblastoma. Ellsworth Lecture Ghent August 24th 2013. *Ophthalmic Genet*. 2014 Dec;35(4):193-207.
8. Francis JH, Abramson DH, Gaillard MC, Marr BP, Beck-Popovic M, Munier FL. The classification of vitreous seeds in retinoblastoma and response to intravitreal melphalan. *Ophthalmology*. 2015 Jun;122(6):1173-1179.
9. Abramson DH. Retinoblastoma in the 20th century: past success and future challenges the Weisenfeld lecture. *Invest Ophthalmol Vis Sci*. 2005 Aug;46(8):2683-2691.
10. Munier FL, Beck-Popovic M, Chantada GL, et al. Conservative management of retinoblastoma: Challenging orthodoxy without compromising the state of metastatic grace. "Alive, with good vision and no comorbidity". *Prog Retin Eye Res*. 2019 Nov;73:100764.
11. Rizzuti AE, Dunkel IJ, Abramson DH. The adverse events of chemotherapy for retinoblastoma: what are they? Do we know? *Arch Ophthalmol*. 2008 Jun;126(6):862-865.
12. Weintraub M, Revel-Vilk S, Charit M, Aker M, Pe'er J. Secondary acute myeloid leukemia after etoposide therapy for retinoblastoma. *J Pediatr Hematol Oncol*. 2007 Sep;29(9):646-648.
13. Qaddoumi I, Bass JK, Wu J, et al. Carboplatin-associated ototoxicity in children with retinoblastoma. *J Clin Oncol*. 2012 Apr;30(10):1034-1041.
14. Abramson DH, Marr BP, Dunkel IJ, et al. Intra-arterial chemotherapy for retinoblastoma in eyes with vitreous and/or subretinal seeding: 2-year results. *Br J Ophthalmol*. 2012 Apr;96(4):499-502.
15. Francis JH, Abramson DH, Gobin YP, et al. Electoretinogram monitoring of dose-dependent toxicity after ophthalmic artery chemosurgery in retinoblastoma eyes: six year review. *PLoS One*. 2014 Jan 20;9(1):e84247.
16. Abramson DH. Retinoblastoma: saving life with vision. *Annu Rev Med*. 2014;65:171-184.
17. Munier FL, Beck-Popovic M, Balmer A, Gaillard MC, Bovey E, Binaghi S. Occurrence of sectoral choroidal occlusive vasculopathy and retinal arteriolar embolization after superselective ophthalmic artery chemotherapy for advanced intraocular retinoblastoma. *Retina*. 2011 Mar;31(3):566-573.
18. Suzuki S, Yamane T, Mohri M, Kaneko A. Selective ophthalmic arterial injection therapy for intraocular retinoblastoma: the long-term prognosis. *Ophthalmology*. 2011 Oct;118(10):2081-2087.
19. Schaiquevich P, Francis JH, Cancela MB, Carcaboso AM, Chantada GL, Abramson DH. Treatment of Retinoblastoma: What Is the Latest and What Is the Future. *Front Oncol*. 2022 Apr 1;12:822330.
20. Abramson DH, Dunkel IJ, Brodie SE, Kim JW, Gobin YP. A phase I/II study of direct intraarterial (ophthalmic artery) chemotherapy with melphalan for intraocular retinoblastoma initial results. *Ophthalmology*. 2008 Aug;115(8):1398-404, 1404.e1.
21. Shields CL, Bianciotto CG, Jabbour P, et al. Intra-arterial chemotherapy for retinoblastoma: report No. 2, treatment complications. *Arch Ophthalmol*. 2011 Nov;129(11):1407-1415.
22. Abramson DH. Super selective ophthalmic artery delivery of chemotherapy for intraocular retinoblastoma: 'chemosurgery' the first Stallard lecture. *Br J Ophthalmol*. 2010 Apr;94(4):396-399.
23. Inomata M, Kaneko A. Chemosensitivity profiles of primary and cultured human retinoblastoma cells in a human tumor clonogenic assay. *Jpn J Cancer Res* 1987;78:858-868.
24. Taich P, Ceciliano A, Buitrago E, et al. Clinical pharmacokinetics of intra-arterial melphalan and topotecan combination in patients with retinoblastoma. *Ophthalmology*. 2014 Apr;121(4):889-897.
25. Abramson DH, Daniels AB, Marr BP, et al. Intra-Arterial Chemotherapy (Ophthalmic Artery Chemosurgery) for Group D Retinoblastoma. *PLoS One*. 2016 Jan 12;11(1):e0146582.

26. Abramson DH, Dunkel IJ, Brodie SE, Marr B, Gobin YP. Superselective ophthalmic artery chemotherapy as primary treatment for retinoblastoma (chemosurgery). *Ophthalmology*. 2010 Aug;117(8):1623-1629.
27. Scharoun JH, Han JH, Gobin YP. Anesthesia for Ophthalmic Artery Chemosurgery. *Anesthesiology*. 2017 Jan;126(1):165-172.
28. De la Huerta I, Seider MI, Hetts SW, Damato BE. Delayed Cerebral Infarction Following Intra-arterial Chemotherapy for Retinoblastoma. *JAMA Ophthalmol*. 2016 Jun 1;134(6):712-714.
29. Kaneko A, Suzuki S. Eye-preservation treatment of retinoblastoma with vitreous seeding. *Jpn J Clin Oncol*. 2003 Dec;33(12):601-607.
30. Munier FL, Gaillard MC, Balmer A, et al. Intravitreal chemotherapy for vitreous disease in retinoblastoma revisited: from prohibition to conditional indications. *Br J Ophthalmol*. 2012 Aug;96(8):1078-1083.
31. Munier FL, Soliman S, Moulin AP, Gaillard MC, Balmer A, Beck-Popovic M. Profiling safety of intravitreal injections for retinoblastoma using an anti-reflux procedure and sterilisation of the needle track. *Br J Ophthalmol*. 2012 Aug;96(8):1084-1087.
32. Francis JH, Brodie SE, Marr B, Zabor EC, Mondesire-Crump I, Abramson DH. Efficacy and Toxicity of Intravitreal Chemotherapy for Retinoblastoma: Four-Year Experience. *Ophthalmology*. 2017 Apr;124(4):488-495.
33. Ghassemi F, Shields CL, Ghadimi H, Khodabandeh A, Roohipour R. Combined intravitreal melphalan and topotecan for refractory or recurrent vitreous seeding from retinoblastoma. *JAMA Ophthalmol*. 2014 Aug;132(8):936-941.
34. Shields CL, Douglass AM, Beggache M, Say EA, Shields JA. Intravitreal chemotherapy for active vitreous seeding from retinoblastoma: Outcomes After 192 Consecutive Injections. The 2015 Howard Naquin Lecture. *Retina*. 2016 Jun;36(6):1184-1190.
35. Francis JH, Schaiquevich P, Buitrago E, et al. Local and systemic toxicity of intravitreal melphalan for vitreous seeding in retinoblastoma: a pre-clinical and clinical study. *Ophthalmology*. 2014 Sep;121(9):1810-1817.
36. Schaiquevich P, Francis JH, Cancela MB, Carcaboso AM, Chantada GL, Abramson DH. Treatment of Retinoblastoma: What Is the Latest and What Is the Future. *Front Oncol*. 2022 Apr 1;12:822330.
37. Buitrago E, Lagomarsino E, Mato G, Schaiquevich P. Stability of Melphalan Solution for Intravitreal Injection for Retinoblastoma. *JAMA Ophthalmol*. 2014;132(11):1372-1373.
38. Francis JH, Marr BP, Abramson DH. Classification of Vitreous Seeds in Retinoblastoma: Correlations with Patient, Tumor, and Treatment Characteristics. *Ophthalmology*. 2016 Jul;123(7):1601-1605.
39. Smith SJ, Smith BD, Mohney BG. Ocular side effects following intravitreal injection therapy for retinoblastoma: a systematic review. *Br J Ophthalmol*. 2014 Mar;98(3):292-297.
40. Schlüter S, Bornfeld N, Valiyev E, et al. Combination of Brachytherapy and Intravitreal Chemotherapy in the Treatment of Retinoblastoma with Vitreous Seeding. *Ocul Oncol Pathol*. 2022 Feb;8(1):64-70.
41. Francis JH, Marr BP, Brodie SE, Abramson DH. Anterior Ocular Toxicity of Intravitreal Melphalan for Retinoblastoma. *JAMA Ophthalmol*. 2015 Dec;133(12):1459-1463.
42. Francis JH, Abramson DH, Ji X, et al. Risk of Extraocular Extension in Eyes With Retinoblastoma Receiving Intravitreal Chemotherapy. *JAMA Ophthalmol*. 2017 Dec 1;135(12):1426-1429.
43. Ghassemi F, Shields CL. Intravitreal melphalan for refractory or recurrent vitreous seeding from retinoblastoma. *Arch Ophthalmol*. 2012 Oct;130(10):1268-1271.
44. Shields CL, Manjandavida FP, Arepalli S, Kaliki S, Lally SE, Shields JA. Intravitreal melphalan for persistent or recurrent retinoblastoma vitreous seeds: preliminary results. *JAMA Ophthalmol*. 2014 Mar;132(3):319-325.
45. Buitrago E, Del Sole MJ, Torbidoni A, et al. Ocular and systemic toxicity of intravitreal topotecan in rabbits for potential treatment of retinoblastoma. *Exp Eye Res*. 2013 Mar;108:103-109.
46. Del Sole MJ, Clausse M, Nejamkin P, et al. Ocular and systemic toxicity of high-dose intravitreal topotecan in rabbits: Implications for retinoblastoma treatment. *Exp Eye Res*. 2022 May;218:109026.
47. Nadelmann J, Francis JH, Brodie SE, Muca E, Abramson DH. Is intravitreal topotecan toxic to retinal function? *Br J Ophthalmol*. 2021 Jul;105(7):1016-1018.
48. Smith SJ, Pulido JS, Salomão DR, Smith BD, Mohney B. Combined intravitreal and subconjunctival carboplatin for retinoblastoma with vitreous seeds. *Br J Ophthalmol*. 2012 Aug;96(8):1073-1077.
49. Yousef YA, Al Jboor M, Mohammad M, et al. Safety and Efficacy of Intravitreal Chemotherapy (Melphalan) to Treat Vitreous Seeds in Retinoblastoma. *Front Pharmacol*. 2021 Jul 12;12:696787.
50. Mendelsohn M, Abramson DH, Madden T, et al. Intraocular concentrations of chemotherapeutic agents after systemic or local administration. *Arch Ophthalmol*. 1998;116:1209-1212.
51. Abramson DH, Frank CM, Dunkel IJ. A phase I/II study of subconjunctival carboplatin for intraocular retinoblastoma. *Ophthalmology*. 1999;106:1947-1950.
52. Martin NE, Kim JW, Abramson DH. Fibrin sealant for retinoblastoma: where are we? *J Ocul Pharmacol Ther*. 2008 Oct;24(5):433-438.
53. Carcaboso AM, Chiappetta DA, Opezzo JA, et al. Episcleral implants for topotecan delivery to the posterior segment of the eye. *Invest Ophthalmol Vis Sci*. 2010 Apr;51(4):2126-2134.
54. Hobzova R, Kodetova M, Pochop P, et al. Hydrogel implants for transscleral diffusion delivery of topotecan: In vivo proof of concept in a rabbit eye model. *Int J Pharm*. 2021 Sep 5;606:120832.
55. Kodetova M, Hobzova R, Sirc J, et al. The Role of Cryotherapy in Vitreous Concentrations of Topotecan Delivered by Episcleral Hydrogel Implant. *Pharmaceutics*. 2022 Apr 20;14(5):903.
56. Hayden BC, Jockovich ME, Murray TG, et al. Pharmacokinetics of systemic versus focal Carboplatin chemotherapy in the rabbit eye: possible implication in the treatment of retinoblastoma. *Invest Ophthalmol Vis Sci*. 2004 Oct;45(10):3644-3649.
57. Schmack I, Hubbard GB, Kang SJ, et al. Ischemic necrosis and atrophy of the optic nerve after periocular carboplatin injection for intraocular retinoblastoma. *Am J Ophthalmol*. 2006;142:310-315.
58. National Library of Medicine. Topotecan Episcleral Plaque for Treatment of Retinoblastoma – Full Text (2020). *ClinicalTrials.gov*. Available from: <https://clinicaltrials.gov/ct2/show/NCT04428879> (Accessed October 26, 2021)
59. Chévez-Barrios P, Chintagumpala M, Mieler W, et al. Response of retinoblastoma with vitreous tumor seeding to adenovirus-mediated delivery of thymidine kinase followed by ganciclovir. *J Clin Oncol*. 2005 Nov 1;23(31):7927-7935.
60. Pascual-Pasto G, Bazan-Peregrino M, Olaciregui NG, et al. Therapeutic targeting of the RB1 pathway in retinoblastoma with the oncolytic adenovirus VCN-01. *Sci Transl Med*. 2019 Jan 23;11(476):eaat9321.
61. Laurent VE, Otero LL, Vazquez V, et al. Optimization of molecular detection of GD2 synthase mRNA in retinoblastoma. *Mol Med Rep*. 2010 Mar-Apr;3(2):253-259.
62. Chantada GL, Rossi J, Casco F, et al. An aggressive bone marrow evaluation including immunocytology with GD2 for advanced retinoblastoma. *J Pediatr Hematol Oncol*. 2006 Jun;28(6):369-373.
63. Mora J. Dinutuximab for the treatment of pediatric patients with high-risk neuroblastoma. *Expert Rev Clin Pharmacol*. 2016;9(5):647-653.