

# PROSPECTS FOR CELL THERAPY IN OPHTHALMOLOGY

## 1. USE OF STEM CELLS IN REGENERATION OF THE DAMAGED OCULAR SURFACE

### SUMMARY

Regeneration of corneal epithelium is secured by a population of limbal stem cells (LSC), which are located in the basal part of the limbal epithelium. Deficiency in LSC leads to chronic inflammation, scarring and conjunctivization of cornea. Therapy of LSC deficiency consists in transplantation of limbal tissue, cultivated limbal epithelium or more recently in transplantation of autologous cells including mesenchymal stem cells, oral mucosal epithelial cells or hair follicle-derived stem cells. A significant progress has been achieved in the field of cell therapy and also in the development of convenient scaffolds for the growth and transfer of cells on damaged cornea.

**Key words:** ocular surface damage, stem cells, cell therapy

*Čes. a slov. Oftal., 72, 2016, No. 1, p. 268–271*

### INTRODUCTION

Sight is our most important physical sense, by means of which we obtain approximately 4/5 of all our information about our surroundings. The ocular surface is protected by the cornea, which mediates the transmission of light rays to the retina. Reduction of the transparency of the cornea as a consequence of damage or pathology may lead to a deterioration of vision and in extreme cases to total blindness. As a result, regeneration of the cornea and renewal of the corneal epitheliums have been and continue to be the subject of intensive study, in which there is a search primarily for therapeutic procedures which could offer an alternative to corneal transplant or limbal grafts. Such an alternative could be represented by the renewal of the corneal epithelium with the help of transplantation of various types of stem cells. These can often be obtained directly from the affected patient as autologous cells, thus avoiding complications in connection with the use of allogeneic material, in which it is simultaneously necessary to apply immunosuppressive therapy in connection with frequent adverse side effects

#### Stem cells

Stem cells represent a population of undifferentiated cells, the properties of which include a slow cell cycle, high proliferation capacity as a result of activation, ability of unlimited cell division and also the ability to generate at least one type of highly specialised daughter cells. There are usually intermediary stages between stem cells and terminally differentiated cells, in which these cells are capable of proliferation and differentiation only to a limited extent (22).

Stem cells can be divided into embryonic cells and cells of the adult organism. Separate categories are then formed by stem cells from the umbilical blood of a newborn child and induced pluripotent stem cells, which are prepared experimentally by the introduction of a set of specific genes into somatic cells.

#### Limbal stem cells and regeneration of the corneal epithelium

As the surface structure of the eye, the cornea is constantly exposed to various influences of the external environment, including dehydration, infections and the risk of damage of a mechanical or chemical character.

Constant regeneration of the corneal epithelium is ensured by a population of limbal stem cells (LSC) located in the basal layer of the limbal epithelium, in a structure called the Vogt's striae. This structure provides the LSCs with a unique micro-environment which ensures their protection against adverse environmental impacts and harmful UV radiation, and at the same time the present vascular supply ensures provision of the necessary nutrients and supportive factors. LSCs are distinguished by their slow cell cycle and high proliferative capacity, which can be generated as a response to corneal damage. Since no unique attribute which would be expressed only by the LSC population has been located to date, they are characterised most often using a combination of attributes associated with stem cells such as transcription factor p63, receptor protein Lgr5 and membrane transporter ABCG2 (ATP-binding cassette transporter group 2 protein). At the same time, cells bearing differentiation attributes associated with the corneal epithelium, including keratins 3 and 12, must be excluded (4). Certain attributes characteristic of the populati-

Javorková E., Holáň V.

Institute of Experimental Medicine,  
Academy of Sciences of the Czech Republic,  
Department of Transplant Immunology,  
Videňská 1083, 142 20 Praha 4.  
Head of Department prof. RNDr. Vladimír  
Holáň, DrSc.

*The authors of the study declare that no conflict of interests exists in the compilation and subsequent publication of this academic communication, and that it is not supported by any pharmaceuticals company.*



Mgr. Eliška Javorková, Ph.D.  
Institute of Experimental Medicine,  
Academy of Sciences of the Czech Republic,  
Department of Transplant Immunology,  
Videňská 1083, 142 20 Praha 4  
e-mail: javorkova@biomed.cas.cz

on of LSC, such as their small size and the presence of transporter ABCG2, are used in their isolation by centrifugation on a density gradient or on the basis of effluxion of the fluorescence stain Hoechst 33342 (14).

LSCs therefore ensure the natural regeneration of the corneal epithelium and thus compensate minor damages to the cornea as a result of its everyday exposure to influences of the external environment. However, a problem arises at the moment when more extensive damage to the ocular surface takes place, also affecting the limbal region, which in certain cases may lead to a deficit of LSCs and thus to a fundamental impairment of the process of regeneration of the corneal epithelium.

### **LSC deficit and treatment thereof**

LSC deficit may have a whole range of causes, which can be divided into two basic groups, namely primary and acquired. The first group includes for example aniridia and multiple endocrine deficit. Acquired pathologies are more frequent and incorporate for example ocular pemphigoid, Stevens-Johnson syndrome or repeated eye surgery. Further causes may include microbial infection, chronic allergies or chemical burning of the cornea as a consequence of incautious handling of caustic substances, or more extensive mechanical damages.

Important criteria for the possibilities of treatment and the applicable prognosis primarily concern whether the damage or pathology of the eye is unilateral or bilateral, and further whether the LSC deficit is partial or complete. An LSC deficit then leads to impairment of the self-regeneration of the cornea, chronic inflammations and finally to its scarring and conjunctivisation.

One of the options in the treatment of a general unilateral LSC deficit is the transplantation of limbal tissue from the healthy eye of the patient. The disadvantage of this approach is the risk of acquired LSC deficit in the originally healthy donor eye as a consequence of taking the limbal transplant. The first more extensive trial using this approach was conducted in 1989 by Kenyon et al., in which 26 patients suffering from LSC deficit caused primarily by chemical or thermal damage were treated. The therapy incorporated the transfer of 2 pieces of limbal tissue from the patient's undamaged or at least less damaged eye. Patients were observed for over a year and a half, and an improvement of vision, faster healing, an absence of epithelial defects, a halting or even regression of corneal neovascularisation was achieved in more than half, and cytology confirmed regeneration of the corneal epithelial phenotype (13).

An alternative to transplantation of the entire limbal tissue is represented by transplantation of laboratory cultivated limbal cells prepared from a very small limbal biopsy. The first trial using this procedure was a study by Pellegrini et al. from 1997, observing the possibility of regeneration of a damaged cornea in two patients with a burned ocular surface through the use of an autologous epithelial layer obtained by serial cultivation of limbal cells from a small limbal biopsy with a size of 1 mm<sup>2</sup> from the healthy eye. After transplantation the limbal cells in both patients formed a

compact layer of the corneal epithelium, and stable renewal of the corneal epithelium was achieved, persisting for 2 years after transplantation (17).

Since 1997 more than 1000 transplants of cultivated limbal epitheliums have been performed worldwide. The main criterion in evaluating the success of therapy is the presence of a stable surface without corneal vascularisation and conjunctivisation. A summary analysis of 18 studies, within the framework of which almost 600 patients were treated, has demonstrated that transplantation of an epithelium cultivated from a limbal biopsy on an amnion membrane is an effective method of treatment for patients with an LSC deficit. In approximately 60% of cases there was an improvement of vision, in which the success of treatment did not depend on whether this concerned autologous or allogeneic tissue. In an evaluation of the safety of treatment it was determined that the majority of side effects of this therapy were only transitional (24).

### **Cultivation and transmission of LSCs for therapy of LSC deficit**

Two main strategies are used in the acquisition and cultivation of LSCs. The first approach is an explantation technique, in which an entire limbal biopsy is cultivated. In the second approach, individual LSCs are isolated from limbal tissue with the help of enzymatic digestion. However, cultivation of cells acquired by this method usually requires the use of nutrient layers such as inactivated fibroblasts. In order to support the expansion and maintenance of LSCs within the culture an amnion membrane is also frequently used, which subsequently serves also as a scaffold of stem cells upon transplantation onto the ocular surface.

Since the beginning of the 20th century an amnion membrane has been used in the treatment of skin burns. In ophthalmology it has long been used in the treatment of conjunctival defects, and in the 1990s its use was extended also to the region of the cornea. The main reasons are its anti-inflammatory and antimicrobial effects, together with low immunogenicity. An amnion membrane has the capacity to reduce the inflammatory response and scarring of the ocular surface following its damage, and at the same time supports re-epithelisation thanks to the presence of growth factors and its antimicrobial properties (6).

In recent years a range of new biocompatible materials have been developed in an endeavour to facilitate the transmission of LSCs in the treatment of ocular defects, including fibrin gel (16), collagen scaffolds (3), hydrogels composed of compounds of chitosan with collagen or elastin (8), translucent layers of hair keratin (5), various forms of contact lenses carrying stem cells (1) or various types of nanofibre scaffolds (23, 9, 2) prepared most often from natural polymers such as chitosan and collagen, or from synthetic polymers such as polyamide or polyvinyl alcohol.

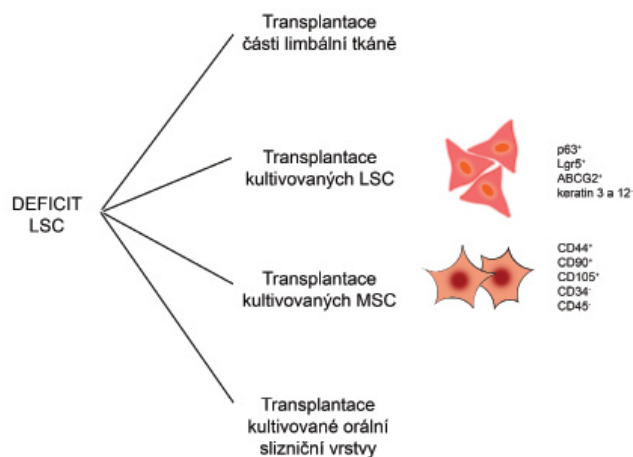
### **Further types of cells utilised in the treatment of LSC deficit**

An alternative to transplantation of autologous LSCs, which cannot be used for example in the case of a bilateral LSC deficit, is represented by therapeutic procedures using other types of stem cells. These may be obtained directly

from the patient's organism, multiplied in tissue cultures and used as autologous cells for the regeneration of a damaged cornea. Encouraging results have been achieved especially upon the use of mesenchymal stem cells (MSCs), epithelial cells of the oral mucosa or hair follicle-derived stem cells. At present it is precisely MSCs that are the subject of the most intensive study in connection with the regeneration and repair of the corneal epithelium. Some therapeutic approaches for the treatment of LSC deficit are illustrated in fig. 1.

### Mesenchymal stem cells

MSCs are used primarily due to their relatively easy availability, the possibility of their multiplication in tissue cultures,



**Obr. 1 Potential therapeutic approaches in the treatment of LSC deficit. In the treatment of LSC deficit parts of limbal tissue or laboratory cultivated LSCs, MSCs or oral mucosal layer may be transplanted.**

their capability of differentiation into epithelial cells and for their immunomodulation properties, enabling the suppression of adverse inflammatory immune responses in the damaged cornea (9, 2).

MSCs were first described in 1966 in a study by Friedenstein et al., demonstrating the presence of cells with osteogenic potential in suspension obtained from bone marrow. Since then the presence of MSCs has been demonstrated in a whole range of organs and tissues, although bone marrow remains amongst the most widely used sources of these cells, and in recent years also fat tissue and umbilical blood have been used. During cultivation in vitro, MSCs are distinguished by their spindle shape and adherence to the base. As in the case of LSCs, for MSCs also no attribute has been located which is unique only for this population. However, MSCs may be characterised by a combination of expression of positive attributes, which include the molecules CD44, CD90 and CD105, as well as the absence of the leukocyte attributes CD34 or CD45. At the same time, cells carrying these attributes should be capable of differentiation into adipocytes, osteocytes and chondrocytes. In actual practice, however, the differentiation potential of MSCs is far more extensive, and incorporates the ability to differentiate into cells forming mesodermal tissue and also the capability of transdifferentiation

into cells forming endodermal and ectodermal tissue. Furthermore MSCs have extensive immunomodulation properties, which also influence the natural and adaptive component of the immune system (21, 20).

Ma et al. were the first to demonstrate that human MSCs transplanted with the help of an amnion membrane to a damaged cornea of a laboratory rat can support the healing and renewal of the corneal epithelium. The therapeutic effect was linked primarily with the suppression of inflammation and angiogenesis (15). In another study MSCs were used on rats, after incubation with corneal stromal cells expressing keratin 12, which is an attribute of cells of the corneal epithelium. These cells were transferred to the damaged cornea with the help of an amnion membrane, and 4 weeks after application reduced the opacity and neovascularisation of the cornea (12).

According to the results of our group, intravenously administered MSCs are capable of specific migration to the damaged cornea and of contributing here to suppressing the early phase of corneal inflammation following burning of the cornea by sodium hydroxide. In comparison with a healthy eye, a 30 times higher quantity of fluorescence marked MSCs was found in the damaged cornea, and at the same time there was also a reduction of infiltration of the cornea by leukocytes and suppression of production of proinflammatory cytokines, including IL-1 and IL-6 (11). In a further study we demonstrated that MSCs have comparable therapeutic potential with LSCs, and after transfer to the ocular surface support the regeneration of the corneal epithelium and suppress local inflammatory reaction in the place of damage (10).

At present two clinical trials using MSCs for the treatment of corneal damage are listed on the website [www.clinicaltrials.gov](http://www.clinicaltrials.gov). One is taking place in Spain, within the framework of which 27 patients suffering from LSC deficit are being treated. It concerns a phase 1 and 2 clinical trial, the main aim of which is to determine whether transplantation of allogeneic MSCs is safe and effective in the treatment of LSC deficit in comparison with treatment with the help of allogeneic LSCs.

The second study, which is to be commenced in 2015, shall take place in China, and the estimated number of treated patients with a chemically damaged cornea should be around 100. It will concern a phase 2 clinical trial focusing on safety and efficacy of treatment by means of repeated doses of MSCs administered by means of subconjunctival injection.

### Oral mucosal epithelial cells

Another cell type tested for reconstruction of the damaged corneal epithelium is epithelial cells of the oral mucosa, which could be suitable because they manifest structural similarities to other layered epitheliums.

The first study using these cells was conducted by Gipson et al. in 1986, in which treatment using the oral epithelial layer was tested on a rabbit model. It was determined that 4 months after transplantation the eye was still without signs of inflammatory response (7).

Very interesting results were presented by two studies, in which a total of 49 patients suffering from LSC deficit as a consequence of Stevens-Johnson syndrome, ocular pemphigoid or burning of the eye were treated with the help of transplantation of a cultivated oral mucosal layer on an amnion membrane. Improvement of visual acuity took place six months after treatment, primarily in patients suffering from Stevens-Johnson syndrome, whilst in the case of pemphigoid an improvement took place only one month after surgery. In all patients there was a reduction of the incidence of abnormalities on the ocular surface, and overall a long-term improvement of visual acuity was achieved in half of the patients (18, 19).

## CONCLUSION

In the last two decades there has been considerable development in the therapeutic approach in the treatment of LSC deficit. In certain cases clinical trials have been conducted which have produced encouraging results. These trials are currently focused primarily on the use of cultivated LSCs and more recently various types of MSCs which may replace LSCs in the case of their deficiency.

*Práce byla podpořena projektem NPU LO1309 z Ministerstva školství, mládeže a tělovýchovy České republiky.*

## LITERATURE

1. **Brown, K.D., Low, S., Mariappan, I. et al.:** Plasma polymer-coated contact lenses for the culture and transfer of corneal epithelial cells in the treatment of limbal stem cell deficiency. *Tissue Eng*, 20; 2014: 646–655.
2. **Cejkova, J., Trosan, P., Cejka, C. et al.:** Suppression of alkali-induced oxidative injury in the cornea by mesenchymal stem cells growing on nanofiber scaffolds and transferred onto the damaged corneal surface. *Exp Eye Res*, 116; 2013: 312–323.
3. **Dravida, S., Gaddipati, S., Griffith, M. et al.:** A biomimetic scaffold for culturing limbal stem cells: a promising alternative for clinical transplantation. *J Tissue Eng Regen Med*, 2; 2008: 263–271.
4. **Echevarria, T.J., Di Girolamo, N.:** Tissue-regenerating, vision-restoring corneal epithelial stem cells. *Stem Cell Rev*, 7; 2011: 256–268.
5. **Feng, Y., Borrelli, M., Meyer-Ter-Vehn, T. et al.:** Epithelial wound healing on keratin film, amniotic membrane and polystyrene in vitro. *Curr Eye Res*, 39; 2014: 561–570.
6. **Fernandes, M., Sridhar, M.S., Sangwan, V.S. et al.:** Amniotic membrane transplantation for ocular surface reconstruction. *Cornea*, 24; 2005: 643–653.
7. **Gipson, I.K., Geggel, H.S., Spurr-Michaud, S.J.:** Transplant of oral mucosal epithelium to rabbit ocular surface wounds in vivo. *Arch Ophthalmol*, 104; 1986: 1529–1533.
8. **Grolík, M., Szczubiałka, K., Wowra, B. et al.:** Hydrogel membranes based on genipin-cross-linked chitosan blends for corneal epithelium tissue engineering. *J Mater Sci Mater Med*, 23; 2012: 1991–2000.
9. **Holan, V., Javorkova, E.:** Mesenchymal stem cells, nanofiber scaffolds and ocular surface reconstruction. *Stem Cell Rev*, 9; 2013: 609–619.
10. **Holan, V., Trosan, P., Cejka, C. et al.:** A comparative study of the therapeutic potential of mesenchymal stem cells and limbal epithelial stem cells for ocular surface reconstruction. *Stem Cells Transl Med*, 4; 2015: 1052–1063.
11. **Javorkova, E., Trosan, P., Zajicova, A. et al.:** Modulation of the early inflammatory microenvironment in the alkali-burned eye by systemically administered interferon- $\gamma$ -treated mesenchymal stromal cells. *Stem Cells Dev*, 23; 2014: 2490–2500.
12. **Jiang, T.S., Cai, L., Ji, W.Y. et al.:** Reconstruction of the corneal epithelium with induced marrow mesenchymal stem cells in rats. *Mol Vis*, 16; 2010: 1304–1316.
13. **Kenyon, K.R., Tseng, S.C.:** Limbal autograft transplantation for ocular surface disorders. *Ophthalmology*, 96; 1989: 709–722.
14. **Krulova, M., Pokorna, K., Lencova, A. et al.:** A rapid separation of two distinct populations of mouse corneal epithelial cells with limbal stem cell characteristics by centrifugation on percoll gradient. *Invest Ophthalmol Vis Sci*, 49; 2008: 3903–3908.
15. **Ma, Y., Xu, Y., Xiao, Z. et al.:** Reconstruction of chemically burned rat corneal surface by bone marrow-derived human mesenchymal stem cells. *Stem Cells*, 24; 2006: 315–321.
16. **Marchini, G., Pedrotti, E., Pedrotti, M. et al.:** Long-term effectiveness of autologous cultured limbal stem cell grafts in patients with limbal stem cell deficiency due to chemical burns. *Clin Experiment Ophthalmol*, 40; 2012: 255–267.
17. **Pellegrini, G., Traverso, C.E., Franzi, A.T. et al.:** Long-term restoration of damaged corneal surfaces with autologous cultivated corneal epithelium. *Lancet*, 349; 1997: 990–993.
18. **Sotozono, C., Inatomi, T., Nakamura, T. et al.:** Visual improvement after cultivated oral mucosal epithelial transplantation. *Ophthalmology*, 120; 2013: 193–200.
19. **Sotozono, C., Inatomi, T., Nakamura, T. et al.:** Cultivated oral mucosal epithelial transplantation for persistent epithelial defect in severe ocular surface diseases with acute inflammatory activity. *Acta Ophthalmol*, 92; 2014: 447–453.
20. **Svobodova, E., Krulova, M., Zajicova, A. et al.:** The role of mouse mesenchymal stem cells in differentiation of naive T-cells into anti-inflammatory regulatory T-cell or proinflammatory helper T-cell 17 population. *Stem Cells Dev*, 21; 2012: 901–910.
21. **Uccelli, A., Moretta, L., Pistoia, V.:** Mesenchymal stem cells in health and disease. *Nat Rev Immunol*, 8; 2008: 726–736.
22. **Watt, F.M., Hogan, B.L.:** Out of Eden: stem cells and their niches. *Science*, 287; 2000: 1427–1430.
23. **Zajicova, A., Pokorna, K., Lencova, A. et al.:** Treatment of ocular surface injuries by limbal and mesenchymal stem cells growing on nanofiber scaffolds. *Cell Transplant*, 19; 2010: 1281–1290.
24. **Zhao, Y., Ma, L.:** Systematic review and meta-analysis on transplantation of ex vivo cultivated limbal epithelial stem cell on amniotic membrane in limbal stem cell deficiency. *Cornea*, 34; 2015: 592–600.