

The Success Rate of Persistent Primary Macular Hole Reoperations

Rambousek Jan, Veith Miroslav, Penčák Martin,
Straňák Zbyněk, Ernest Adam, Studený Pavel

Department of Ophthalmology, 3rd Faculty of Medicine, Charles University
and University Hospital Kralovske Vinohrady, Czech Republic



MUDr. Jan Rambousek

Submitted to the editorial board: April 30, 2025

Accepted for publication: September 22, 2025

Available on-line: November 4, 2025

The authors of the study declare that no conflict of interests exists in the compilation and subsequent publication of this professional communication, and that it is not supported by any pharmaceuticals company. The study has not been submitted to any other journal or printed elsewhere.

Correspondence address:

Oftalmologická klinika 3. LF UK a Fakultní
nemocnice Královské Vinohrady
Šrobárova 1150/50
100 34 Praha 10
Czech Republic
E-mail: jan.rambousek@fnkv.cz

SUMMARY

Aims: The aim of the study was to describe a cohort of patients reoperated on for persistent primary macular hole, and to evaluate the anatomical and functional results of the reoperated patients.

Material and Methods: 459 eyes of 390 patients were operated on for primary macular hole at Department of Ophthalmology, 3rd Faculty of Medicine, Charles University, Kralovske Vinohrady University Hospital between January 1, 2013, and December 31, 2023. We included 33 eyes of 33 patients in our retrospective case series, in which macular hole persisted after the primary surgery. Preoperative, perioperative and postoperative data of these patients were recorded, as well as initial and resulting best corrected visual acuity (BCVA), surgical technique, whether the first or second reoperation was successful. The minimum follow-up time was 90 days after the revision surgery. The statistical analysis included descriptive statistics to characterize the demographic and clinical parameters. Qualitative and quantitative variables were analyzed using means, medians and standard deviations.

Results: Primary surgery for macular holes was successful in 426 eyes of 357 patients (92.8%). The surgery was unsuccessful in the remaining 33 eyes of 33 patients (7.2%), with persistent macular hole. These patients underwent reoperation, which led to closure of the hole in 27 of 33 eyes (reoperation success rate 81.8% and total success rate of primary surgery and reoperation altogether 98.7%). Reoperation was unsuccessful in 6 eyes (18.2% of reoperated eyes and 1.3% of all operated macular holes). In 4 eyes a second reoperation was performed; in 3 eyes the reoperation was successful and led to an improvement of BCVA. The average BCVA of the successfully reoperated eyes was 65.2 ± 11.9 letters (ETDRS \pm SD). In the eyes of patients after a successful second reoperation, BCVA was 56.7 ± 8.4 letters, while in the eyes of patients who did not undergo further surgery ($n = 3$), average BCVA was only 39.0 ± 11.0 letters.

Conclusion: Reoperation of macular holes has a very good success rate and usually leads to an improvement of visual acuity. Improvement of visual acuity can also be achieved in patients who only achieved success after a second reoperation.

Key words: persistent and recurrent macular hole, revision surgery, ILM peeling, pars plana vitrectomy

Čes. a slov. Oftal., 81, 2025, No. x, p.

INTRODUCTION

Macular hole (MH) is a disorder of the central retina, most often affecting patients in the 6th and 7th decade of life, more frequently women [1]. It is usually manifested in deterioration of vision, metamorphopsias or the appearance of central scotoma. Following a comprehensive ophthalmological examination and evaluation of the biomicroscopic finding, as well as the finding on optical coherence tomography (OCT), in the case of some findings (e.g. stage I hole according to Gass, or newly appearing hole with a size of less than 250 μ m) initially observation only may be recommended [2,3].

Alternative semi-invasive methods of treatment such as the use of ocriplasmin or pneumatic vitreolysis are

now used rather only in rare cases due to their low rate of effectiveness [4].

Sutureless transconjunctival pars plana vitrectomy (PPV) with peeling of the internal limiting membrane (ILM) and intraocular tamponade is the therapeutic method of choice for findings in stage 2 to 4 according to Gass or in small, medium and large holes according to the IVTS (International Vitreomacular Traction Study Group), with and without traction [3,5]. Surgery generally has a very high success rate, stated in the professional literature within the range of 85–98% [5].

However, there are cases where surgery does not succeed in closing macular hole, upon which it is necessary to proceed to revision surgery [6]. The numerous risk

factors that may increase the probability of failure of surgery (greater size of hole, long period of duration of macular hole, high myopia) are well described in the literature [7]. There are several procedures and therapeutic options for treating recurrent and persistent macular hole. An example may be replacement of tamponade, revision surgery with various approaches to the ILM (extension of ILM peeling, plug with loose flap of ILM), the use of retinal grafts, amniotic membranes, lens capsules, the use of an autologous platelet concentrate, induced retinal detachment, retinal incisions and others. Cohorts describing surgical approaches to revision surgery of macular holes are usually small, and the choice of surgical approach is therefore considerably individual, depending on the surgeon's own experience and preference.

The aim of this study was to determine the success rate of macular hole reoperation in eyes in which the primary operation failed to close the hole, and to evaluate the anatomical and functional results of patients who underwent revision surgery.

MATERIALS AND METHODS

We conducted a retrospective analysis of the health documentation of all patients operated on for a diagnosis of macular hole at the Department of Ophthalmology of the 3rd Faculty of Medicine of Charles University and Kralovske Vinohrady University Hospital in the period between January 1, 2013, and December 31, 2023. Primary macular holes were operated on by 4 vitreoretinal surgeons, reoperations were performed by 3 surgeons. In the primary operations, pars plana vitrectomy was the standard procedure, with application of one of the following techniques: simple peeling of the internal limiting membrane, temporal ILM flap or inverted ILM flap. In the case of revision surgery the surgical strategy was not uniform, and the choice of technique depended on the individual decision of the operating surgeon, based on the size and configuration of the macular hole, the accessibility of the ILM flap, the length of duration of the hole and other factors. During revision surgery a check of the periphery was always conducted, as well as a check of whether ILM peeling was sufficient, or whether extension of ILM peeling was performed. The standard is to consider peeling to be sufficient if it is performed within a scope of 1.5 to 2 PD (papillary diameter) [3]. In the view of some authors, extension of ILM peeling is associated with a higher success rate of closure of macular holes (especially of holes larger than 400 μm) [8].

In the case of failure of revision surgery there was the option of considering the benefits of a second reoperation, thus the third operation in total. The technique of the second reoperation again depended on the judgement of the surgeon, and was therefore not uniform. In the case of two patients it incorporated silicone oil tamponade (in one also massage of the edges of the hole with diamond dusted membrane scraper), and in two others plug with loose ILM flap and SF6.

Patients with unfavorable prognostic indicators (large

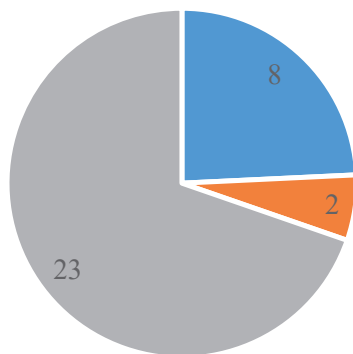
holes, pathological myopia, long duration of hole etc.) were also included in the retrospective series of cases. By contrast, patients with secondary macular holes for example upon a background of trauma, vascular diseases and retinal detachment, were excluded from the cohort. From the analyzed data, 459 eyes of 390 patients corresponded to the set parameters. Of these patients, 33 eyes of 33 patients underwent revision surgery due to persistent macular hole. We analyzed data of the patients from the period before the first operation up to the follow-up examinations after reoperation (first or second). The preoperative data incorporated information about age, sex, phakia or pseudophakia, best corrected visual acuity and the measurable and calculable parameters of MH. The perioperative data incorporated the surgical technique, whether peeling was performed, type of tamponade, complications of surgery and any applicable special technique used. The postoperative data incorporated BCVA and whether the macular hole was successfully closed. At the same time we recorded the length of time from the first operation to reoperation and the time of determination of BCVA after reoperation. BCVA originally stated on a Snellen chart was converted to ETDRS letters. In the patients who had silicone oil tamponade, BCVA was evaluated after silicone oil removal in order to ensure that the result was comparable. The range of the time from the first macular hole operation to reoperation was 13 to 226 days. The mean period was 77 days and the median was 55 days. Best corrected visual acuity was evaluated at a minimal interval of 90 days after macular hole surgery. The mean follow-up observation period was 260 days, the median was 191 days. Of the 33 patients (33 eyes) who underwent revision surgery, 9 patients were affected successively or simultaneously with bilateral macular hole (27%).

The choice of tamponade depended on the surgeon. In the primary operation sterile air was applied in the majority of cases. In reoperation SF6 was most often used (Graph 1). For diagnosis and determination of the measurable and calculable MH parameters we used the instruments Zeiss Cirrus HD-OCT 4000 (Carl Zeiss Meditec, Jena, Germany) and Heidelberg Spectralis OCT (Heidelberg Engineering, Heidelberg, Germany). The measurable parameters of the hole were evaluated on OCT. For MH a scan was identified that passes through the widest part of the hole, and subsequently the minimum linear diameter (MLD) of the hole, height of the hole (H) and base diameter (BD) and other parameters were measured in accordance with the established procedures according to the International Vitreomacular Traction Study Group [6].

An analysis of the measurable parameters of macular holes was conducted, and we evaluated whether the size of MLD before reoperation had an influence on the success rate of revision surgery in our cohort. For this purpose, the group of successfully reoperated patients was statistically compared with the group of unsuccessfully reoperated patients using a unpaired (independent) T-test for comparison of groups with the same dispersion.

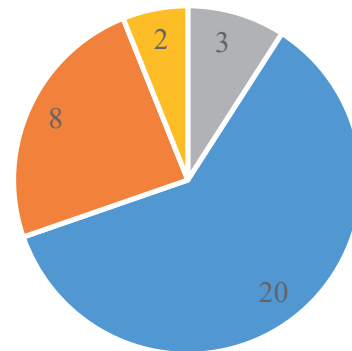
The further statistical analysis incorporated descriptive

Primary surgery tamponade



■ SF6 ■ C3F8 ■ Sterile air

Revision surgery tamponade



■ Sterile air ■ SF6 ■ C3F8 ■ SO

Graph 1. Primary surgery and revision surgery

statistics for characterizing demographic and clinical parameters. The qualitative and quantitative variables were analyzed with the aid of the mean, medium and standard deviation. A unpaired T-test was used for comparison of populations and analysis of the significance of key parameters of macular holes. Statistical significance was determined at the level of $p < 0.05$.

RESULTS

The cohort of evaluated patients is schematically presented in Figure 1. Out of those 459 operated eyes, macular hole was successfully closed in 426 eyes (success rate of primary operation 92.8%). In one patient with pathological myopia we recorded a recurrence of macular hole 5 years after the procedure. The patient was successfully reoperated on using the technique of bimanual insertion of an amniotic membrane into the subretinal space of the macular hole, with an improvement of BCVA and restoration of anatomical parameters in the fovea. Persistence of macular hole, and therefore failure of the primary operation, was recorded in 33 eyes of 33 patients (7.2%). In these eyes revision surgery was performed, which led to closure of the hole in 27 out of 33 eyes (success rate of reoperation 81.8% and success rate of primary operation and reoperation altogether 98.7%).

The clinical and demographic data of the patients who underwent revision surgery are presented in Table 1.

Bilateral failure of the primary operation from our cohort of 33 eyes of 33 patients was recorded in 3 patients (9%). The data from these operations are not part of our cohort, since they were operated on early at another center.

In all cases, after staining the performance of ILM peeling was evident. Extension of ILM peeling was performed in 7 cases, in 26 eyes peeling was sufficient ($n = 33$). In the next step, either replacement with air (or gas or oil) was performed, or one of the special surgical techniques was

additionally used. In our cohort the following techniques were used: 6x plug with loose ILM flap, i.e. insertion of ILM into macular hole (of which multiple ILM flaps were used 1x) 4x amniotic membrane, 1x repositioning of temporal ILM flap which loosened after the first operation, 2x massage of edges of hole with diamond dusted membrane scraper. The specific choice of surgical technique in reoperation depended on the preference of the surgeon (see Materials and Methods).

Eyes that underwent successful reoperation, both before primary operation and before reoperation had a smaller mean MLD than eyes in which reoperation was unsuccessful (baseline $498 \pm 168 \mu\text{m}$ vs. $564 \pm 120 \mu\text{m}$, and before reoperation $489 \pm 177 \mu\text{m}$ vs. $707 \pm 190 \mu\text{m}$ (Graph 2). However, no statistically significant difference was determined between the populations ($p = 0.078$). Mean postoperative BCVA of reoperated patients was 65.2 ± 11.9 (ETDRS letters \pm SD). In 6 patients revision surgery was unsuccessful (18.2% of reoperated patients and 1.3% of the total operated macular holes). Of these one patient was lost from the observation. In one patient the anatomical finding was highly advanced (wide open hole with flat edges), and the patient did not wish to undergo further surgery, hence reoperation was not performed.

A second reoperation was performed on 4 patients, and in 3 out of 4 eyes revision surgery was successful, leading to an improvement of BCVA. One patient had persistent macular hole even despite reoperation with silicone oil, which continued even after the discharge of SO, after which a further procedure was not recommended. In 3 patients the second reoperation was successful, and their resulting mean BCVA was 56.7 ± 8.4 (ETDRS letters \pm SD). In the patients who did not undergo a further procedure following unsuccessful revision surgery ($n = 3$), mean BCVA was only 39.0 ± 11.0 (ETDRS letters \pm SD), as presented in Table 2.

The frequency of severe complications was very low in

our cohort. Not one single case of endophthalmitis or retinal detachment was documented in the operated eyes within the observed period. The most frequent complication was the development of cataract. Cataract surgery was performed on 65% of patients within one year.

DISCUSSION

The current advanced and very sparing surgical technique for macular hole enables us to attain excellent results and successful closure of macular hole in 85–98% of

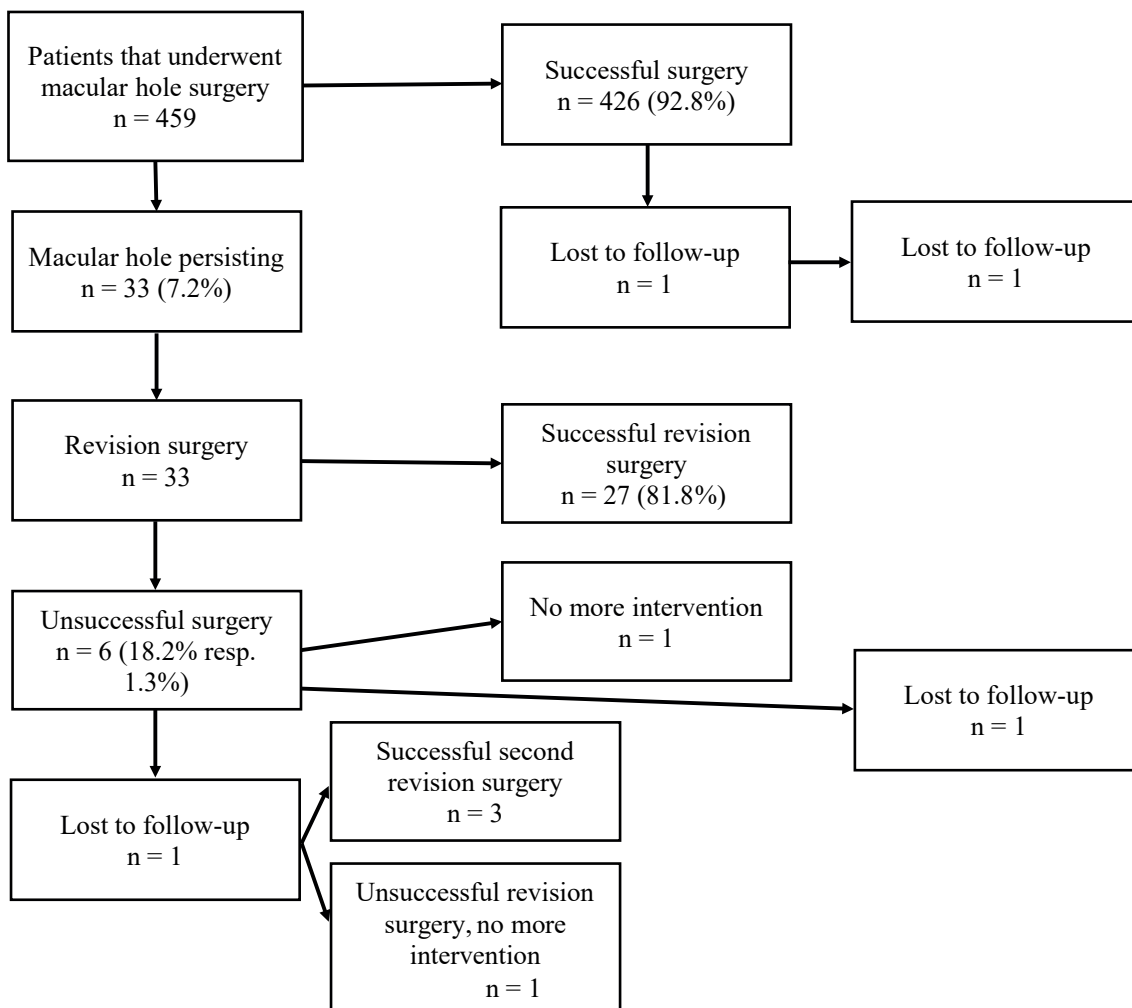
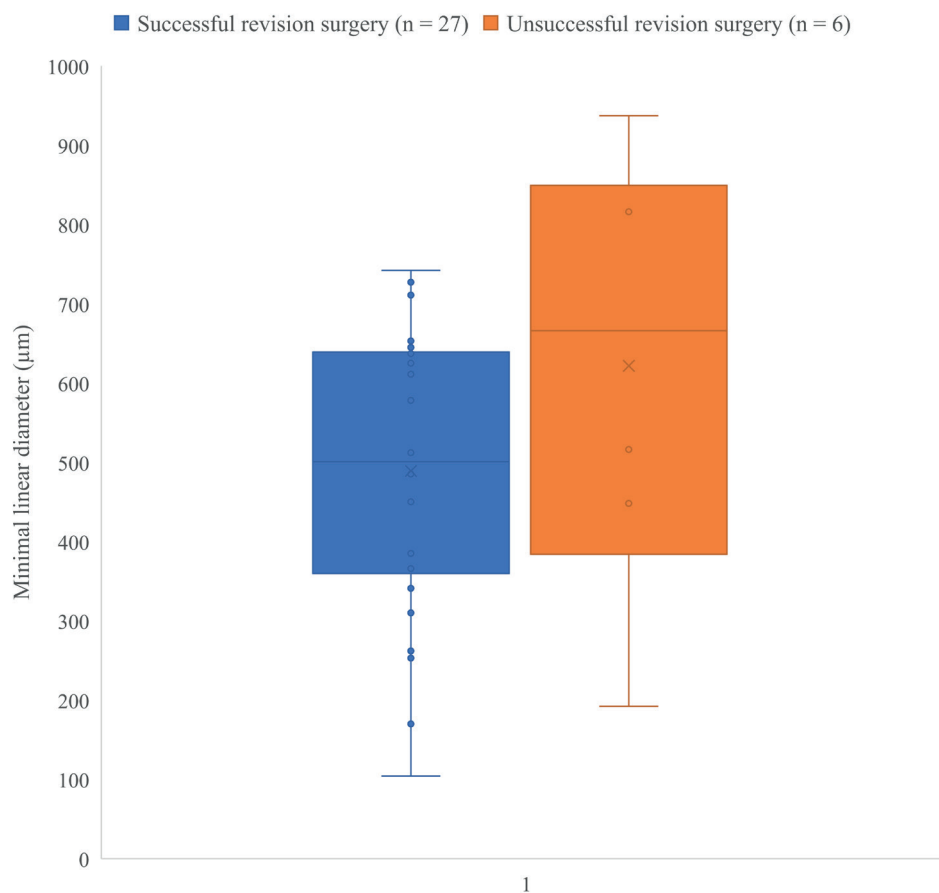


Figure 1. Diagram of the analyzed cohort

Table 1. Selection of clinical and demographic data of the patients that underwent revision surgery

		Underwent revision surgery n = 33	Successful revision surgery n = 27	Unsuccessful revision surgery n = 6
Age	Years in average \pm SD	73 \pm 6	72 \pm 5	74 \pm 8
Sex	male, n	3	3	0
	female, n	30	24	6
Phakic/pseudophakic	n	9	8	1
Bilateral macular hole	n	9	8	1
Primary surgery failure in the other eye	n	3	2	1
MLD before primary surgery	μ m, average \pm SD	509 \pm 166	498 \pm 168	564 \pm 120
MLD before revision surgery	μ m, average \pm SD	514 \pm 201	489 \pm 177	707 \pm 190

MLD – minimal linear diameter [4,5]



Graph 2. Minimal linear diameter of the hole before revision surgery

Table 2. Comparison of the final best-corrected visual acuity (BCVA) among patients

	Successful revision surgery	Successful second revision surgery	Second revision surgery not performed
Final BCVA (average number of letters ETDRS ± SD)	65,2 ± 11,9	56,7 ± 8,4	39,0 ± 11,0

cases, depending on whether risk factors appear, which generally reduce the success rate of surgery [6,7,9]. In our cohort, which also incorporated unfavorable and risk findings (large macular holes, pathological myopias, long duration of macular hole), the success rate was 92.8%. Failure of macular hole surgery was therefore 7.2%, which is comparable with similar previously published cohorts, which state a 4–47% failure rate of operations for MH [10,11].

An analysis of the demographic data determined that the mean age in the individual groups (reoperated patients, successfully reoperated and unsuccessfully reoperated) did not differ significantly, and this mean age of 73 years corresponds to the most frequent time when MH appears in patients. The representation of sex in our cohort was unequal, in a ratio of men to women of 1:10 (3 men and 30 women). The reported male-to-female sex ratio is usually stated at between 1:2 and 1:7, therefore our cohort deviates slightly from the norm in terms of the predominance of women, though it is not in conflict with the usual distribution [1,10]. From our observations

we may note the very low incidence of recurrence of macular hole (only one in the entire cohort), and also the high patient compliance with treatment, since only one patient was lost from the observation. From the cohort of revision surgery, 27 reoperations were successful (27 out of 33), thus 81.8%, which is a comparable result with a Canadian study of analogous parameters [12].

This Canadian study described 22 eyes in which closure of MH was not achieved after primary surgery. Of these, 20 eyes underwent revision surgery. Successful closure of the hole was achieved in 17 out of 20 patients, i.e. in 85%. In 3 patients closure of the hole was unsuccessful. In 70% of cases the surgical technique was extension of ILM peeling, in 12% inverted ILM flap and in 6% loose ILM flap. In the unsuccessfully reoperated patients (n = 3), in one case extension of ILM peeling was performed, in one case additional ILM peeling was not performed, only tamponade, and in one case loose ILM flap. The most frequently used tamponade was C3F8 (in 88%). It was recommended that patients were positioned face-down for a period of one week. Consistently with other authors, they state

a shorter duration of macular hole in the group in which revision surgery was successful in comparison with the unsuccessfully reoperated patients. In the successfully reoperated patients there was also a smaller mean MLD.

The surgical approach to reoperation differs markedly among the individual operating surgeons. A very often mentioned method is extension of ILM peeling, since this reduces horizontal traction on the macular hole and leads to more frequent closure of the hole [8]. A study from Shanghai from 2014 retrospectively analyzed a group of 134 eyes of patients who had been operated on for primary macular hole. Macular hole persisted in 14 eyes after surgery, 13 of which underwent revision surgery with extension of ILM peeling up to the vascular arcades. Macular hole was successfully closed by the operation in 8 out of the 13 patients, i.e. in 61.5%. [13].

In revision surgery the option is for extension of peeling beyond 2 PD or up to the vascular arcades, as described above. However, if a temporal flap was used in the primary operation, in the case of dislocation of the flap it is possible to perform simple repositioning of the flap over the edges of the hole, which also has a good effect as in our cohort.

Of other special surgical techniques, plug with a loose ILM flap was repeatedly used, which is a proven technique that produces positive results [14]. In a study from 2020, Fung stated successful closure of persistent macular hole with the aid of a loose ILM flap in 7 out of 8 patients, i.e. in 87.5%. In addition, this was a cohort of unfavorable findings with a median MLD of holes of 821 μm .

In the case that it is not possible to create a flap that is sufficiently large, it is also possible to use multiple small ILM flaps. Any applicable choice of an alternative technique, for example amniotic membrane or lens capsule, depends on the condition of the lens of the eye in question. In a phakic eye it is possible to use the anterior and the posterior capsule in concurrent cataract surgery. In an pseudophakic eye after primary posterior capsulorhexis it is no longer possible to use a capsule. Polish authors in a study from 2021 achieved successful closure of macular hole upon use of a capsule in 5 out of 5 operated eyes [15].

Amniotic membrane is also a frequently stated technique, which is not dependent on the condition of the patient's lens. An indisputable advantage of this technique is its substantially smaller limitation by the quantity of material in comparison with the use of a lens capsule [16].

The last special technique used in the cohort was massage of the edges of the macular hole with a diamond dusted membrane scraper. This technique of massaging the edges of the hole with a silicone brush was used in combination with extension of ILM peeling and C3F8 tamponade in a published cohort of Czech authors in 2014 [17].

The author and team processed a retrospective cohort of 6 eyes with unclosed MH following PPV at an interval of 5 to 11 months after the first unsuccessful operation. ILM peeling was performed in all eyes in the primary operation. The revision surgery incorporated extension of ILM peeling, manual loosening of the edges of the rigid MH and discharge of the content of IMH with temporary air tamponade, and face-down positioning of the

patient for a period of one week. Postoperative closure was achieved in all 6 operated eyes, and the success rate was therefore 100%. Visual acuity improved in all patients, final BCVA was within the range of 20/32 to 20/160, mean 20/60 (median 20/80). The authors attribute the high success rate to the careful mechanical loosening of the edges of the hole and internal discharge rather than to simple extension of ILM peeling in combination with sufficient tamponade and positioning of the patient.

According to the available literature, to date there is no absolute consensus regarding the matter of the choice of tamponade in revision surgery for macular hole [12,18]. Salvatore Cillino of Palermo conducted a randomized prospective study in 2016, in which he compared the use of 20% C2F6 against a compound of silicone oil and perfluorohexyloctane (Desiron-68) in patients with persistent macular hole (MLD of the holes was $680.3 \pm 120.8 \mu\text{m}$ and $740.5 \pm 105.3 \mu\text{m}$). Successful closure of macular hole was achieved in 30% in the group with C2F6 and in 90% in the group with silicone oil and perfluorohexyloctane [19]. However, prospective randomized studies are rather rare in this field, and we have most of our data from retrospective studies. In primary surgery for macular hole, in cases where the size of the hole is greater than 400 μm , SF6 tamponade in combination with the reading position for 5 days is sufficient. Longer-acting tamponades such as C3F8 do not have an added effect [20]. By contrast, in revision surgery for persistent macular hole, in the studies we analyzed the authors incline rather towards longer-acting tamponades (most frequently C3F8) [3,12,13,21,22]. Silicone oil is also sometimes used for persistent macular holes [12]. It is also suitable in the case of difficult or impossible positioning. In our cohort it is evident that even with tamponades acting for a shorter time (e.g. SF6) it is possible to achieve closure of persistent macular holes.

In our cohort of reoperations we observed apparently greater MLD in the population of unsuccessful reoperations ($n = 6$) in comparison with successful reoperations ($n = 27$). However, the analysis did not detect a statistically significant difference between the groups. We believe that the reason for this is that the population of unsuccessfully reoperated macular holes was too small, since in the graphic illustration it is possible to observe a trend of data distribution in the sense of larger holes in unsuccessfully reoperated eyes. In the study we chose as referential, the authors consistently with us observed larger MLD in unsuccessfully operated MH. For a genuinely credible assessment of reoperations of macular holes, it is necessary to continue to gather data and subsequently compare them in a larger population of unsuccessful reoperations [12].

Best corrected visual acuity in the patients following successful revision surgery was 65.2 ± 11.9 (mean ETDRS letters \pm SD), and it is worth mentioning that 30% of reoperated patients attained visual acuity better than 6/12. In a similar study by Canadian authors, resulting BCVA is stated at 55 ± 19 letters and 29% of patients with visual acuity better than 6/12 on a Snellen chart [12].

By comparison, among patients in whom the macular hole was closed after a second revision surgery, BCVA was

56.7 ±8.4. In patients who underwent no further procedure, BCVA was 39.0 ±11.0 letters. Even despite the visibly lower values of visual acuity in the patients after the second reoperation, we can conclude that revision surgery of macular hole is beneficial, because in this group the patients often achieved serviceable vision, even if worse than in the group of already previously successfully reoperated patients. In the group in which closure of macular hole was unsuccessful, visual acuity did not improve but also did not deteriorate.

The authors from Canada described the results in 45 patients in whom closure of macular hole was not achieved following pars plana vitrectomy. A total of 30 patients underwent revision surgery, in which extension of ILM peeling and gas tamponade was performed. Closure was successful in 14 out of 30 patients, i.e. 46.7%. In the successfully reoperated eyes there was a statistically significant improvement of BCVA one year after surgery. In the eyes in which macular hole was not closed after the

second operation there was neither an improvement nor a deterioration of BCVA, analogously with our cohort [23].

CONCLUSION

The success rate of persistent macular hole reoperation was 81.8%. The total success rate of primary surgery and revision surgery was 98.7%. The success rate of the second reoperation was 75%. Of the group of successfully reoperated patients, 30% attained visual acuity of equal or better than 6/12. In all the successfully reoperated patients, BCVA improved even despite the long duration of macular hole. In conclusion it is therefore possible to state that reoperation of macular hole has a very high success rate, a low risk of complications and as a rule leads to improvement of BCVA. Improvement of BCVA can be achieved even in patients in whom macular hole was closed only after the second reoperation.

REFERENCES

- McCannel CA, Ensminger JL, Diehl NN, Hodge DN. Population-based incidence of macular holes. *Ophthalmology*. 2009;116(7):1366-1369. doi:10.1016/j.ophtha.2009.01.052
- Gass JD. Reappraisal of biomicroscopic classification of stages of development of a macular hole. *Am J Ophthalmol*. 1995;119(6):752-759. doi:10.1016/s0002-9394(14)72781-3
- The Royal College of Ophthalmologists. Draft clinical guideline on idiopathic full-thickness macular holes [David Steel, chair] [Internet]. London (UK): The Royal College of Ophthalmologists; 2024 Oct [cited 2025 Aug 2]. Available from: <https://www.rcophth.ac.uk/wp-content/uploads/2024/10/DRAFT-clinical-guideline-on-idiopathic-full-thickness-macular-holes.pdf>
- Yu BE, Sheidow T, Sambhi RS, Hooper P, Malvankar-Mehta MS. The effectiveness of ocriplasmin versus surgery for the treatment of macular holes: A systematic review and meta-analysis. *Eur J Ophthalmol*. 2021 Jul;31(4):2003-2012. Epub 2020 Jul 30. doi: 10.1177/1120672120946925
- Kim SJ, Lim JI, Bailey ST, et al. American Academy of Ophthalmology Preferred Practice Pattern Retina/Vitreous Committee. Idiopathic Macular Hole Preferred Practice Pattern®. *Ophthalmology*. 2025 Apr;132(4):P234-P269. Epub 2025 Feb 7. doi: 10.1016/j.ophtha.2024.12.021.
- Duker JS, Kaiser PK, Binder S, et al. The International Vitreomacular Traction Study Group classification of vitreomacular adhesion, traction, and macular hole. *Ophthalmology*. 2013 Dec;120(12):2611-2619. Epub 2013 Sep 17. doi: 10.1016/j.ophtha.2013.07.042
- Ruiz-Moreno JM, Staicu C, Piñero DP, Montero J, Lugo F, Amat P. Optical coherence tomography predictive factors for macular hole surgery outcome. *Br J Ophthalmol*. 2008 May;92(5):640-644. doi: 10.1136/bjo.2007.136176
- Bae K, Kang SW, Kim JH, Kim SJ, Kim JM, Yoon JM. Extent of Internal Limiting Membrane Peeling and its Impact on Macular Hole Surgery Outcomes: A Randomized Trial. *Am J Ophthalmol*. 2016 Sep;169:179-188. Epub 2016 Jul 5. doi: 10.1016/j.ajo.2016.06.041
- Li Y, Jin S, Shi L, Qin H, Zhao J. Factors Associated with Anatomic Failure and Hole Reopening after Macular Hole Surgery. *J Ophthalmol*. 2021 Dec 7;2021:7861180. doi: 10.1155/2021/7861180
- Steel DH, Donachie PHJ, Aylward GW, et al. BEAVRS Macular hole outcome group. Factors affecting anatomical and visual outcome after macular hole surgery: findings from a large prospective UK cohort. *Eye (Lond)*. 2021 Jan;35(1):316-325. Epub 2020 Mar 30. doi: 10.1038/s41433-020-0844-x
- Zhao PP, Wang S, Liu N, Shu ZM, Zhao JS. A Review of Surgical Outcomes and Advances for Macular Holes. *J Ophthalmol*. 2018 Apr 18;2018:7389412. doi: 10.1155/2018/7389412
- Lachance A, You E, Garneau J, et al. Revision Surgery for Idiopathic Macular Hole after Failed Primary Vitrectomy. *J Ophthalmol*. 2021 Jan 7;2021:8832538. doi: 10.1155/2021/8832538
- Che X, He F, Lu L, Zhu D, Xu X, Song X, Fan X, Wang Z. Evaluation of secondary surgery to enlarge the peeling of the internal limiting membrane following the failed surgery of idiopathic macular holes. *Exp Ther Med*. 2014 Mar;7(3):742-746. Epub 2014 Jan 7. doi: 10.3892/etm.2014.1477
- Fung NSK, Mak AKH, Yiu R, Wong IYH, Lam WC. Treatment of large, chronic and persistent macular hole with internal limiting membrane transposition and tuck technique. *Int J Retina Vitreous*. 2020 Mar 9;6:3. doi: 10.1186/s40942-019-0206-7
- Cisiecki S, Bonińska K, Bednarski M. Autologous Lens Capsule Flap Transplantation for Persistent Macular Holes. *J Ophthalmol*. 2021 Feb 27;2021:8148792. doi: 10.1155/2021/8148792
- Bamberger MD, Felfeli T, Politis M, Mandelcorn ED, Galic IJ, Chen JC. Human Amniotic Membrane Plug for Chronic or Persistent Macular Holes. *Ophthalmol Retina*. 2022 May;6(5):431-433. Epub 2022 Jan 17. doi: 10.1016/j.oret.2022.01.006
- Hejsek L, Stepanov A, Dusova J, Jiraskova N. Reoperation of idiopathic macular hole. *Biomed Pap Med Fac Univ Palacky Olomouc Czech Repub*. 2014;158(4):596-599. doi:10.5507/bp.2013.088
- Shi Y, Feng L, Li Y, et al. Outcomes of revision surgery for idiopathic macular hole after failed primary vitrectomy. *Front Med (Lausanne)*. 2023 Jul 27;10:1169776. doi: 10.3389/fmed.2023.1169776
- Cillino S, Cillino G, Ferraro LL, Casuccio A. Treatment of persistently open macular holes with heavy silicone oil (Densiron 68) versus C2f6. A Prospective Randomized Study. *Retina*. 2016 Apr;36(4):688-694. doi: 10.1097/IAE.0000000000000781
- Veith, M. Chirurgické řešení idiopatické makulární díry s použitím různých typů tamponád a různého režimu pooperačního polohování [online]. Defended dissertation thesis. Hradec Králové: Univerzita Karlova, Lékařská fakulta v Hradci Králové, 9. 9. 2020 [cit. 2025-08-16]. Available from: <http://hdl.handle.net/20.500.11956/120791>
- Moisseiev E, Fabian ID, Moisseiev J, Barak A. Outcomes of repeated pars plana vitrectomy for persistent macular holes. *Retina*. 2013 Jun;33(6):1137-1143. doi: 10.1097/IAE.0b013e31828076c5
- Baumann C, El-Faouri M, Ivanova T, et al. Manchester revisional macular hole study: predictive value of optical coherence tomography parameters on outcomes of repeat vitrectomy, extension of internal limiting membrane peel, and gas tamponade for persistent macular holes. *Retina*. 2021 May;41(5):908-914. doi:10.1097/IAE.0000000000002959
- D'Souza MJJ, Chaudhary V, Devenyi R, Kertes PJ, Lam W-Ch. Re-operation after ILM peel in idiopathic full-thickness macular holes. *Br J Ophthalmol*. 2011;95(11):1564-1567. doi:10.1136/bjo.2010.195826