

# Failure of Primary Posterior Continuous Curvilinear Capsulorhexis? A Case Report

Novák Jan<sup>1</sup>, Otrošínová Marianna<sup>1</sup>, Kubíková Lucie<sup>1</sup>, Krásnik Vladimír<sup>2</sup>

<sup>1</sup>Pardubice Regional Hospitals, joint-stock company, Pardubice Hospital, Department of Ophthalmology, Czech Republic

<sup>2</sup>Department of Ophthalmology, Faculty of Medicine, Comenius University and Ružinov University Hospital, Bratislava, Slovakia

Submitted to the editorial board: December 12, 2024

Accepted for publication: March 17, 2025

Available on-line:

*The authors of the study declare that no conflict of interests exists in the compilation, theme and subsequent publication of this professional communication, and that it is not supported by any pharmaceuticals company. The study has not been submitted to any other journal or printed elsewhere, with the exception of congress abstracts and recommended procedures.*



**First author:**

Doc. MUDr. Jan Novák, CSc., FEBO

**Corresponding author:**

MUDr. Marianna Otrošínová, FEBO

Kyjevská 44

533 03 Pardubice

Czech Republic

E-mail: ivancova.marianna@gmail.com

## SUMMARY

The aim of the study is to present the possible development of proliferative secondary cataracts in the unique case of a patient having undergone premium cataract surgery with preventive primary posterior continuous curvilinear capsulorhexis (PCCC). Due to the negative effect on visual functions, it was decided to treat the patient with an Nd:YAG laser, which was successful with minimal energy but resulted in damage to the anterior hyaloid membrane (AHM).

### Case report

In 2020, a 65-year-old man underwent uncomplicated cataract surgery in both eyes at our clinic bilaterally with primary PCCC with implantation of a tension ring and an artificial intraocular lens into the capsule. In February 2023, on the recommendation of the area ophthalmologist, he was examined at our outpatient clinic due to a decrease of visual acuity in the right eye. Blurred vision predominated. A diagnosis of proliferative form of secondary cataract was confirmed and documented using a photo of the anterior segment in retroillumination and anterior segment OCT (Optovue, Avanti RTVue XR). The patient was indicated for Nd:YAG laser disruption by proliferation in the PCCC space in the right eye. The return of visual acuity to its original state confirmed the correct diagnosis. The literature review and discussion summarize the current issue of secondary cataracts and the use of primary PCCC.

**Conclusion:** Secondary cataract is the main long-term complication of modern cataract surgery. One of the possible solutions is the preventive implementation of a simple PCCC, which may be accompanied by isolated failure.

**Key words:** primary posterior continuous curvilinear capsulorhexis, PCCC, proliferations, Nd:YAG laser

*Čes. a slov. Oftal., 81, 2025, No. 4, p. 213–218*

## INTRODUCTION

Cataract surgery using the method of phacoemulsification is an irreversible trauma, which is always followed by individually conditioned reparation processes. A role is played in these processes both by residual cells in the lens capsule (A,B,D-cells) and migrated monocytes/macrophages. Fibroproliferative changes of the capsule after cataract surgery develop sooner or later throughout the entire scope of the capsule of the original lens crystalline in 100% of operated eyes. A deterioration of visual acuity (VA) occurs only when the central part of the posterior capsule is affected, especially in the axis of vision. In regular ophthalmological practice, therefore only posterior capsular opacification (PCO) in the region of the axis of vision is considered to constitute a secondary cataract [1,2]. PCO is usually evaluated throughout the entire scope of the optics of the intraocular lens (IOL), or possibly

projection of the pupil. The occurrence of PCO is generally considered the main indicator of the quality of the performed operation, or the perspective of the success rate of various surgical techniques or the quality of construction and material of the intraocular lenses. Despite improvements in the technique of cataract surgery, PCO therefore still remains the most common long-term postoperative complication in patients who have undergone cataract surgery. When the central part of the posterior capsule is affected this leads to a significant deterioration of visual functions and patient dissatisfaction. The basic treatment is disruption of the altered posterior capsule behind the IOL using an Nd:YAG laser. The incidence of this treatment is more than 50% ten years after standard cataract surgery. The standard operation covers removal of the lens core and cortical matter after the performance of anterior curvilinear capsulorhexis and implantation of an IOL into the capsule.

There is a whole range of premium surgical methods and specially constructed intraocular lenses and other implants aimed at reducing the incidence of PCO. The surgical techniques use methods leading to the removal of the lens cells, quality materials and special barrier construction of the IOL. Nevertheless, in the available literature the incidence of PCO is stated at between 20 and 77% in adults and in as many as 100% of child patients with an intact posterior capsule [3,4].

In the occurrence and development of secondary cataract, a key role is played by the central part of the posterior capsule of the lens, which serves as a platform along which germinative equatorial lens epithelial cells (E-LECs) can migrate between the posterior capsule and the posterior surface of the artificial IOL. Forgotten "D-cells" (dream cells) and migrated cells from the family of monocytes/macrophages may also proliferate on the posterior capsule. The matrix of the capsule itself alters its structure in contact with certain materials of artificial lenses. Mechanical changes of the capsule in the axis of vision also influence visual functions. Folds in the center of the posterior capsule formed by mechanical pressure of the haptics on the equator indicate optical errors of the system, and furthermore reduce the effect of the barrier function of the sharp edge of the IOL and enable migration of cells to the axis of vision. The usual outcome of this is proliferative, fibrotic or mixed form of secondary cataract. Extreme attempts to inhibit growth or eradicate the presence of LECs have proven to be surgically complicated, with problematic effectiveness and are therefore generally unacceptable. A typical example is the introduction of the Perfect Capsule™ device (Milvella Pty. Ltd., Epping, NSW, Australia), developed by Maloof and his team. Perfect Capsule™ enables precise and safe administration of pharmacological substances during cataract surgery. This system creates a sealed environment inside the lens capsule, which eliminates the risk of contact of the applied substance with the surrounding tissues. At the same time, it provides the surgeon with the option of thorough flushing of the intracapsular space after applying the selected chemical substance [5]. The most effective way of preventing secondary cataract therefore appears to be removal of the central part of the posterior capsule [6,7].

Primary PCCC, a maneuver known since the 1980s, is still performed only rarely during the course of cataract surgery. In 1996 Galand et al. recommended the routine use of PCCC for both children and adults [8,9]. However, these techniques are not routinely used on adults due to the risk of potential severe complications such as breach of the AHM, prolapse of the vitreous, postoperative inflammatory reaction or macular edema [10]. A considerable role is also played by potential prolonging of the operation and increased cost. However, this does not apply in the case of modern surgeons [11].

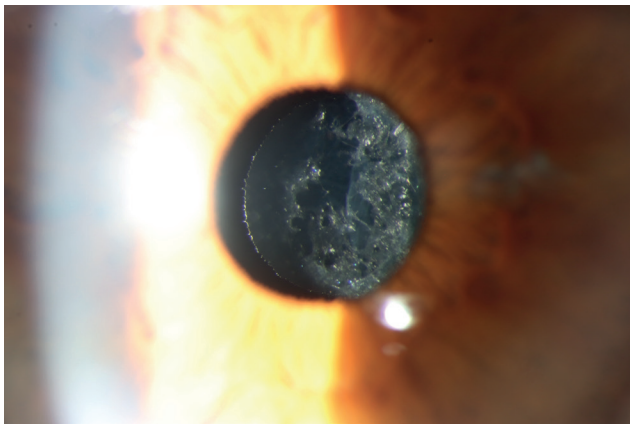
## CASE REPORT

In November 2020 a 65-year-old patient was operated on at our center for bilateral cataract. Before surgery, the

best corrected visual acuity (BCVA) was 0.63 in the right eye and 0.80 in the left eye. The patient underwent problem-free cataract surgery on both eyes with implantation of an aspherical artificial intraocular lens AMO-ZCB00 Tecnis (Johnson and Johnson Vision, California, USA). This lens meets the strictest criteria for design and quality. It is one of the longest-used intraocular lenses without any references to faults in the literature regarding the used hydrophobic material, and it is furnished with a sharp edge to prevent the migration of LECs within a scope of 360°. Surgery was performed first on the right eye, and one week later on the left eye. A procedure of cataract surgery with primary preventive PCCC was chosen for the patient, a neurosurgeon who required high quality of postoperative contrast sensitivity, in an attempt to avoid posterior capsular opacification and a deterioration of visual functions after surgery.

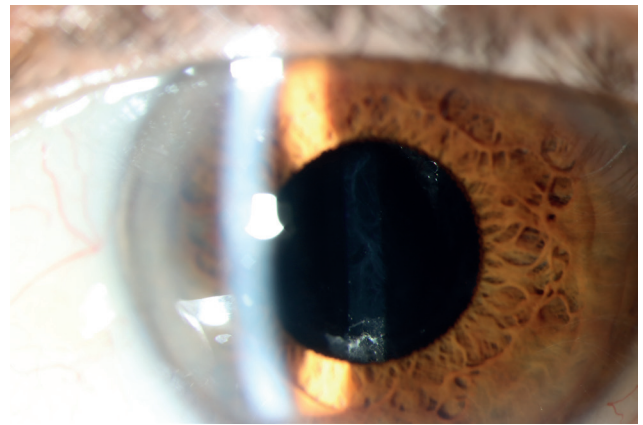
Written informed consent was obtained from the patient. After standard phacoemulsification, the lens capsule was thoroughly cleaned, removing residues of cortical matter. The anterior capsule, equator and posterior capsule were then cleaned of LECs by irrigation/aspiration through a combination of a one and five-way aspiration cannula. The operation continued with the performance of PCCC. The posterior capsule was concavely pushed under an air bubble in the direction of the vitreous and stained with the aid of a drop of brilliant blue. This was followed by flushing and applanation of the posterior capsule with cohesive viscoelastic material (VEM). The Berger's space was filled from the needle incision in the center of the posterior capsule with cohesive VEM. Subsequently the posterior capsule was concavely pushed towards the vitreous, and a 4 mm PCCC was ringed on the cake of the VEM in the Berger's space using 25G coaxial forceps. The size and position of posterior capsulorhexis was chosen so as to ensure that its edge did not extend beyond the edge of the optical part of the IOL (slightly smaller than 5mm anterior capsulorhexis). The torn central part of the posterior capsule was removed, and after the filling of cohesive VEM into the periphery of the capsule a 12 mm capsular tension ring (Ophtec BV, Netherlands) was implanted in order to prevent striae of the remainder of the posterior capsule. Finally a pre-folded artificial IOL was implanted using a screw injector. The VEM was drained from the anterior chamber, the capsule and Berger's space with the aid of an irrigation and aspiration 5-way cannula without damage to the PHM, the wounds were hydrated and antibiotics were applied into the anterior chamber.

Postoperatively BCVA was 1.00 in the right eye and 1.00 in the left eye. Two and a half years after surgery there was a deterioration of VA in the right eye to 0.60, resulting in subjective patient dissatisfaction. Upon examination using a slit lamp in artificial mydriasis, the entire visible area of the original PCCC in the right eye was occluded with a mesh of proliferations on the AHM, which also hindered examination of the ocular fundus, while in the left eye the finding was of isolated filaments behind the IOL



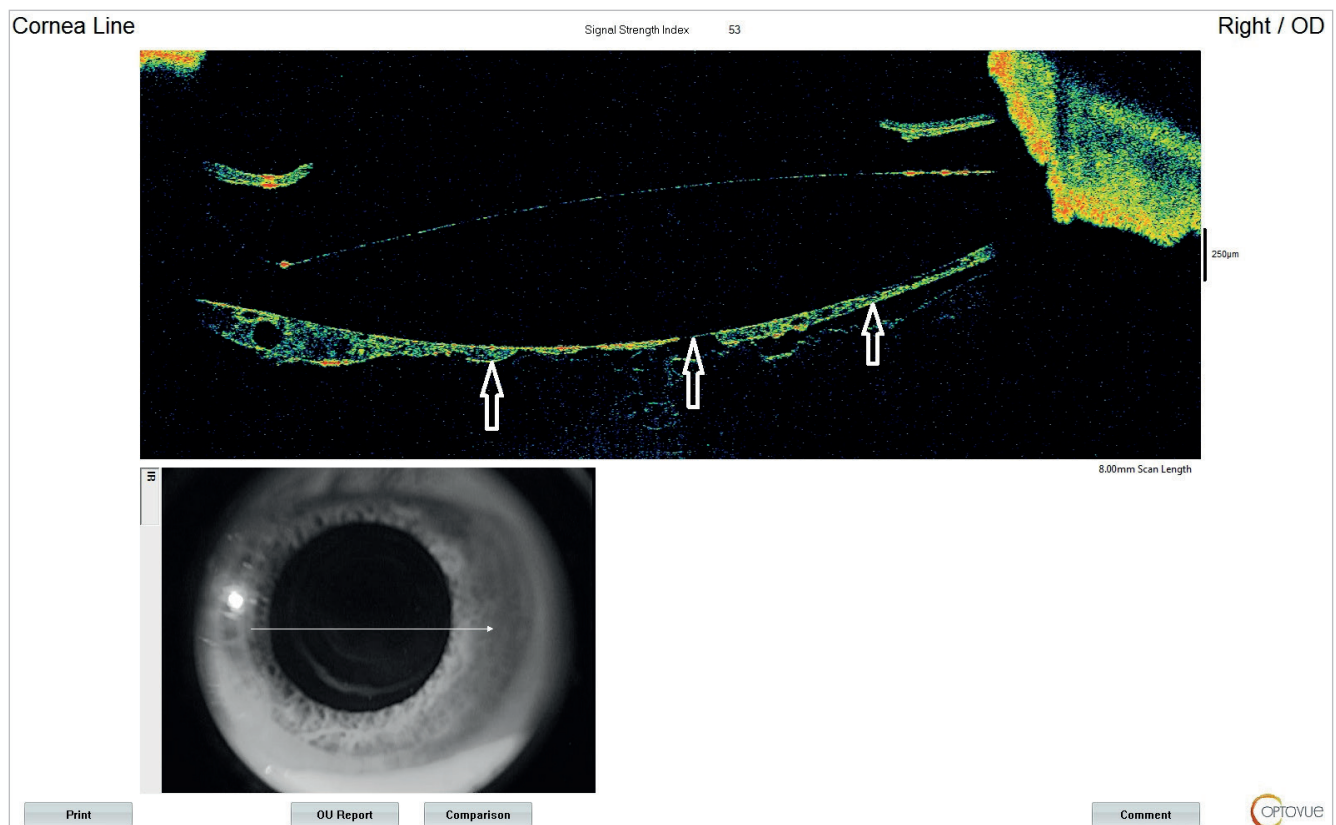
**Figure 1.** Anterior segment of the right eye. The entire visible area of the original PCCC enclosed by a mesh of proliferations lying on the AHM

*PCCC – posterior circular curvilinear capsulorrhexis, AHM – anterior hyaloid membrane*



**Figure 2.** Anterior segment of the left eye. Isolated filaments behind IOL in the PCCC area

*PCCC – posterior circular curvilinear capsulorrhexis, IOL – intraocular lens*



**Figure 3.** Anterior segment OCT of the right eye. Area of the original PCCC enclosed by proliferations. Intact AHM adheres practically close to the back surface of the IOL in the central area (white arrows)

*OCT – optical coherence tomography, PCCC – posterior circular curvilinear capsulorrhexis, AHM – anterior hyaloid membrane*

in the region of the PCCC (Figure 1 and 2). The finding in the right eye was also documented with the aid of anterior segment optical coherence tomography (AS-OCT) (Figure 3). The AHM was probably buckled over the PCCC already after surgery (we encounter this phenomenon in anterior segment OCT) and in the center it was in contact with the posterior surface of the IOL. Together with the remainder of the posterior capsule, from the beginning

it thus formed a continuous platform for the migration of proliferating cells from the periphery to the center.

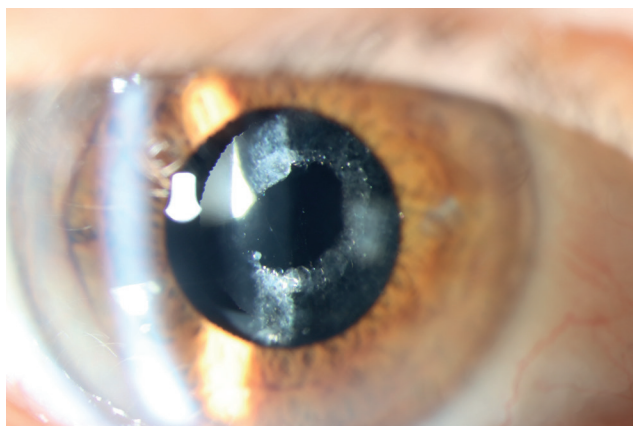
Before we decided on how to proceed further, the results of the examination of the ocular fundus were assessed. Examination of the macular region by optical coherence tomography excluded the presence of any macular pathology. The occlusive mesh of proliferations on the AHM in the right eye was successfully breached with the aid of



an Nd:YAG laser using only 3 impulses with a total energy of 2.0 J. Tearing of the AHM was visible here. After Nd:YAG laser capsulotomy, BCVA improved to 0.80 (Figure 4 and 5).

## DISCUSSION

Even after successful cataract surgery preserving an intact clear posterior capsule, adult patients worldwide nevertheless suffer secondary deterioration of visual func-

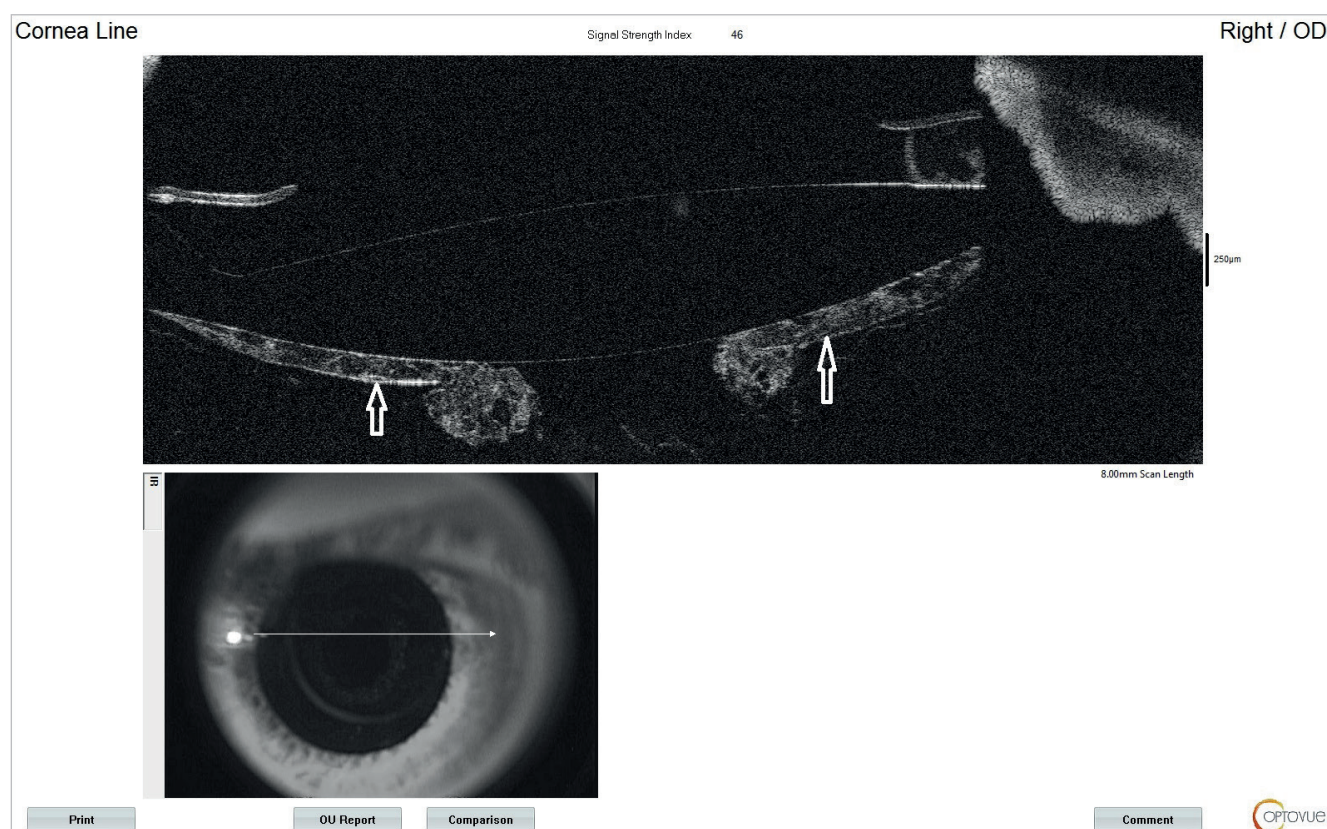


**Figure 4.** Anterior segment of the right eye after Nd:YAG laser treatment. The mesh of proliferations is disrupted. Damaged AHM (white arrows)

*PHM – anterior hyaloid membrane*

ions as a consequence of repeat blurring of the visual axis caused by posterior capsule opacification. If opacification is so serious that it again inhibits the performance of everyday activities, ophthalmologists perform seemingly simple posterior capsulotomy with the aid of an Nd:YAG laser. In connection with the Nd:YAG laser procedure we consider a successful result to be an opening in the center of the altered posterior capsule with perception of occasional opacifications (fragments of capsule), with VA of 20/20 on Snellen charts, and we accept breach of the AHM. Although the incidence is low, we must take into consideration the risk of occurrence of cystoid macular edema, elevation of intraocular pressure, progression of diabetic retinopathy and retinal detachment following laser capsulotomy. We have underestimated the role of the AHM in maintaining ocular homeostasis. Breach of the hyaloid membrane, either due to complications or intentionally, has an influence on the morbidity of the anterior and posterior segment of the eye [12]. Nevertheless, with awareness of the inevitable occurrence of PCO, Nd:YAG capsulotomy is generally performed preventively at the first follow-up examination following cataract surgery. The reason usually given is the simplicity of disrupting the hitherto unaltered posterior capsule. The occurrence of fibroproliferations does not influence this, but they are mainly localized only in the periphery over the long term.

In the 1990s few people saw the benefit and safety of



**Figure 5.** Anterior segment OCT of the right eye after Nd:YAG laser treatment. The mesh of proliferations in the area of the original PCCC is disrupted. A damaged AHM is visible

*PCCC – posterior circular curvilinear capsulorhexis, AHM – anterior hyaloid membrane*

the PCCC technique, when it was generally believed that the posterior capsule constituted the most important barrier between the anterior and posterior part of the eye. It was Jan Worst and subsequently Tassignon and Menapace who demonstrated that it was in fact the AHM that ensures this barrier function [13].

PCCC sparing the hyaloid membrane plays a significant role in avoiding complications with posterior capsule opacifications that cannot be removed by polishing. In the case of posterior polar cataract, removal of the fragile posterior capsule by means of PCCC averts uncontrolled cracking during polishing, and at the same time avoids residual opacification and the need for early laser capsulotomy. Besides patients who are unable to undergo laser capsulotomy due to physical or psychological conditions, other candidates for cataract surgery with primary PCCC include patients with high myopia, uveitis and patients with pseudoexfoliations, who may especially enjoy lifelong benefit from a reduction of capsular fibrosis, phimosis and unbreached AHM [14].

Galand, as a strong advocate of primary PCCC, believed that simple removal of the posterior capsule was sufficient in order to preserve a clear visual axis. Nevertheless, it has been demonstrated that LECs may continue to grow across the anterior surface of the AHM or along the posterior surface of the IOL [15,16].

Upon use of PCCC as a primary procedure in combination with posterior optic capture (POC) of the IOL into the Berger's space, LECs cannot migrate into the retrolental space using the capsule, vitreous surface or posterior optic part of the lens as in PCCC alone. However, this may continue to enable proliferation of Elschnig pearls across the axis of vision along the anterior surface of the IOL, as was the case with our patient. But there is a difference here: the peripheral posterior capsule, now located between the anterior capsule and the optics of the IOL, coalesces with the anterior capsule and prevents the migration of E-LECs.

Despite the long history of PCCC, there were no prospective randomized trials on the effectiveness and results until the study conducted by Menapace, in which he compared POC with standard cataract surgery with the implantation of an IOL into the capsule, PCCC alone and POC over the course of time on a large series of patients randomized to one eye [17]. Menapace determined that patient preference for the eye without a posterior capsule in comparison with the eye with an intact "clear" capsule was objectively explained by the increase of light dispersion measured with the aid of the straylight meter C-Quant (Oculus Optikergate GmbH) in the eye with the intact capsule [18]. Over the course of several years of observation, no obstruction of the visual axis was recorded, which underlines the value of this technique. This study, along with studies conducted by other surgeons, demonstrated the safety of PCCC and confirmed that the use of these techniques does not lead to changes of intraocular pressure, greater inflammatory reaction in the anterior chamber, increase of macular thickness or retinal detachment (in fact on the contrary, a slight decrease) [17,19–21] in comparison with eyes in which the posterior capsule has been left intact [18,20,21].

However, it is essential to ensure that damage to the AHM does not occur upon PCCC [23].

POC is important especially in selected groups of patients: In children with cataract, in those who are unable to undergo laser capsulotomy and in those who have no access to a laser – especially in developing countries.

It is therefore reasonable to believe that sooner or later hyaloid membrane-sparing PCCC with POC will become a routine procedure. By contrast with an intact "clear" posterior capsule, there would be a reduction of straylight, there would no longer be any need for implants with square-edge optics creating dysphotopsia, and secondary cataract would be practically eliminated [13].

Oetting, Stegman, Jones, Snyder, Crandall, Arbisser and other authors selectively apply these techniques, and some consider primary PCCC with POC to represent another significant leap forward in routine modern cataract surgery [12,17]. A major contribution here was made by Dick, who pioneered the technique of posterior capsulectomy with femtosecond laser assistance [24]. In our country a cheap and quick routine procedure for the performance of PCCC has been developed by Studený [11].

The technique of posterior capsulorhexis requires a steep, brief learning curve, which merely supplements the essential skills of the cataract surgeon – the performance of anterior continuous curvilinear capsulorhexis. It does not require any further special equipment or technology. The ability to manipulate the thin and elastic posterior capsule should be part of the skill of anyone performing comprehensive anterior segment surgery, even though it is not generally emphasized in education programs for young junior surgeons. According to the literature, the learning curve is estimated at 150 operated cases, when the surgeon now feels fully self-assured in the performance of this technique [17].

## CONCLUSION

Posterior capsular opacification, which causes a deterioration of the patient's visual functions following cataract surgery, is the main long-term complication of modern phacoemulsification. The regular therapeutic procedure, the creation of Nd:YAG laser capsulotomy, practically always breaches the AHM. The preservation of an intact AHM has countless proven and potential advantages. PCCC techniques sparing the anterior hyaloid membrane reduce the possibility of pathological consequences on the retina and trabeculum. Cataract surgeons have traditionally been trained to avoid breaching the posterior capsule at all costs, even though in fact both segments of the eye are divided by the anterior hyaloid membrane. This is clear from embryology, anatomy and from an extensive body of peer-reviewed studies. The success of all current and in all probability future PCCC techniques will depend on the preservation of this structure. Our current standard of cataract surgery involving the implantation of an artificial IOL into the sac with an intact posterior capsule should not remain the definitive approach to cataract surgery.

## REFERENCES

- McDonnell PJ, Zarbin MA, Green WR. Posterior capsule opacification in pseudophakic eyes. *Ophthalmology*. 1983;1983:901548-901553.
- Kappelhof JP, Vrensen GFJM. The pathology of after cataract; a minireview. *Acta Ophthalmol Suppl*. 1992;1992:20513-20524.
- Sundelin K, Almarzouki N, Soltanpour Y, et al. Five-year incidence of Nd: YAG laser capsulotomy and association with in vitro proliferation of lens epithelial cells from individual specimens: a case control study. *BMC Ophthalmol*. 2014;14:116.
- Ursell PG, Dhariwal M, O'Boyle D, et al. 5-year incidence of YAG capsulotomy and PCO after cataract surgery with single-piece monofocal intraocular lenses: a real-world evidence study of 20,763 eyes. *Eye*. 2020;34:960-968.
- Maloof A, Neilson G, Milverton EJ, Pandey SK. Selective and specific targeting of lens epithelial cells during cataract surgery using sealed-capsule irrigation. *J Cataract Refract Surg*. 2003;29:1566-1568.
- Menapace R. Routine posterior optic buttonholing for eradication of posterior capsule opacification in adults: report of 500 consecutive cases. *J Cataract Refract Surg*. 2006;32:929-943.
- Menapace R, Schriefl S, Lwowski C, Leydolt C. Impact of primary posterior capsulorhexis on regenerative after-cataract and YAG laser rates with an acrylic micro-incision intraocular lens with plate haptics: 1-year and 3-year results. *Acta Ophthalmol*. 2019;97:1130-1135.
- Castaneda VE, Legler UF, Tsai JC, et al. Posterior continuous curvilinear capsulorhexis. An experimental study with clinical applications. *Ophthalmology*. 1992;99:45-50.
- Galand A, Cauwenberge F, Moosavi J. Posterior capsulorhexis in adult eyes with intact clear capsules. *J Cataract Refract Surg*. 1996;1996:22458-22461.
- Van Cauwenberge F, Rakic JM, Galand A. Complicated posterior capsulorhexis: aetiology, management, and outcome. *Br J Ophthalmol*. 1997;81:195-198.
- Studený P, Benda T. Primary Posterior Continuous Circular Capsulorhexis without the Use of Ophthalmic Viscosurgical Device. *Clin Ophthalmol*. 2023;17:441-444.
- Arbissier LB. Review of primary posterior capsulorhexis in cataract surgery. *Saudi J Ophthalmol*. 2022;36:149-156.
- Menapace R. After-cataract; final eradication in sight? *Clin Exp Ophthalmol*. 2008;36:810-811.
- Devranoglu K, Kılıç A, Özdamar A, et al. Intraocular lens optic capture in eyes with zonular weakness in cataract patients. *J Cataract Refract Surg*. 2013;39:669-672.
- Tassignon MJ, De Groot V, Verweken F, et al. Secondary closure of posterior continuous curvilinear capsulorhexis in normal eyes and eyes at risk for postoperative inflammation. *J Cataract Refract Surg*. 1998;24:1333-1338.
- De Groot V, Vrensen GF, Willekens B et al. In vitro study on the closure of posterior capsulorhexis in the human eye. *Invest Ophthalmol Vis Sci*. 2003;44:2076-2083.
- Menapace R. Posterior capsulorhexis combined with optic buttonholing: An alternative to standard in-the-bag implantation of sharp-edged intraocular lenses? A critical analysis of 1000 consecutive cases. *Graefes Arch Clin Exp Ophthalmol*. 2008;246:787-801.
- Saika S, Werner L, Lovicu FJ, et al. Lens Epithelium and Posterior Capsular Opacification. Springer; 2014. doi: 10.1007/978-4-431-54300-8
- Stifter E, Luksch A, Menapace R. Postoperative course of intraocular pressure after cataract surgery with combined primary posterior capsulorhexis and posterior optic buttonholing. *J Cataract Refract Surg*. 2007;33:1585-1590.
- Tassignon MJ, Van den Heurck JJ, Boven KB, et al. Incidence of rhegmatogenous retinal detachment after bag-in-the-lens intraocular lens implantation. *J Cataract Refract Surg*. 2015;41:2430-2437.
- Stifter E, Menapace R, Neumayer T, et al. Macular morphology after cataract surgery with primary posterior capsulorhexis and posterior optic buttonholing. *Am J Ophthalmol*. 2008;146:15-22.
- Stifter E, Menapace R, Luksch A, et al. Objective assessment of intraocular flare after cataract surgery with combined primary posterior capsulorhexis and posterior optic buttonholing in adults. *Br J Ophthalmol*. 2007;91:1481-1484.
- Groot V, Hubert M, Van Best JA, et al. Lack of fluorophotometric evidence of aqueous-vitreous barrier disruption after posterior capsulorhexis. *J Cataract Refract Surg*. 2003;29:2330-2338.
- Dick HB, Schultz T. Primary posterior laser-assisted capsulotomy. *J Refract Surg*. 2014;30:128-133.